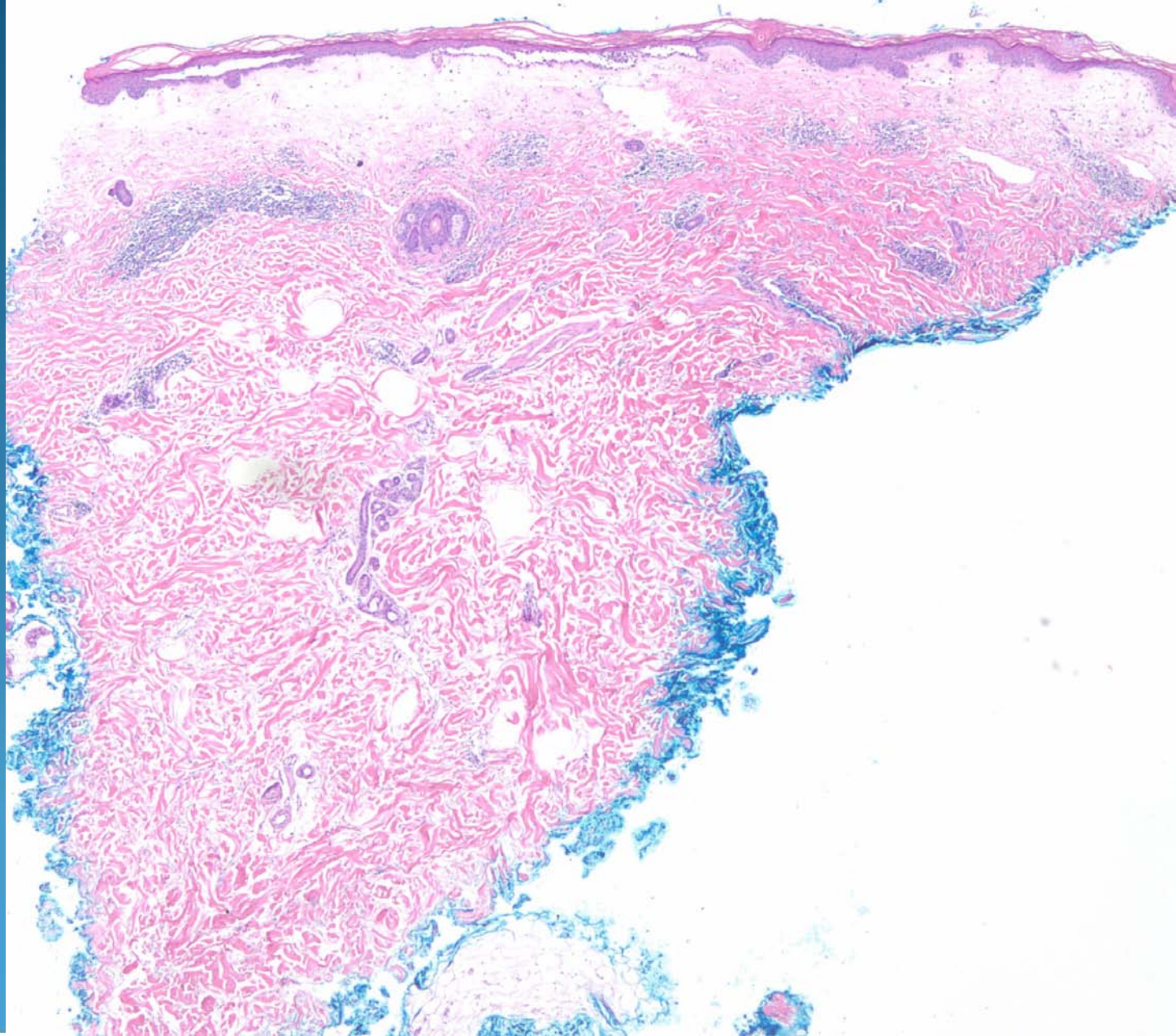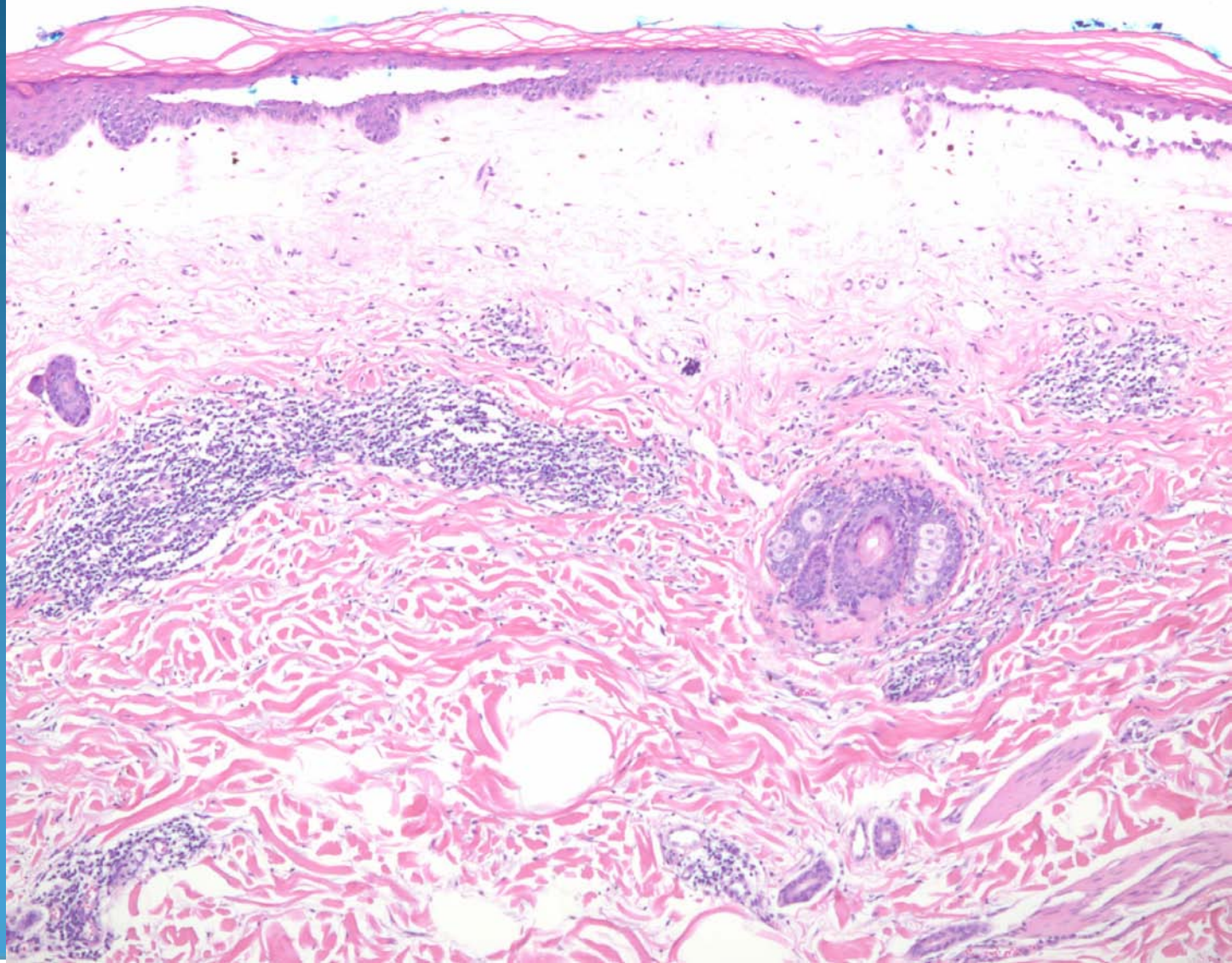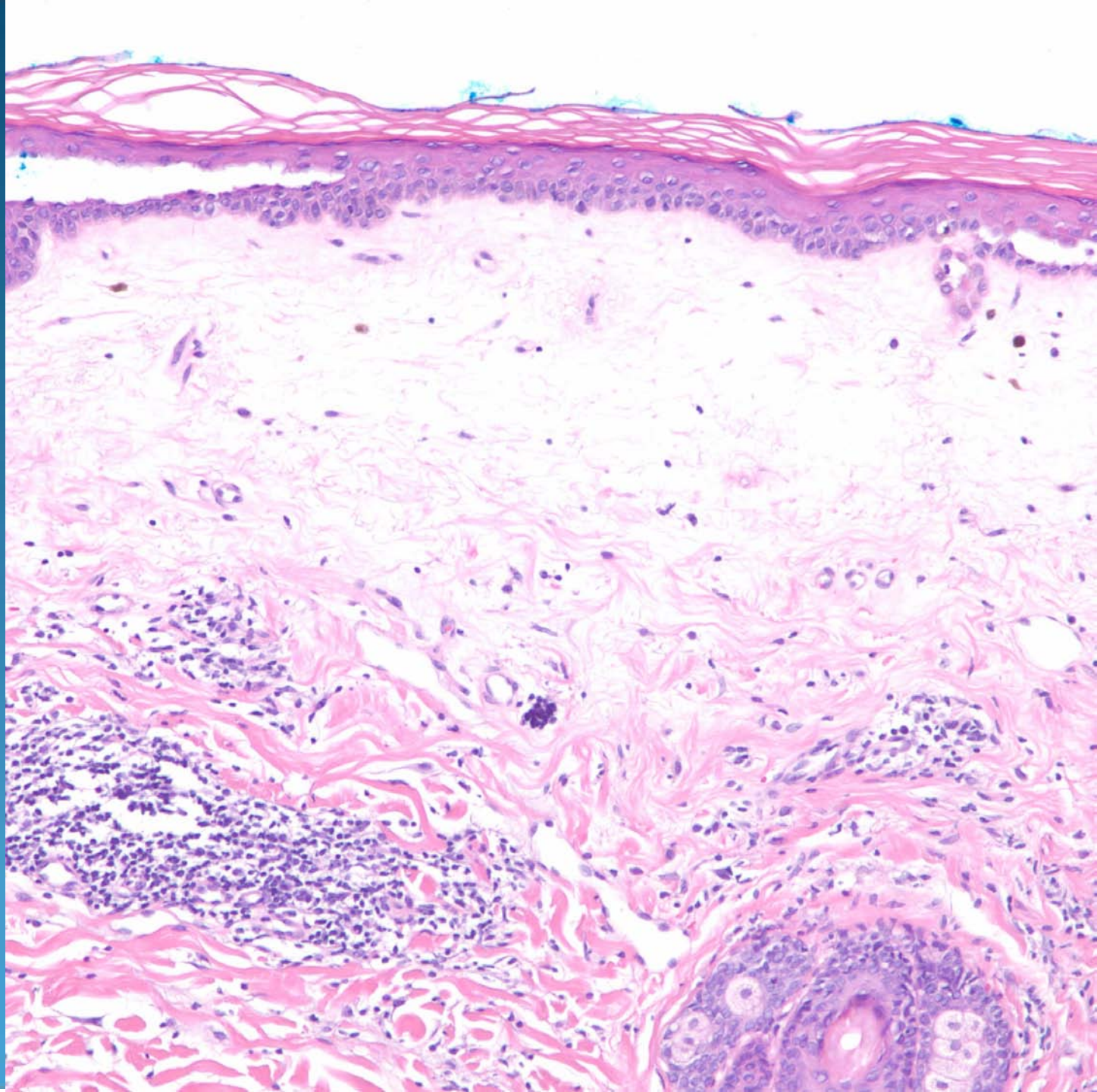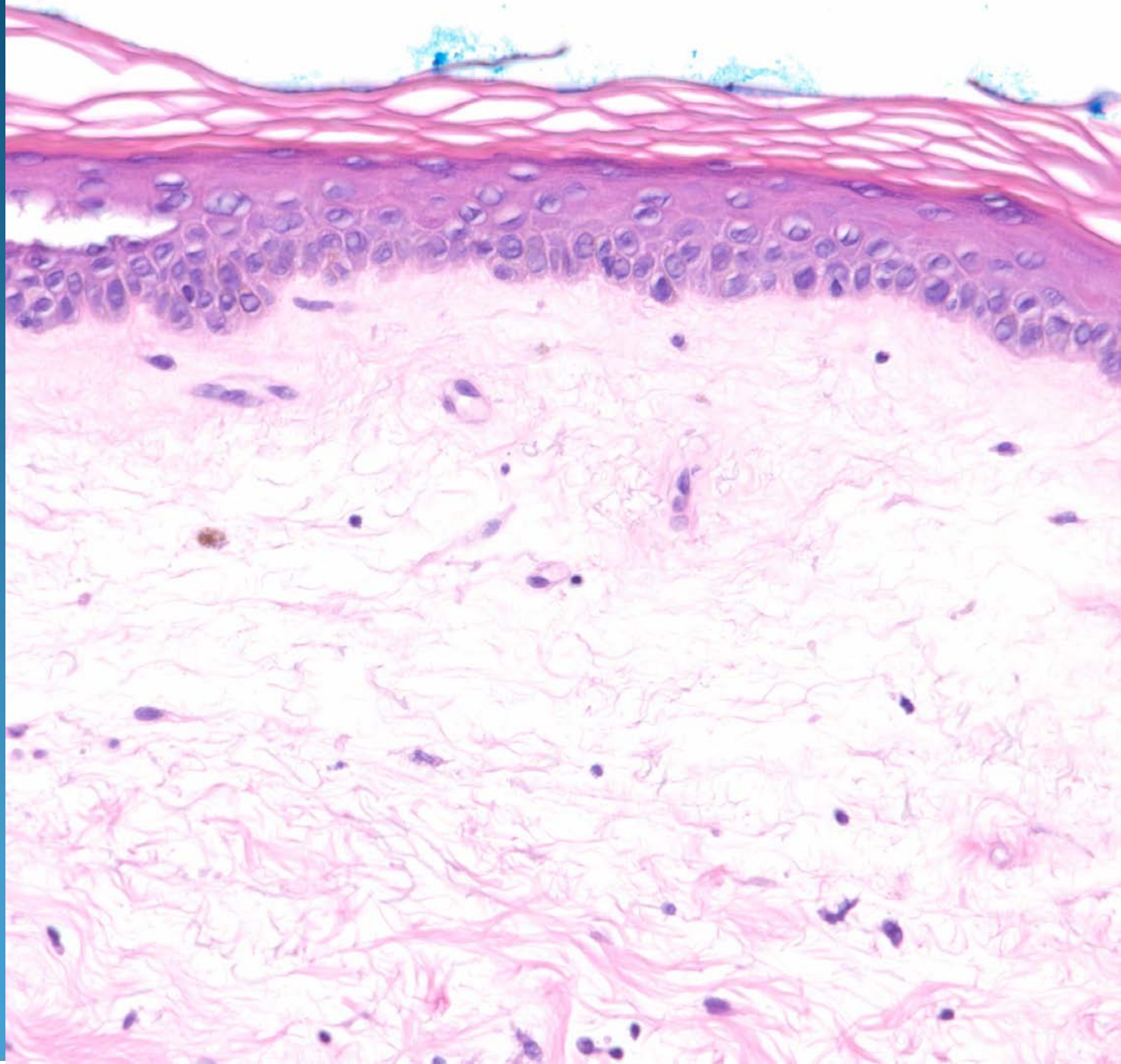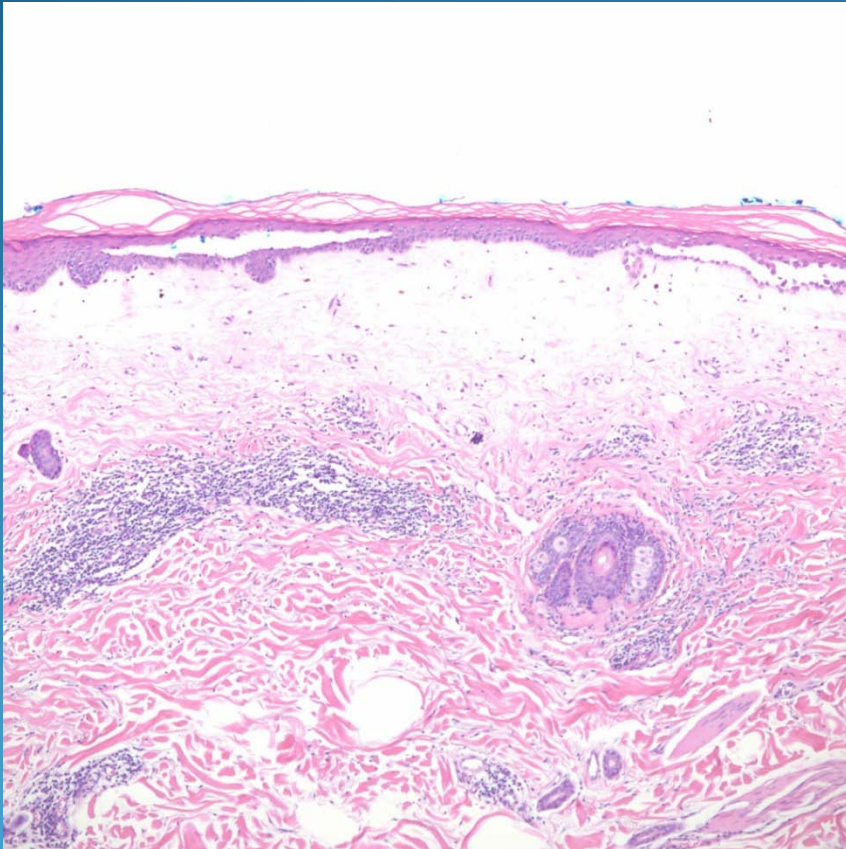


# Lichen Sclerosus et Atrophicus

# Pearls



- Papillary dermal edema with underlying lichenoid inflammatory cell infiltrate
- May see hyalinization of basement membrane
- Follicular plugging