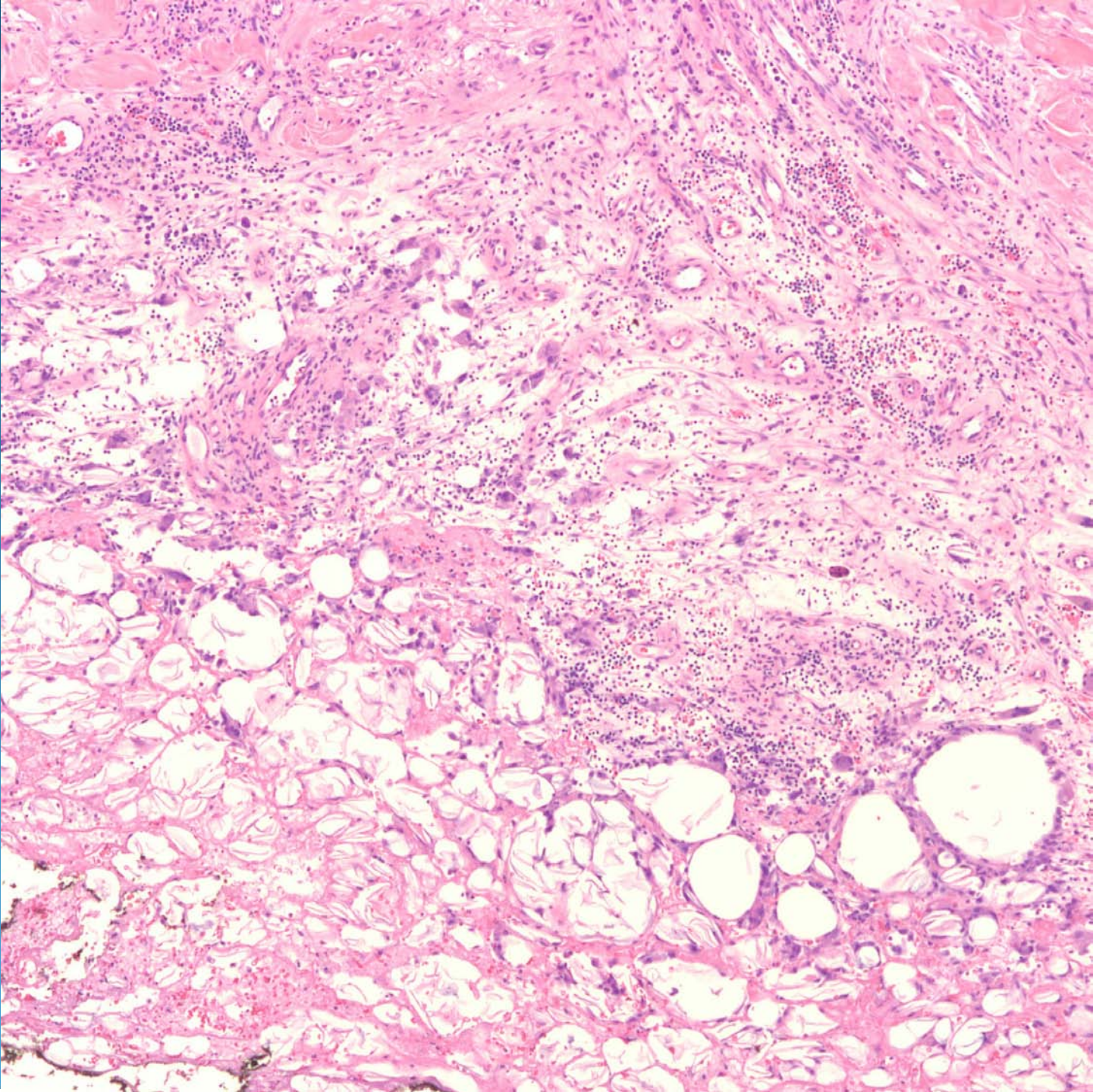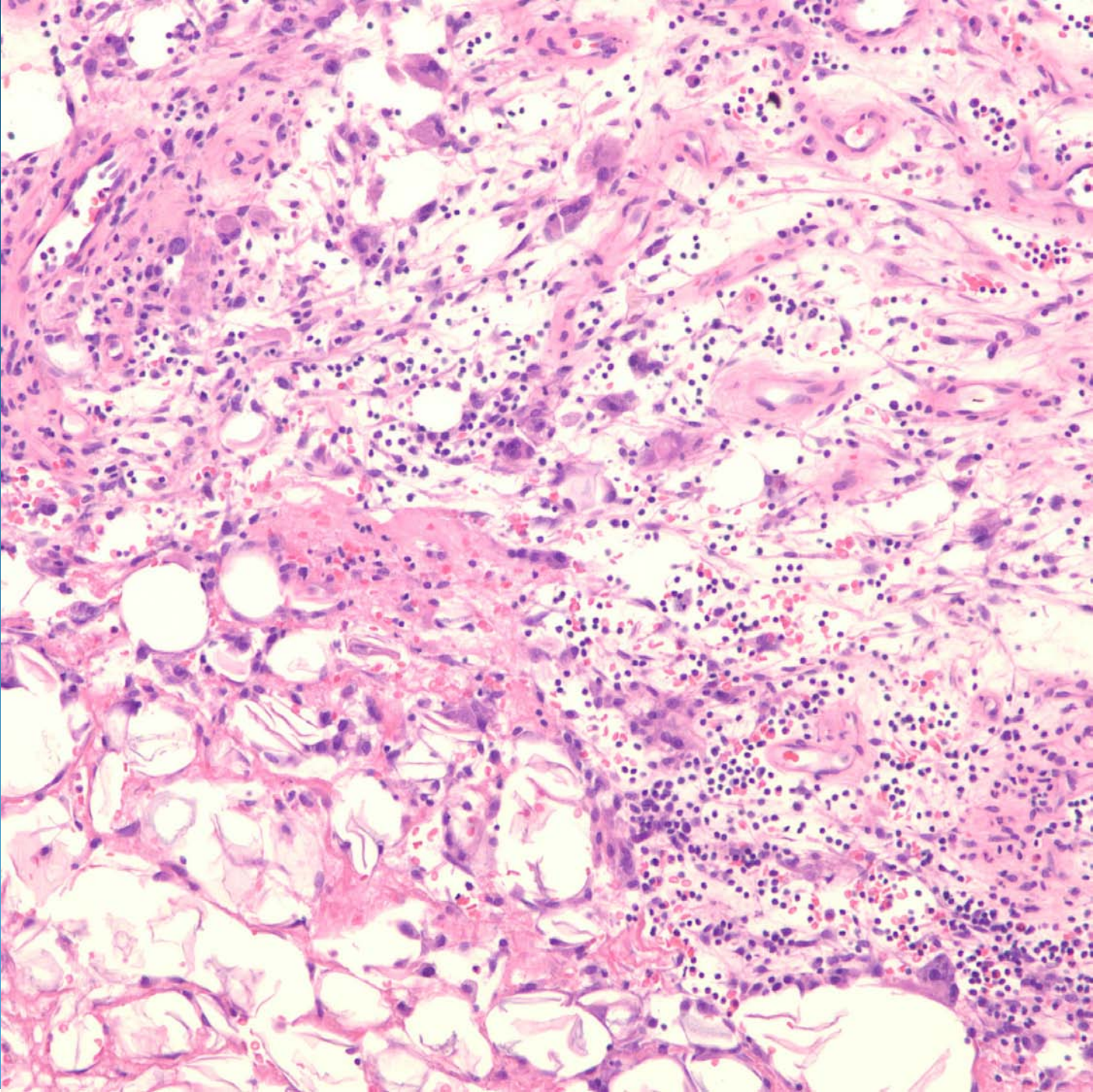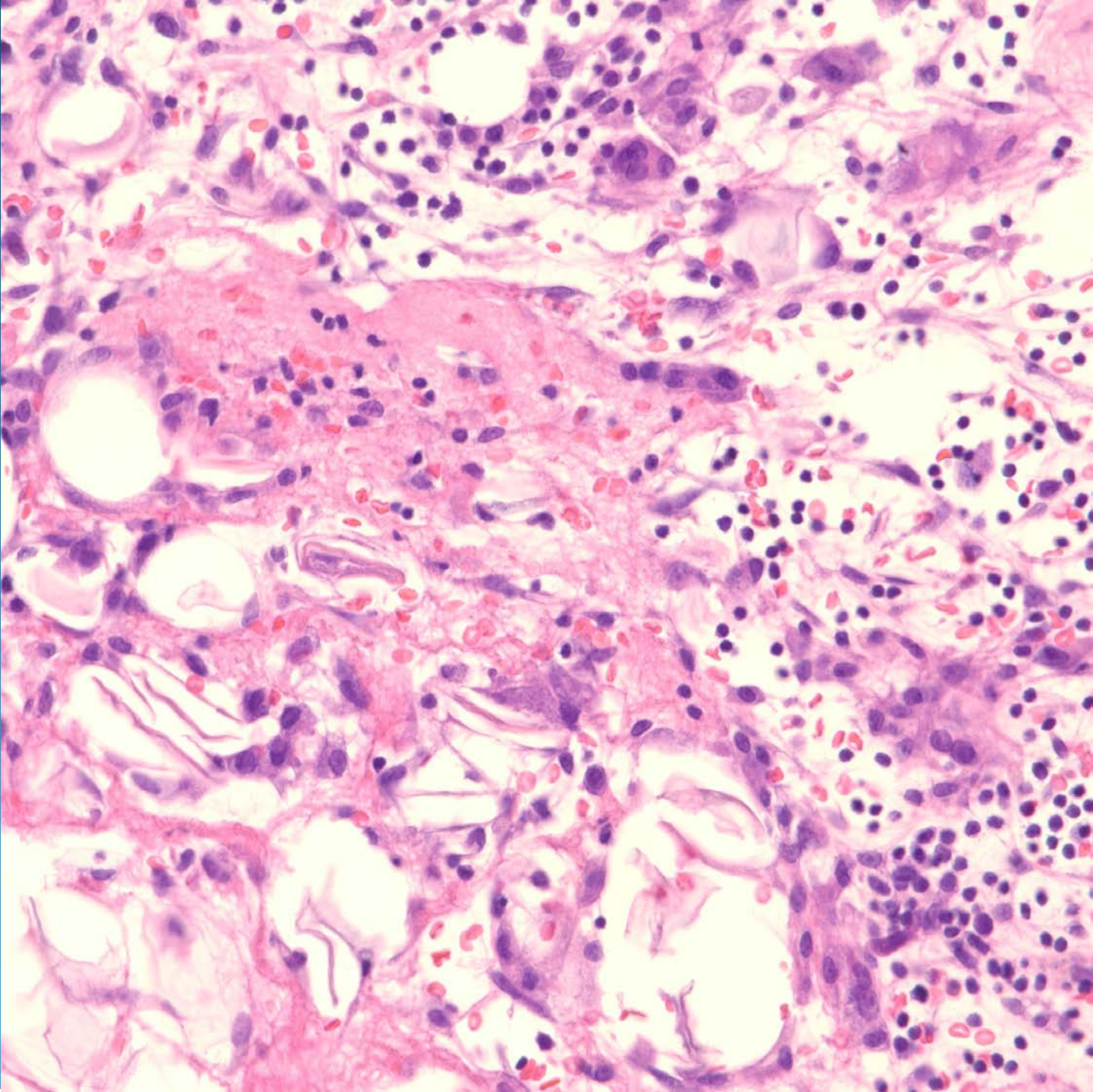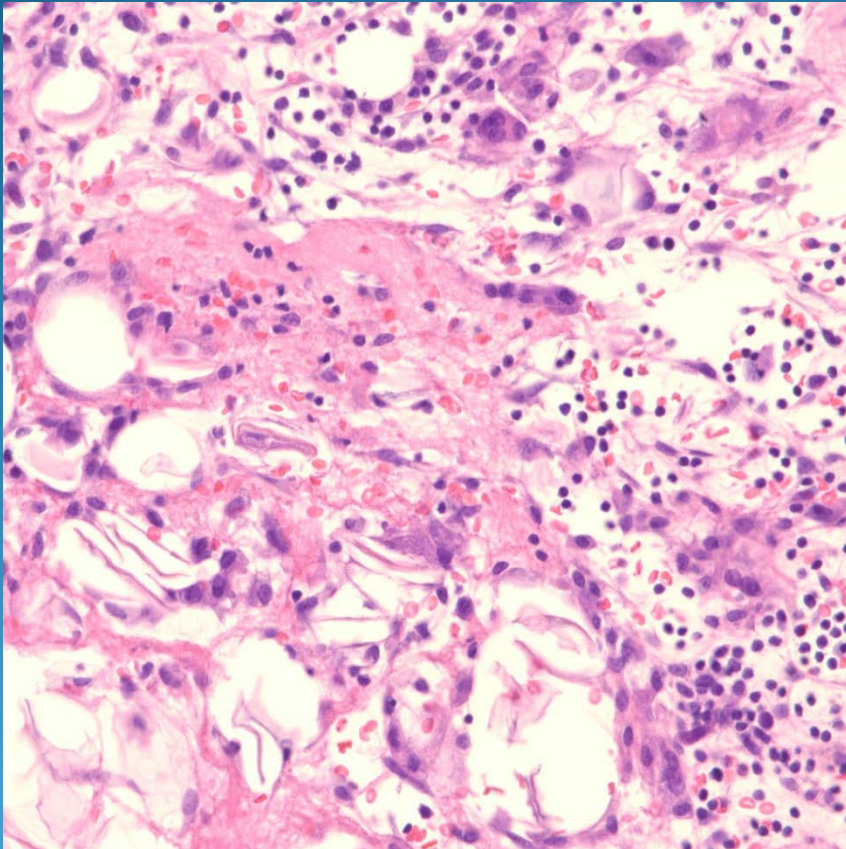


# Keratin Granuloma

# Pearls



- Nodule with clefts and flakes of keratin
- Foreign body giant cells with histiocytes