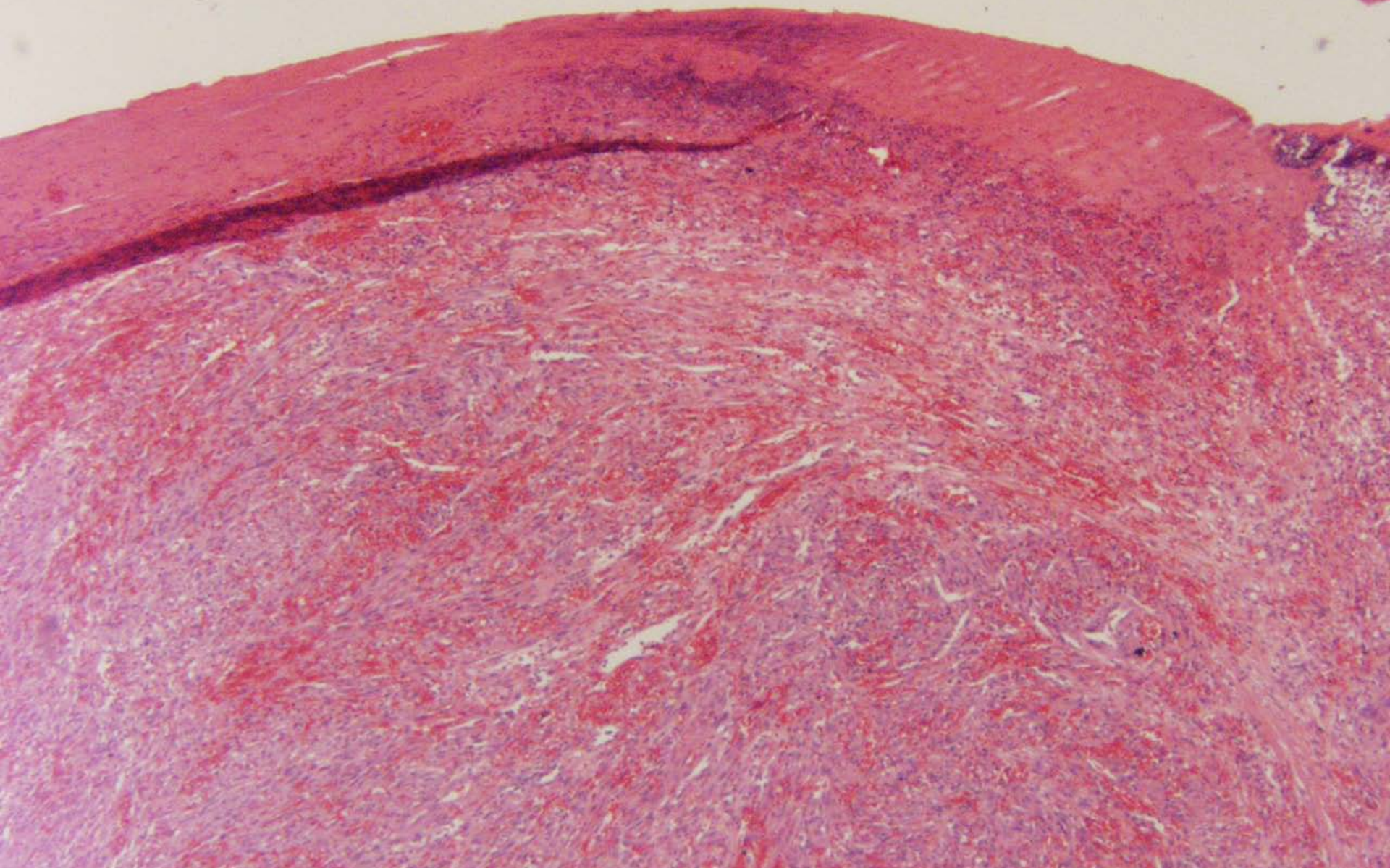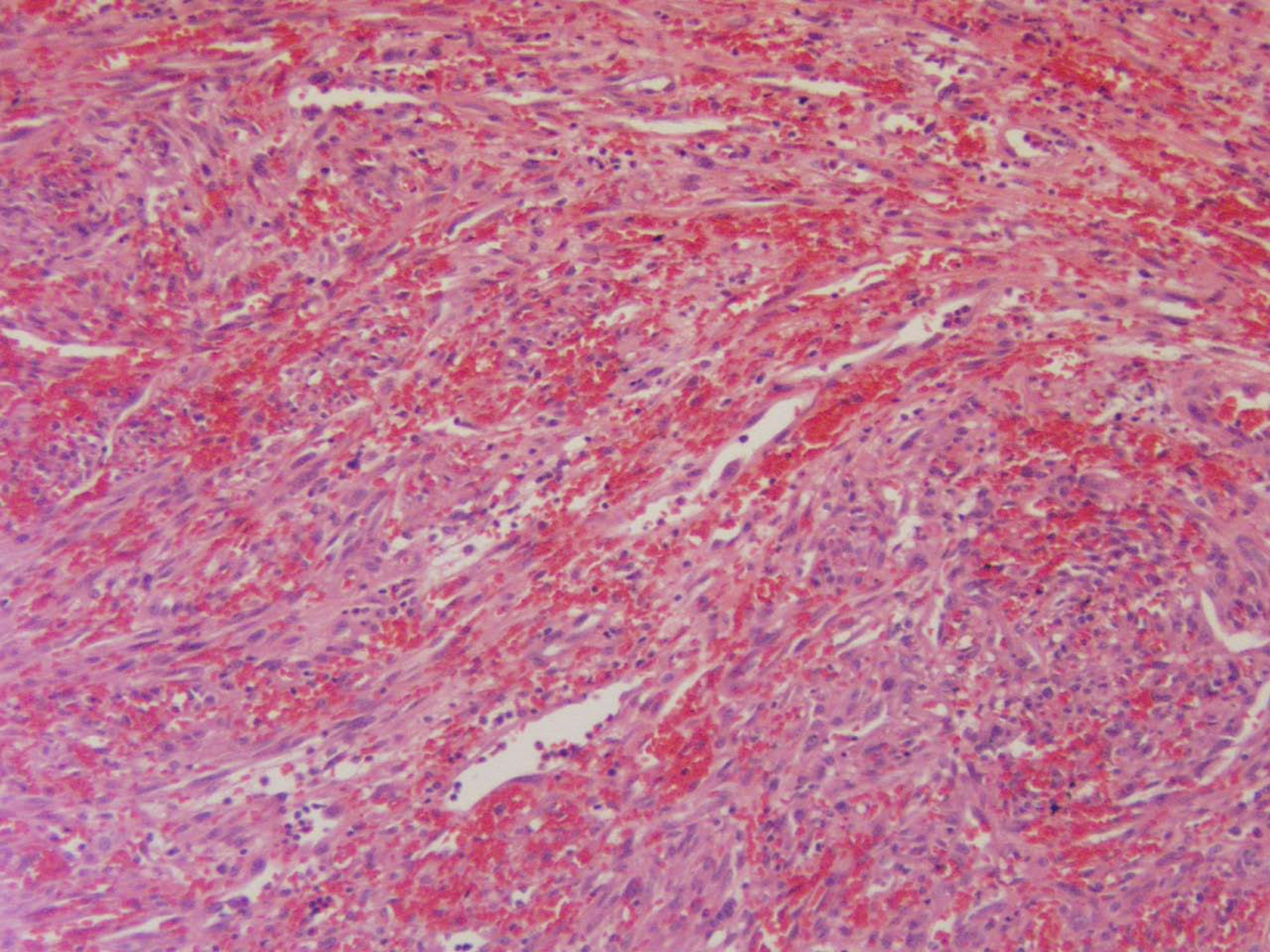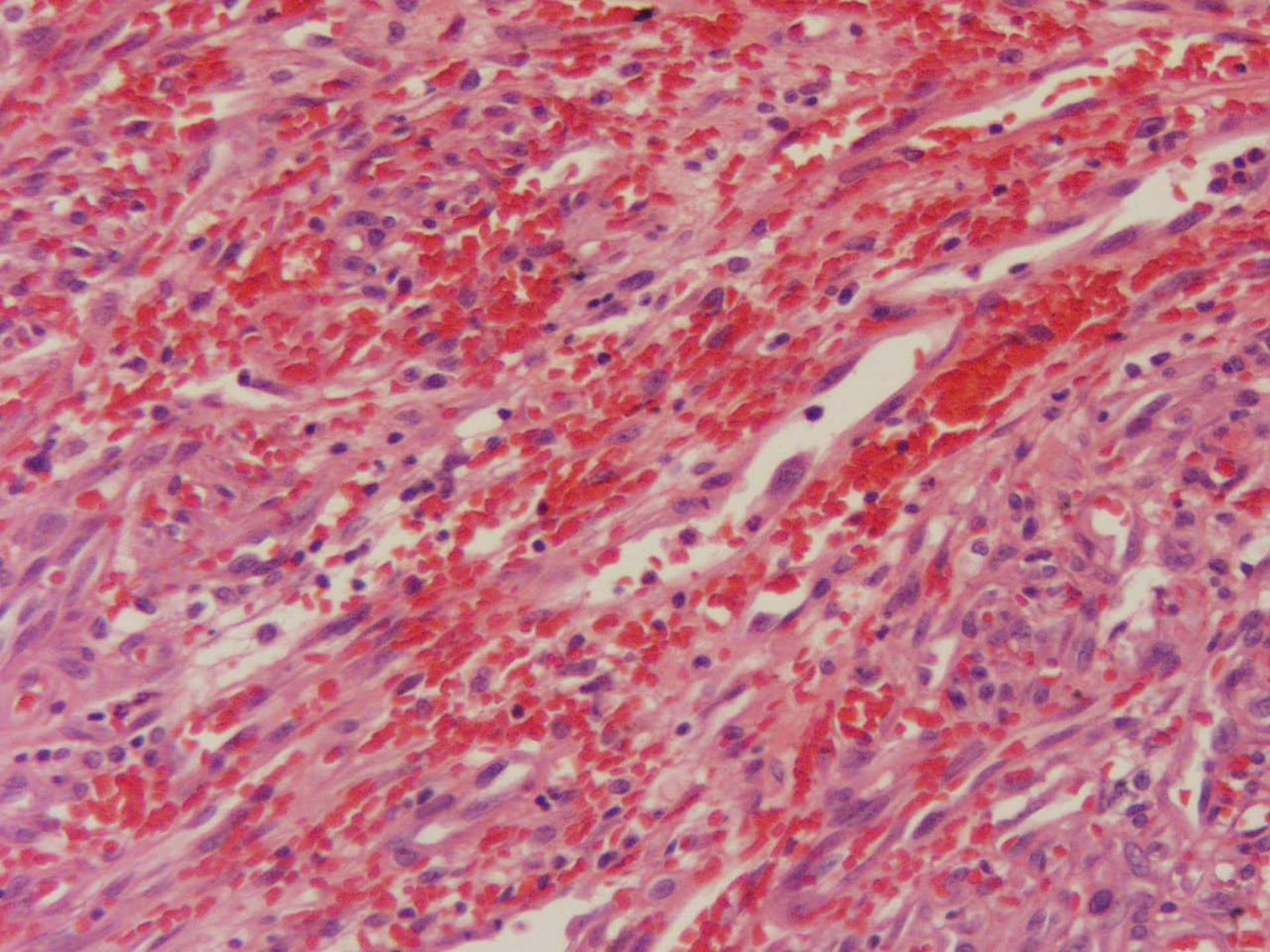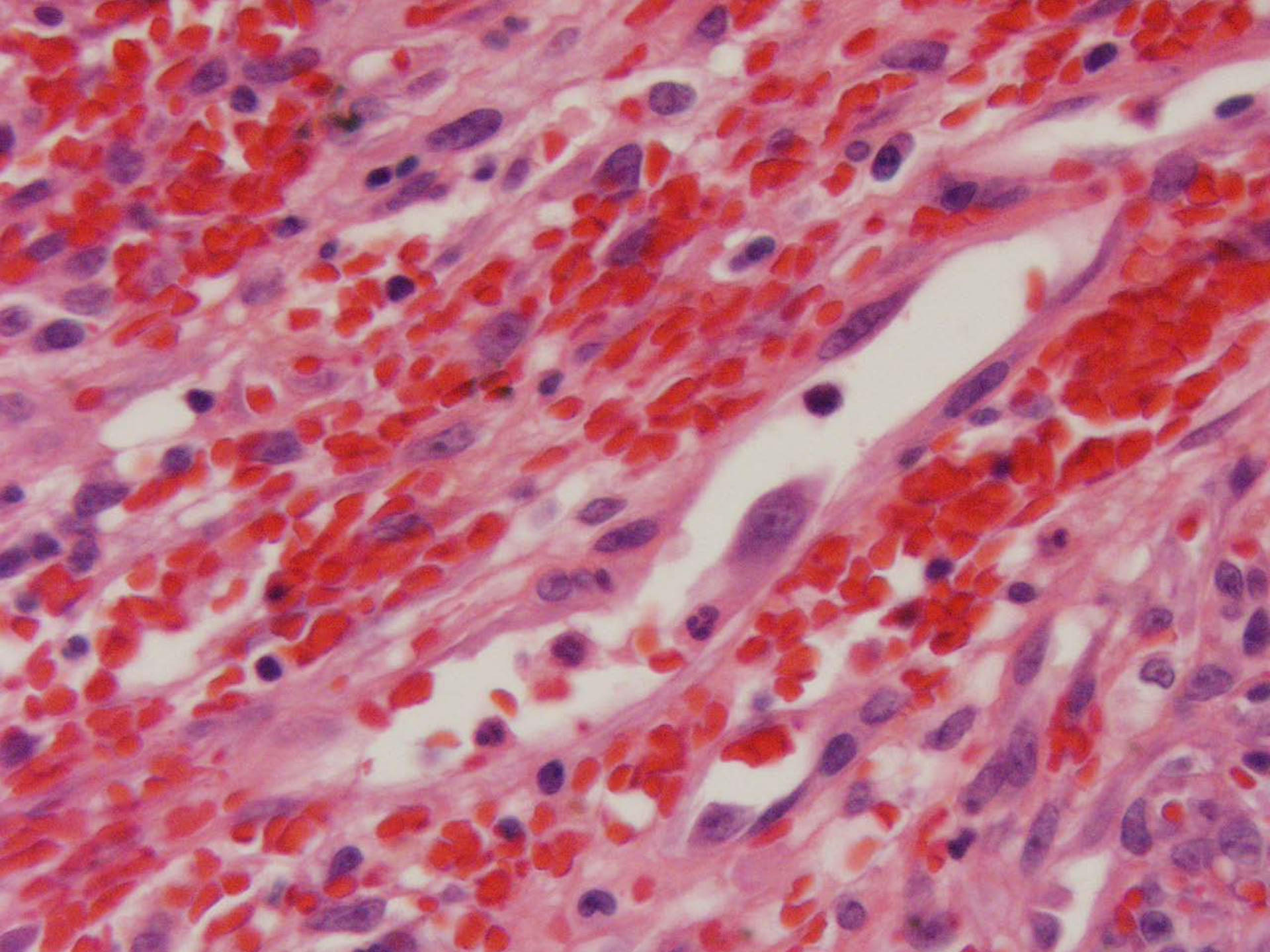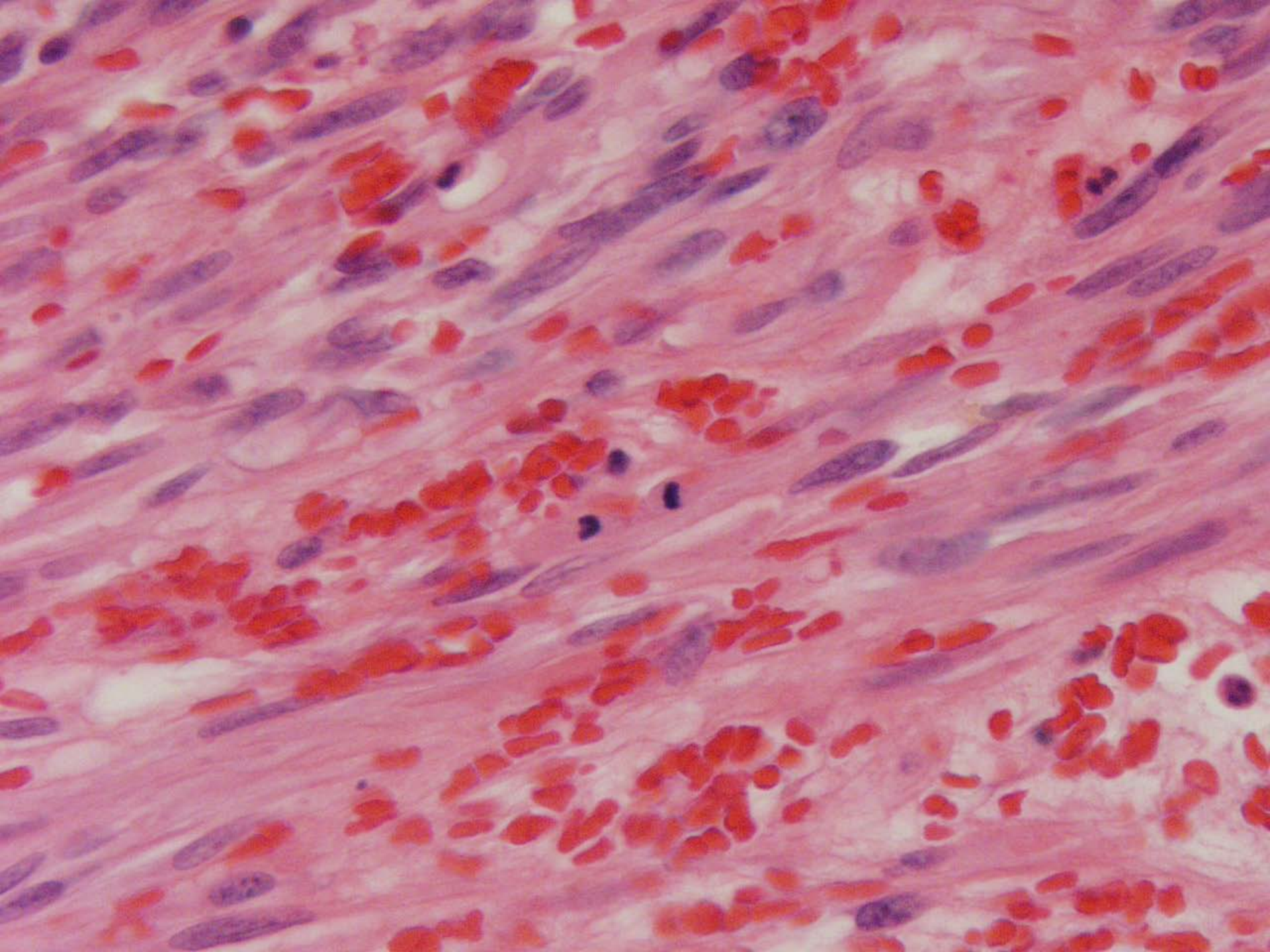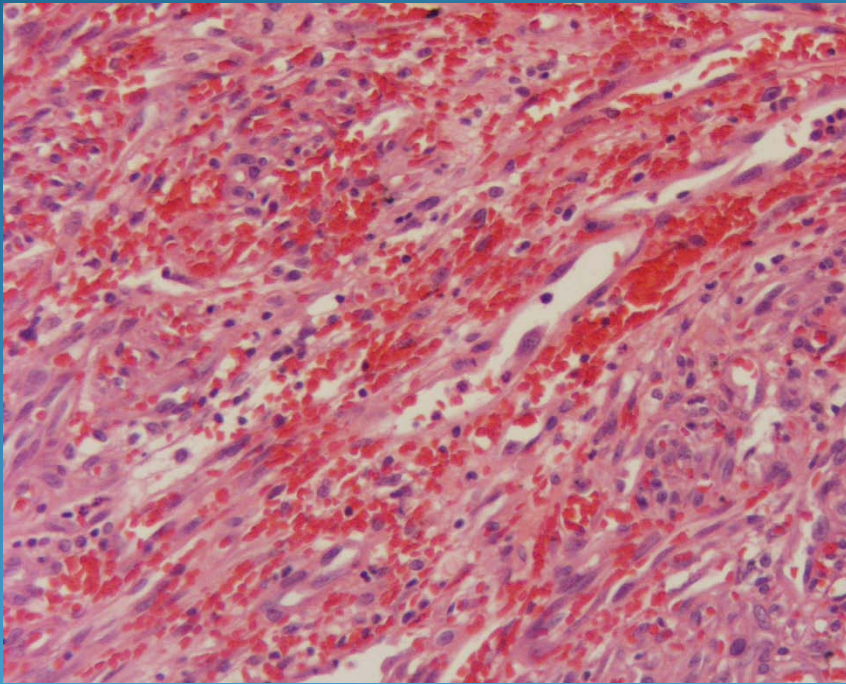


Kaposi's Sarcoma

Pearls



- Spindle cell tumor with vascular slit spaces with numerous red blood cells
- Occasional plasma cells
- Early lesions show promontory sign