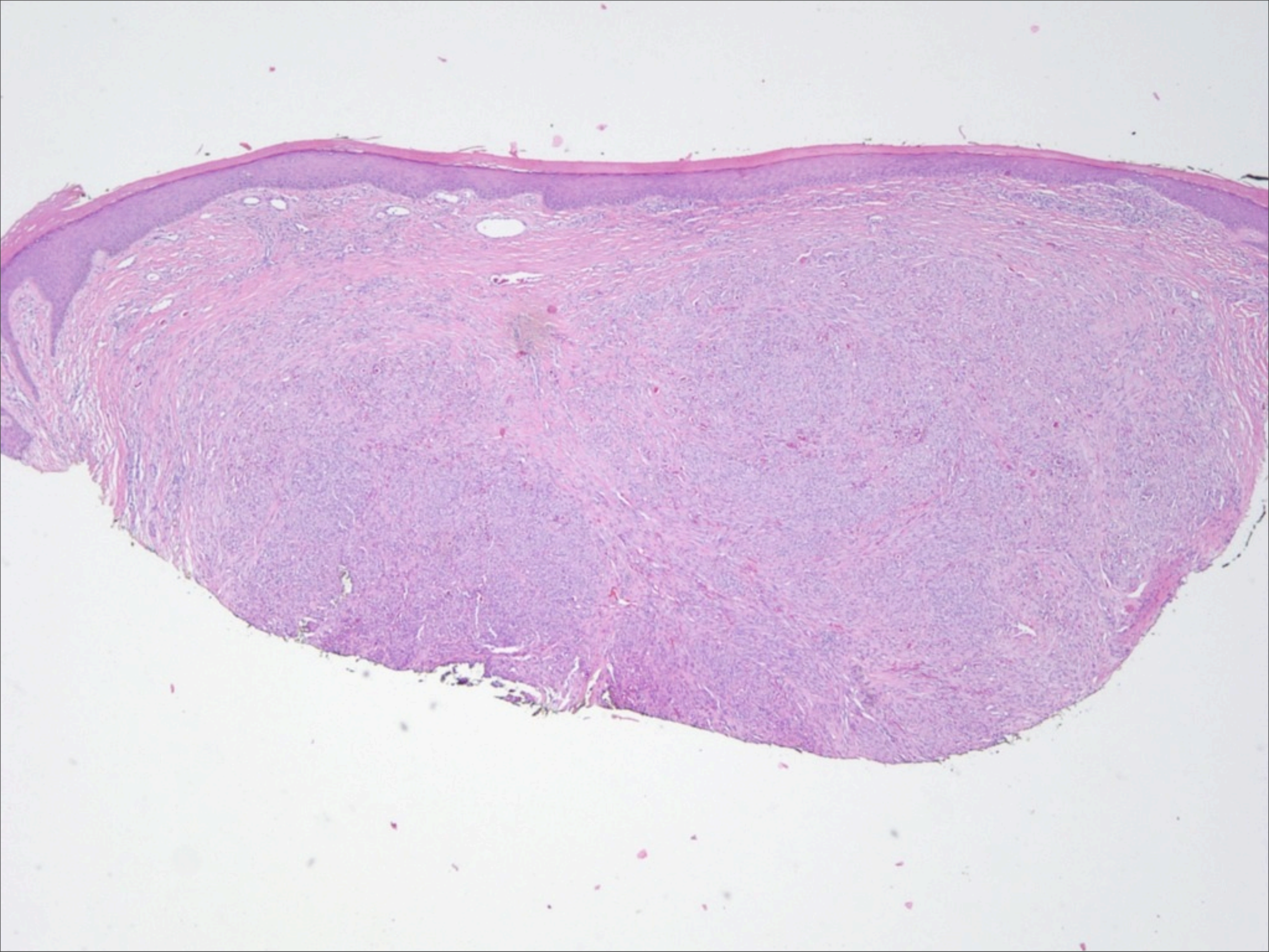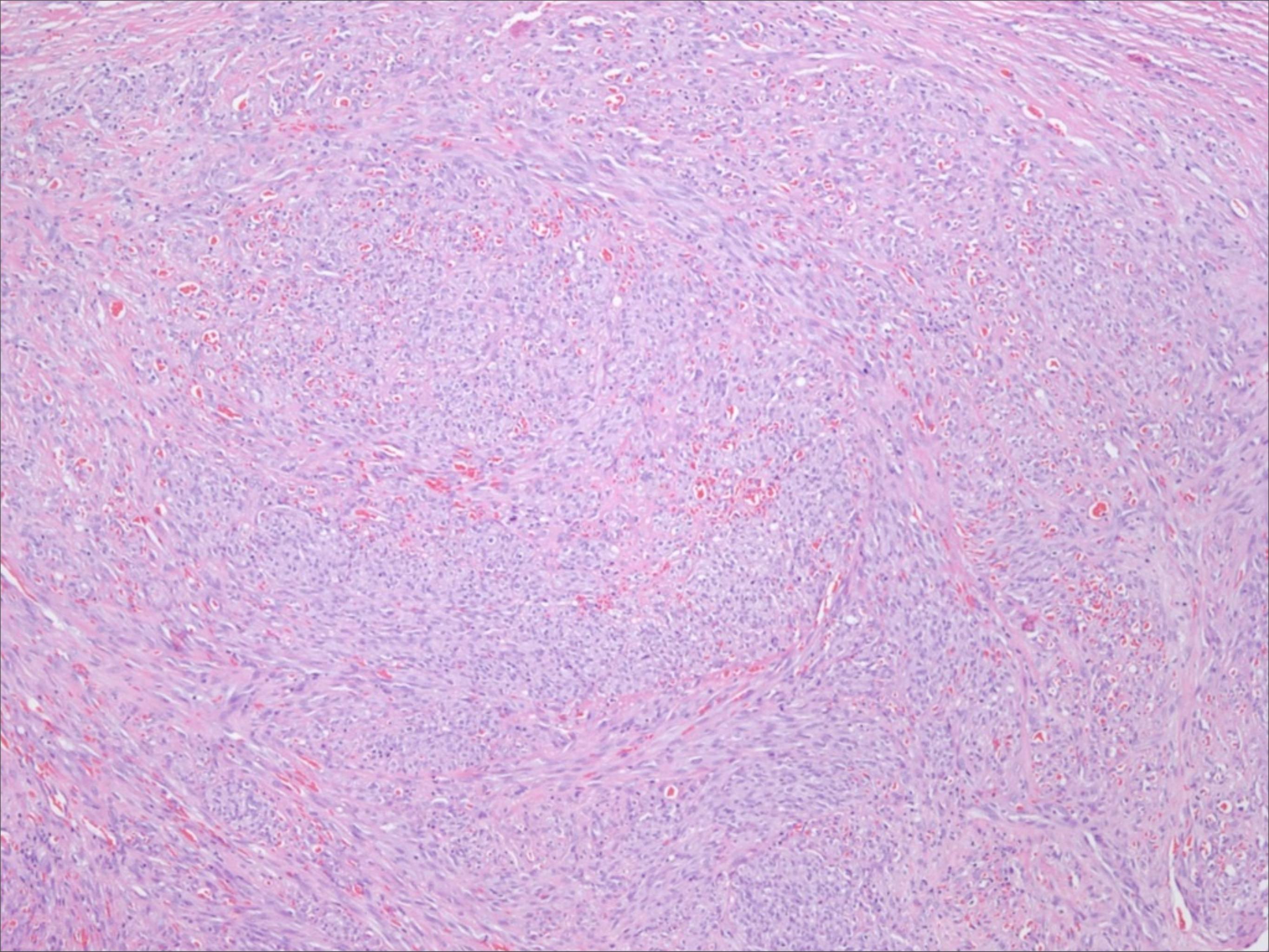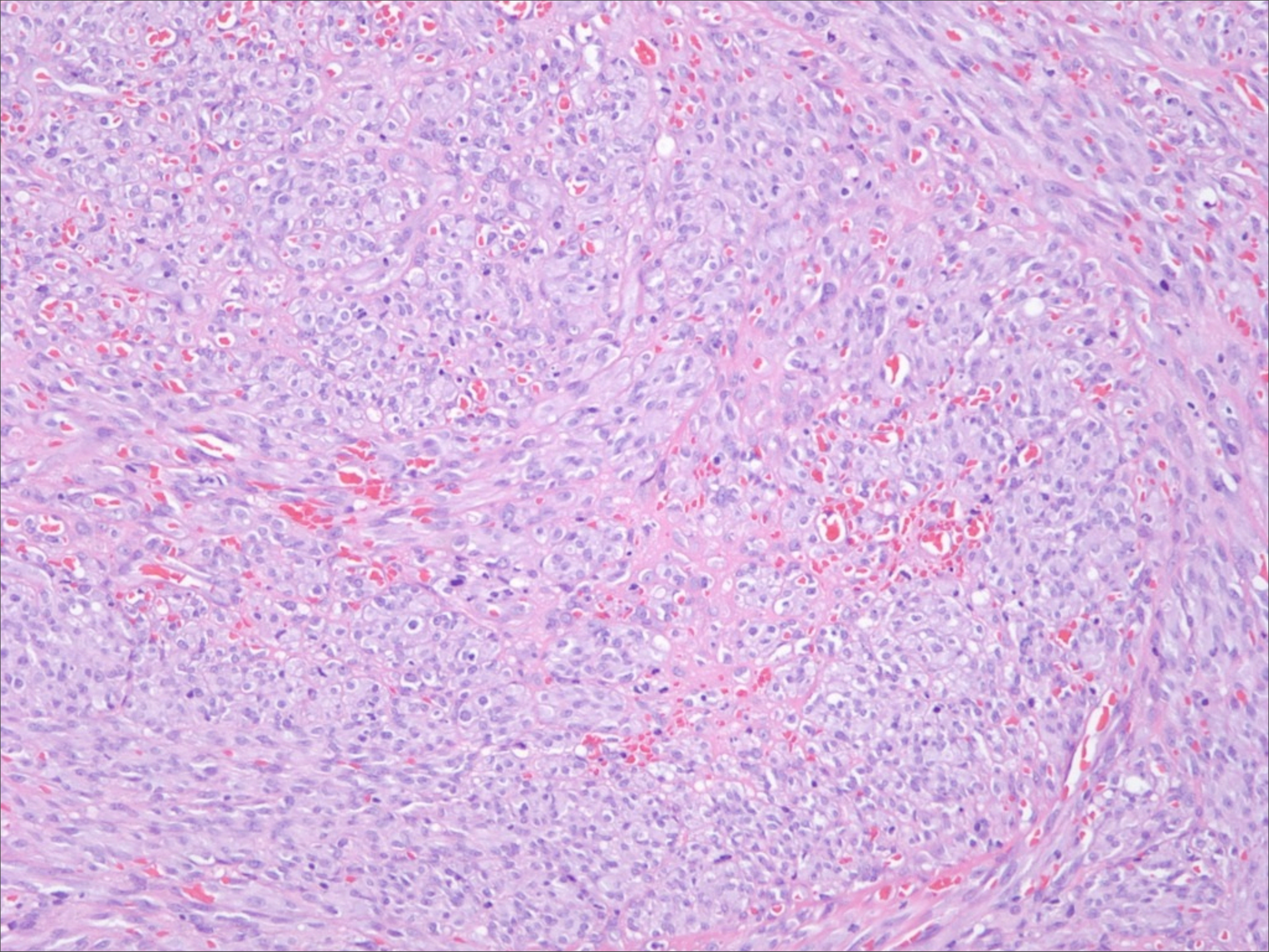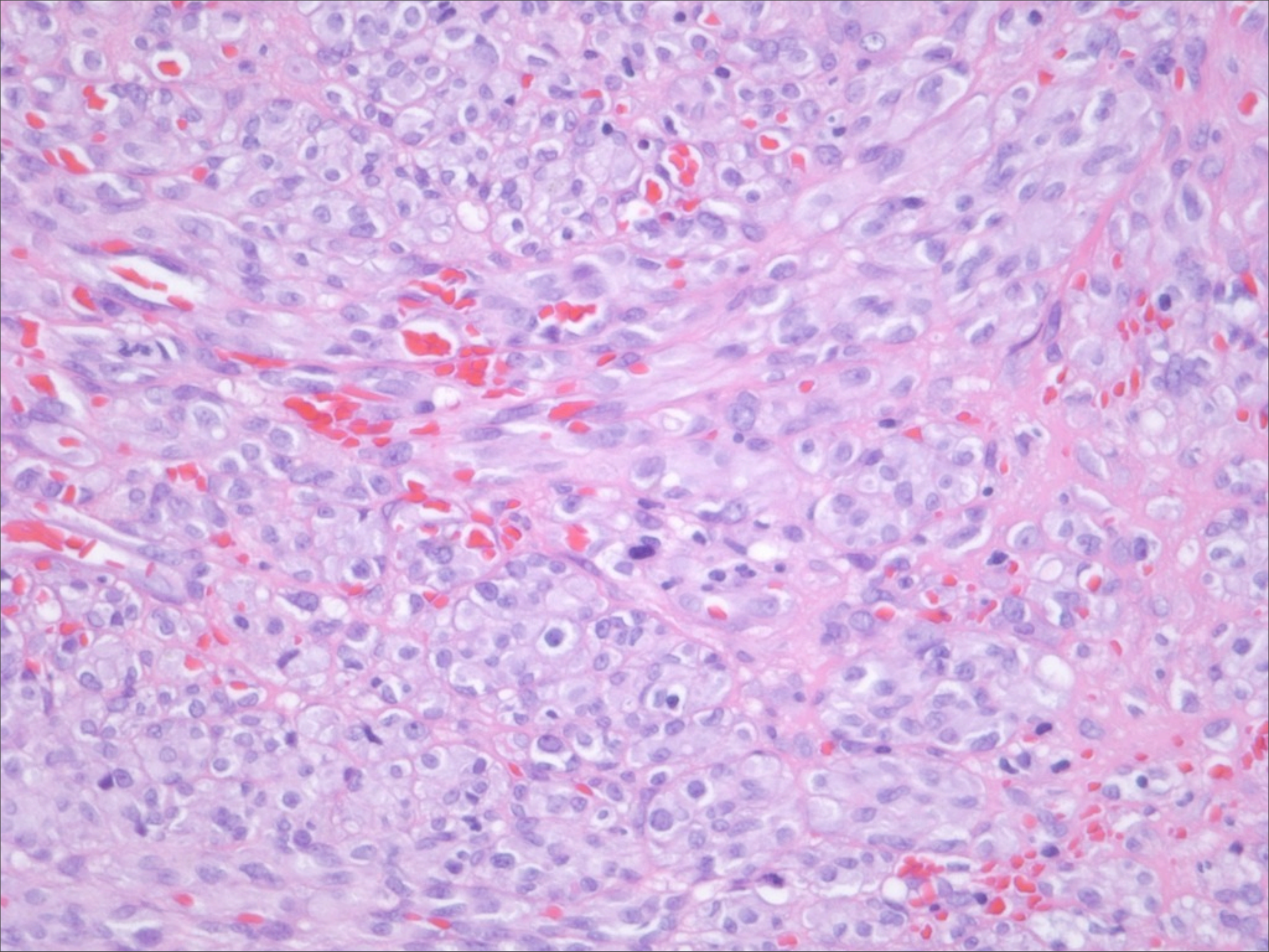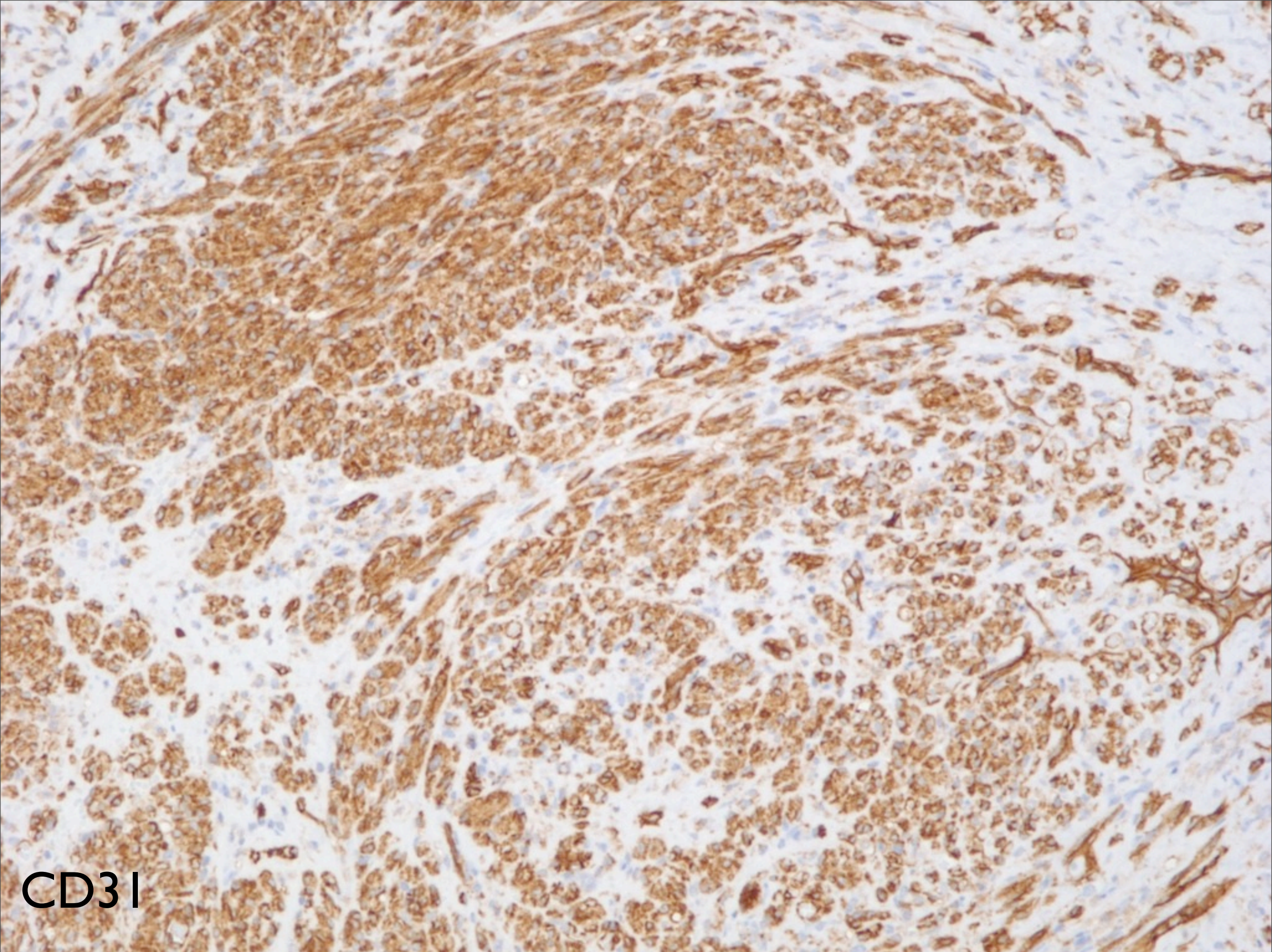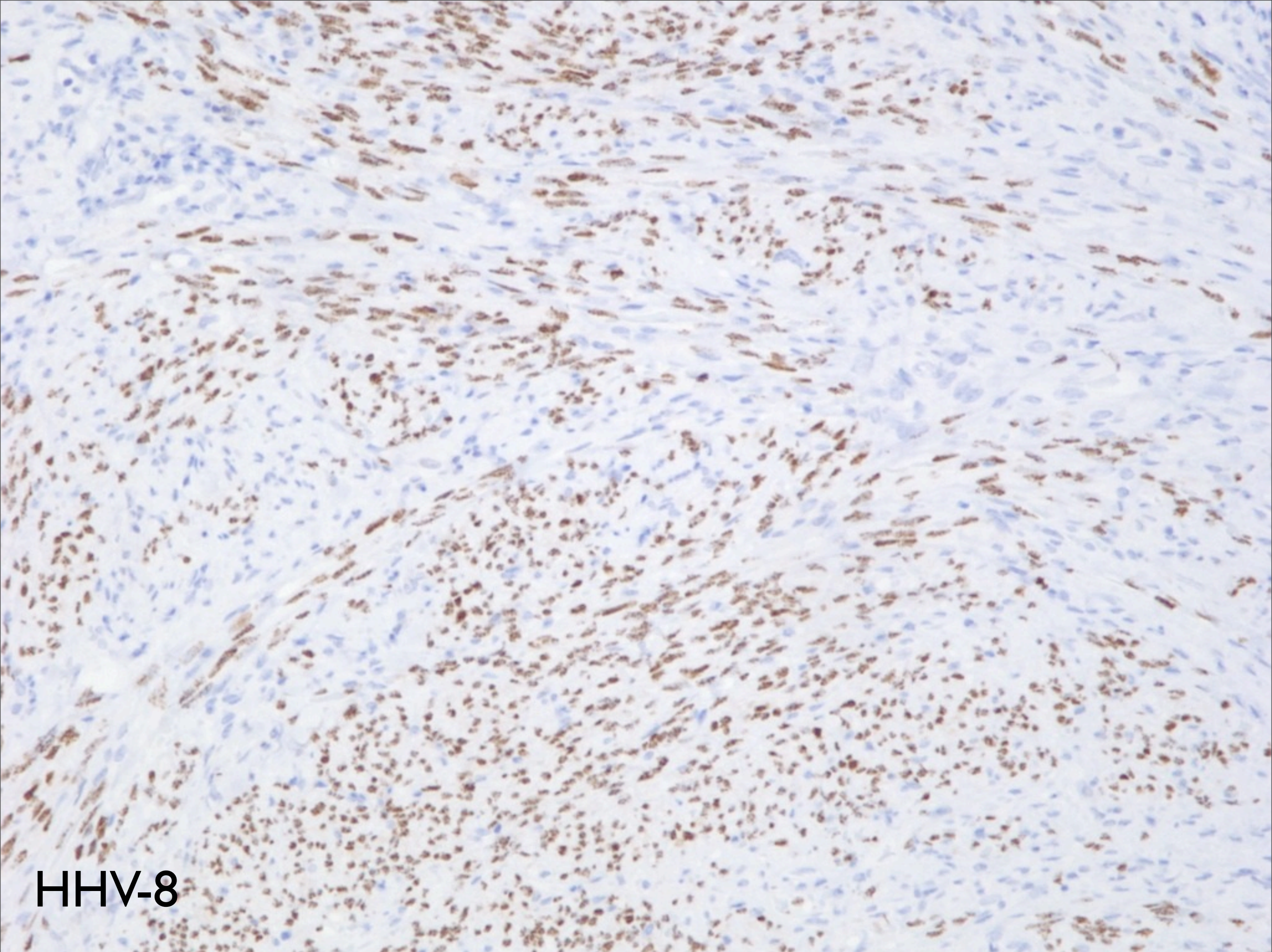


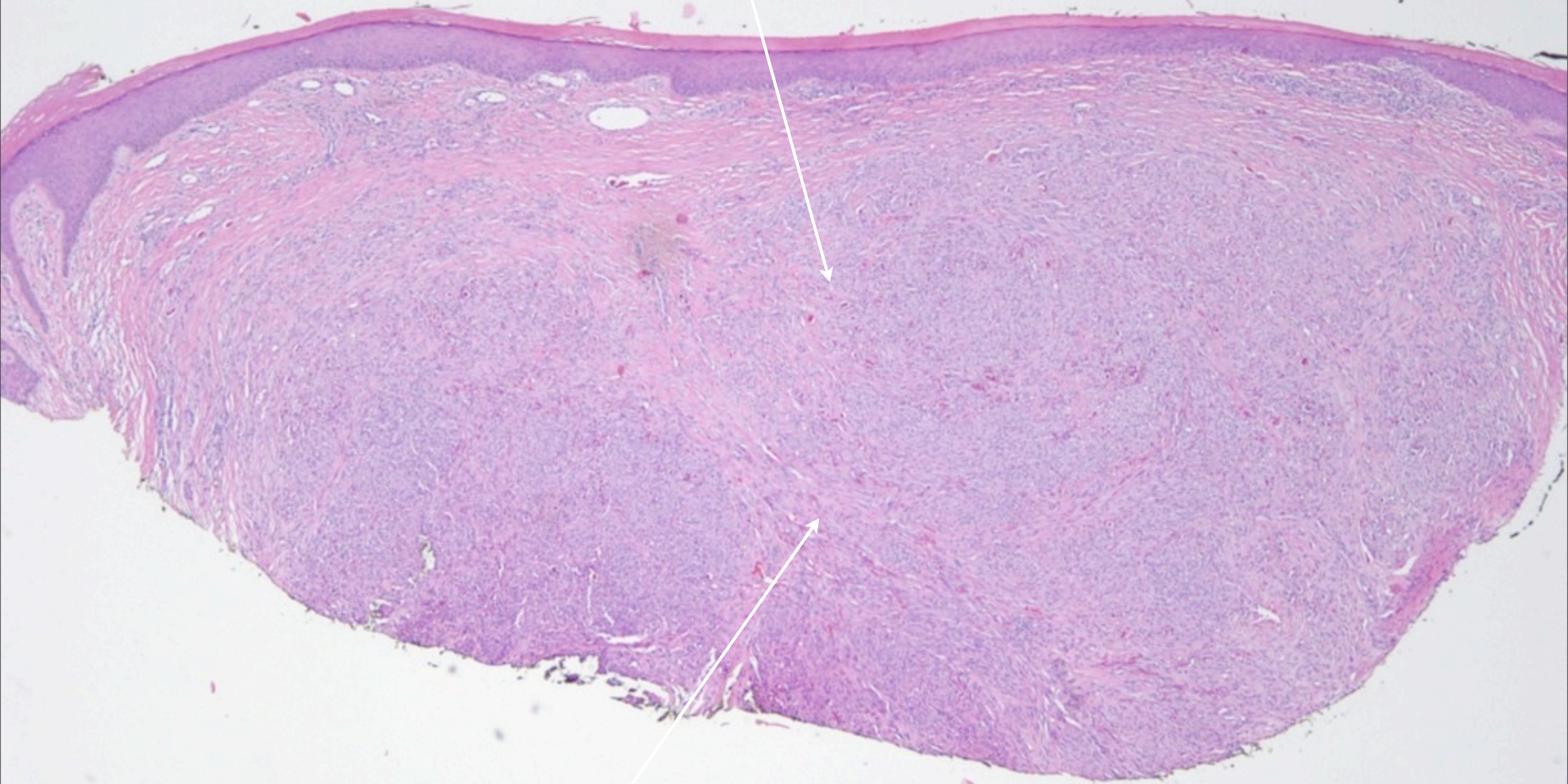
CD31



HHV-8

Kaposi's Sarcoma Tumor Stage

Diffuse proliferation of cytologically atypical spindle cells



Vascular slits with extravasted rbcs