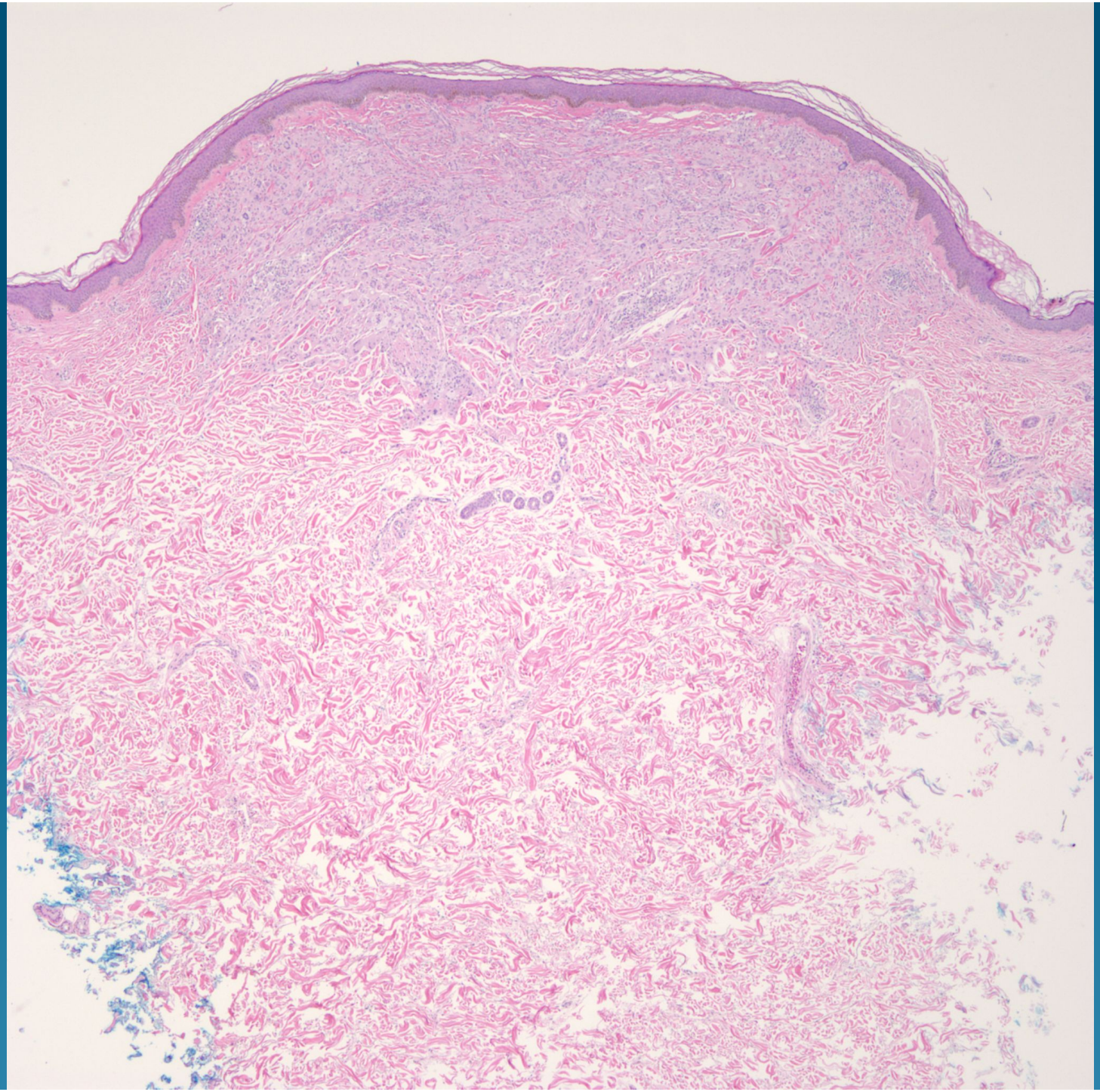

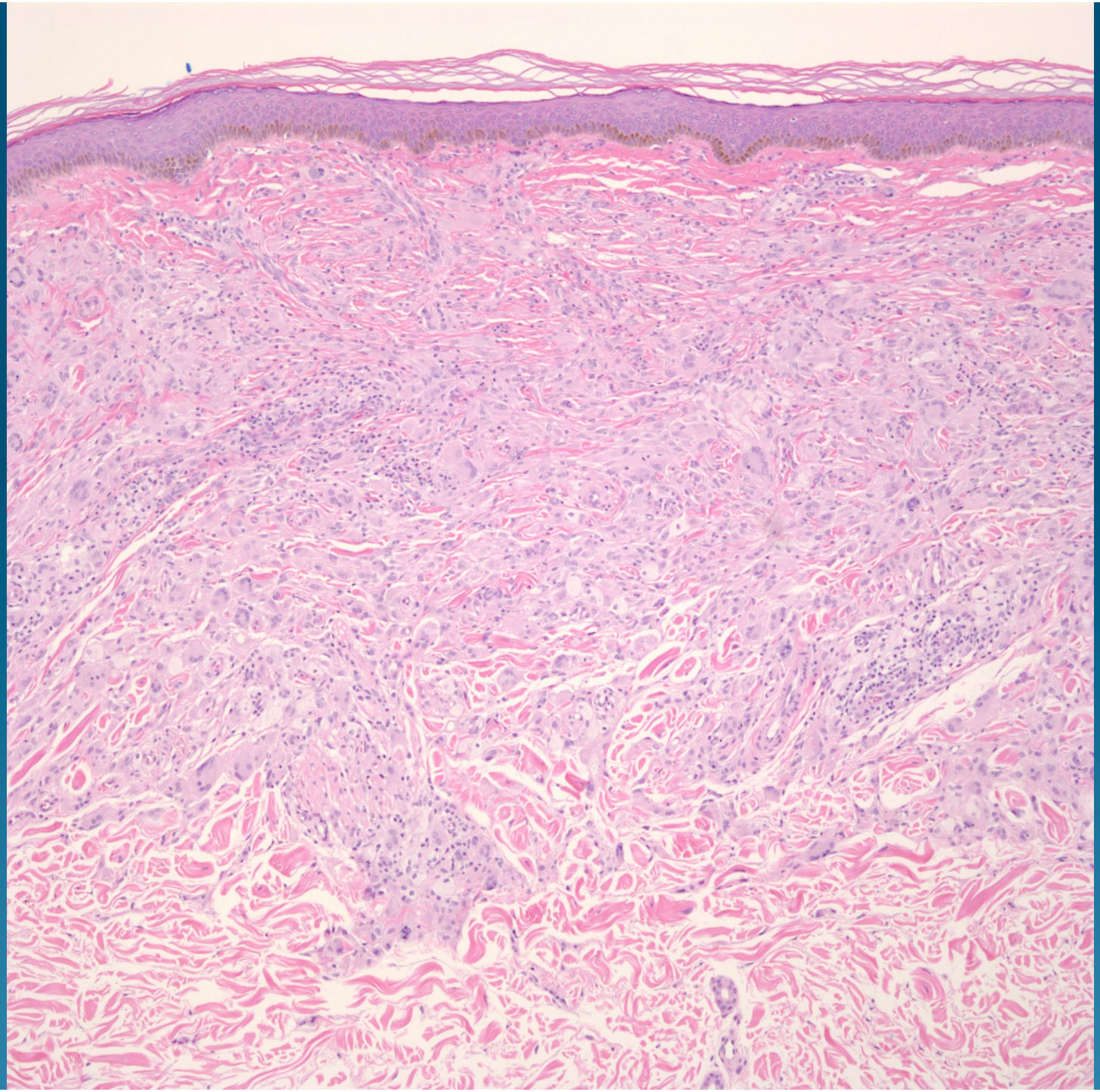

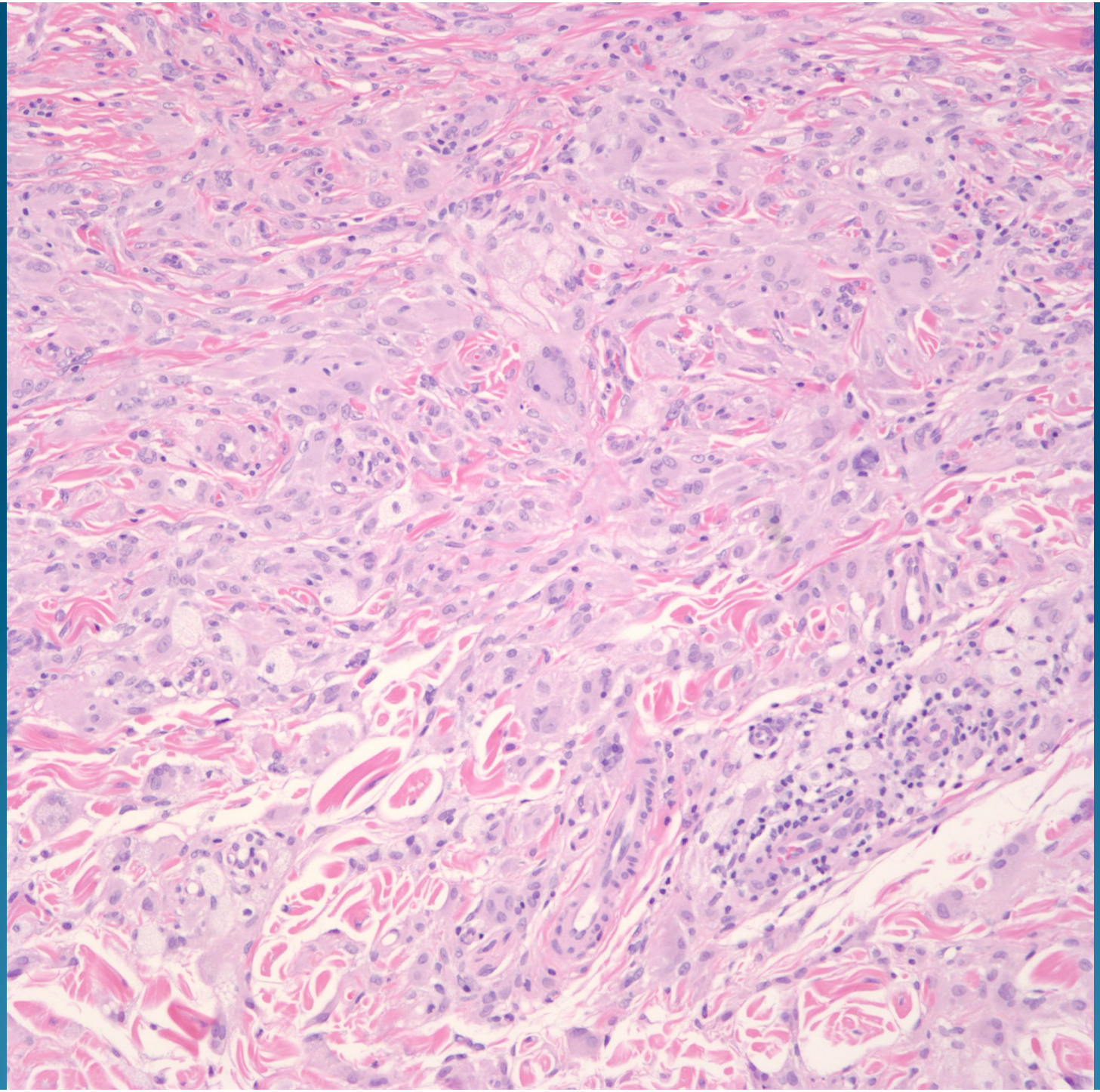

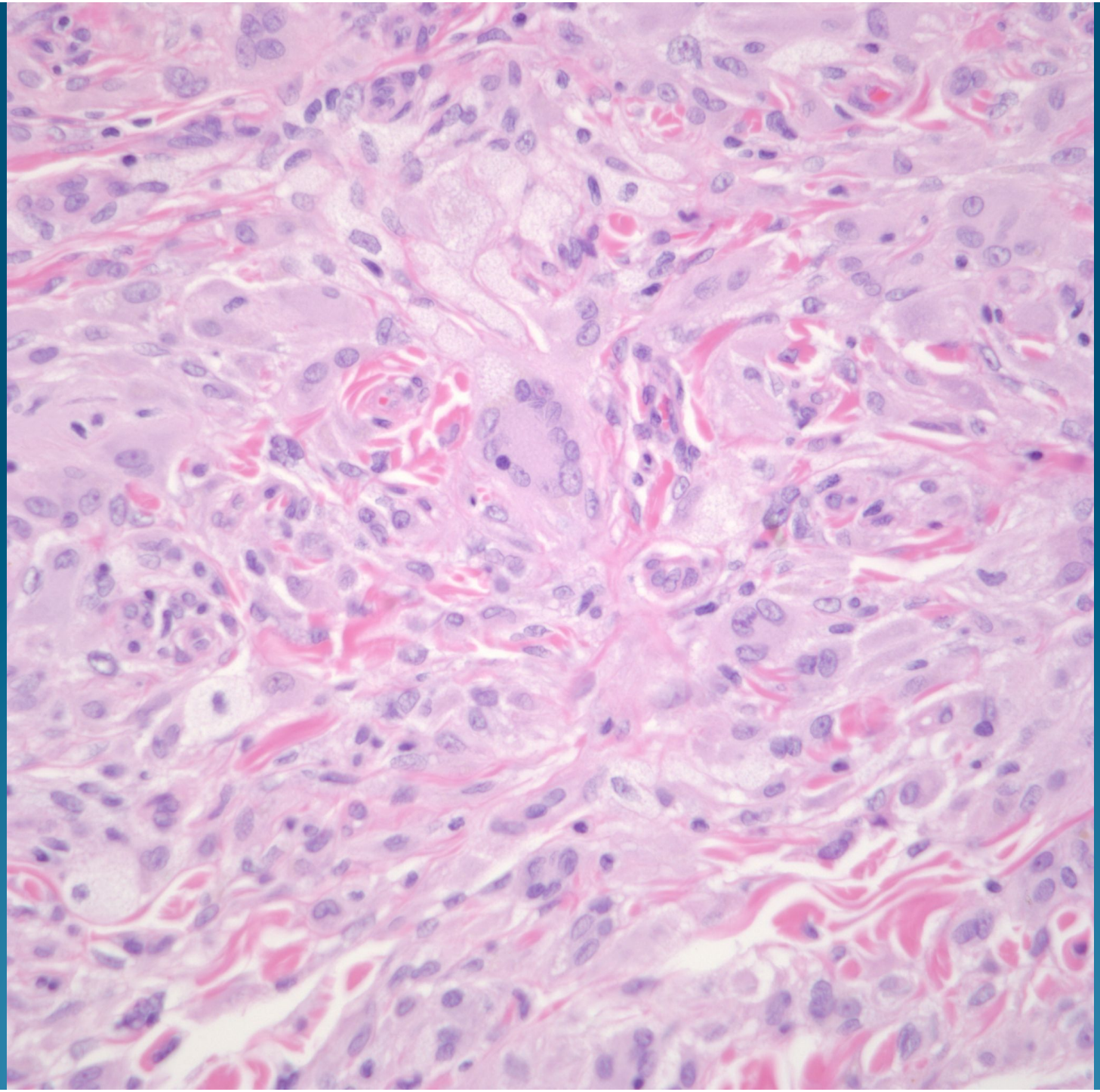

# What is the best diagnosis?

A. Xanthogranuloma
B. Langerhans cell histiocytosis
C. Reticulohistiocytoma
D. Mastocytoma
E. Balloon cell nevus

# Xanthogranuloma

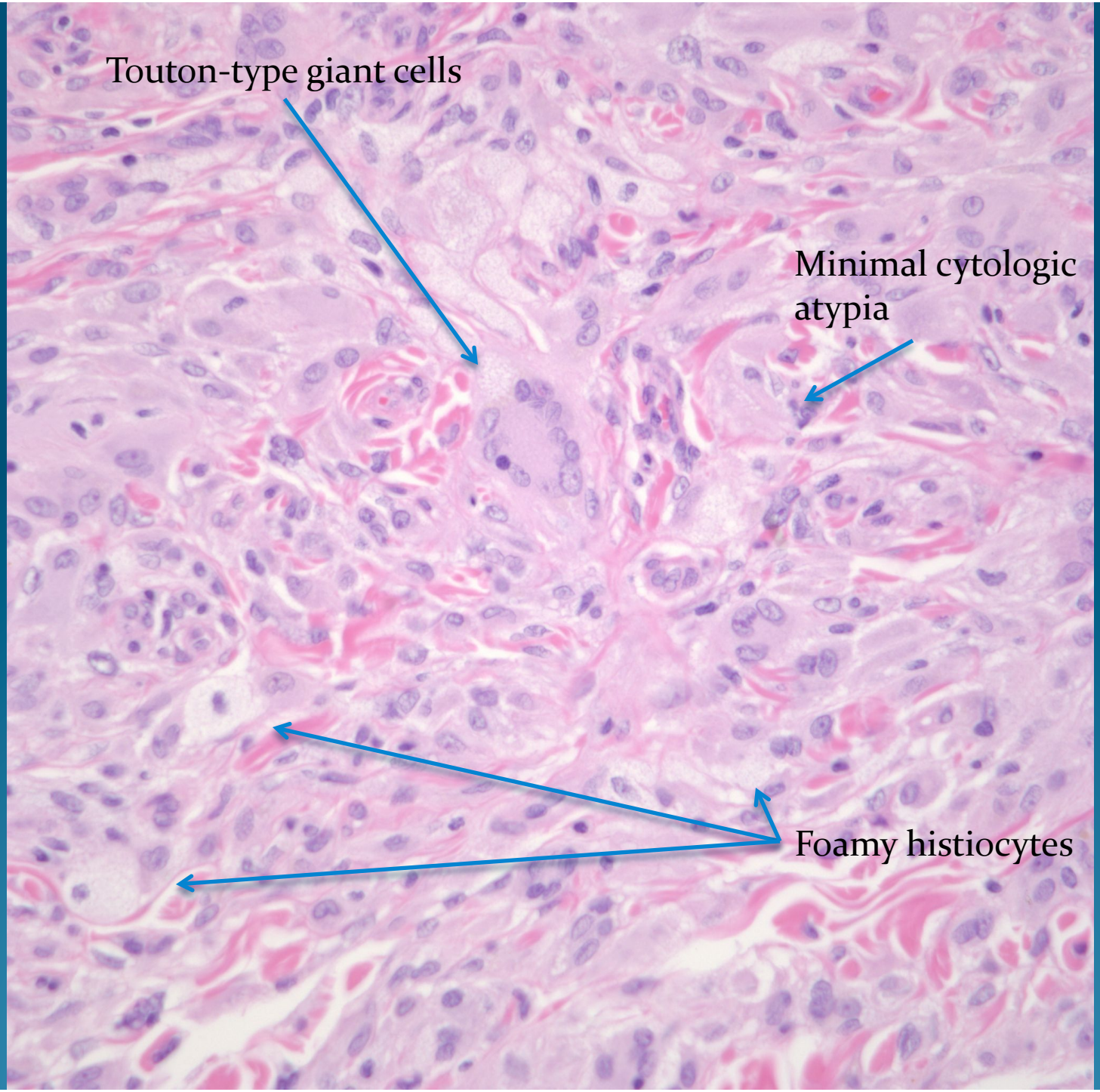
Touton-type giant cells
Minimal cytologic atypia
Foamy histiocytes