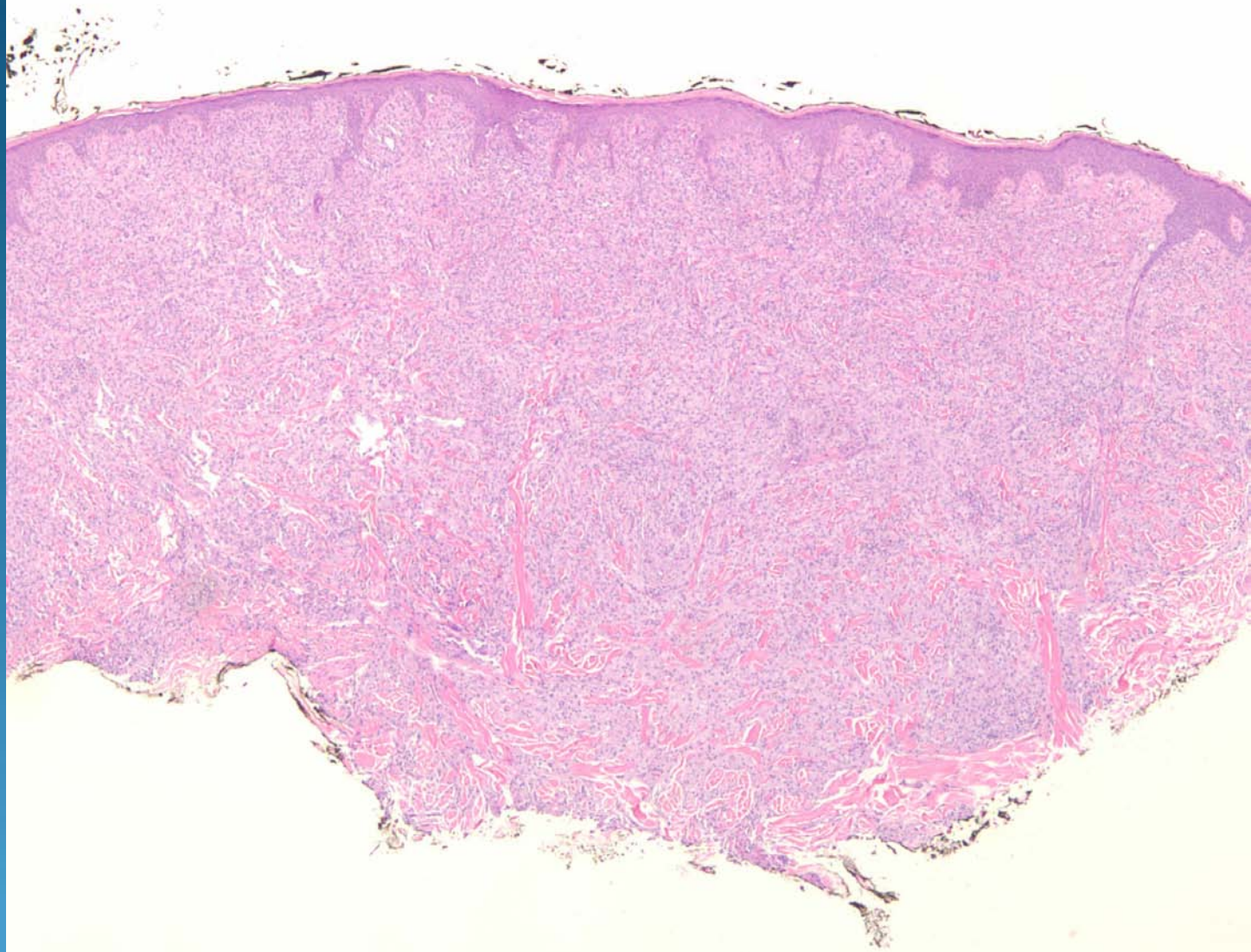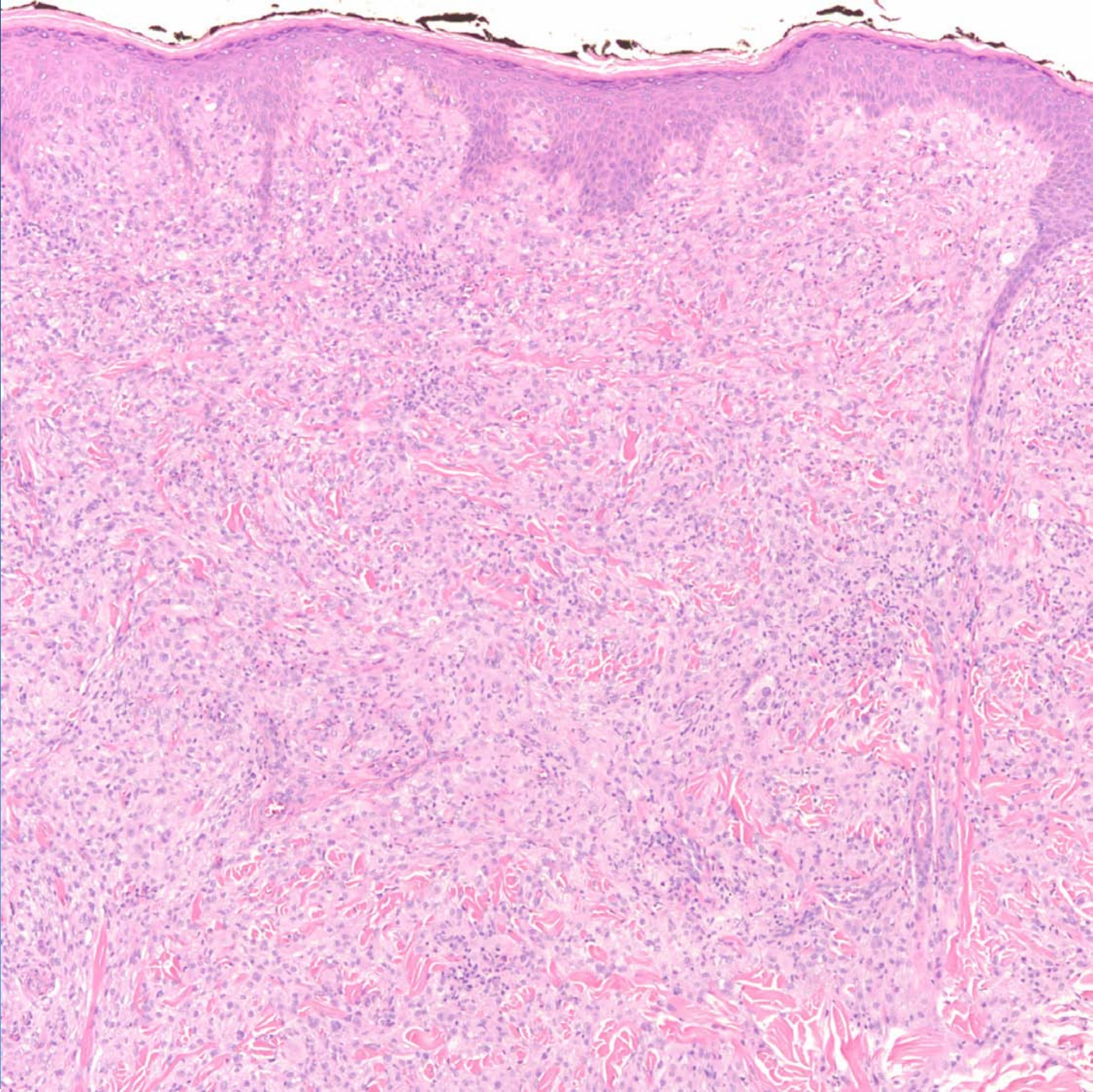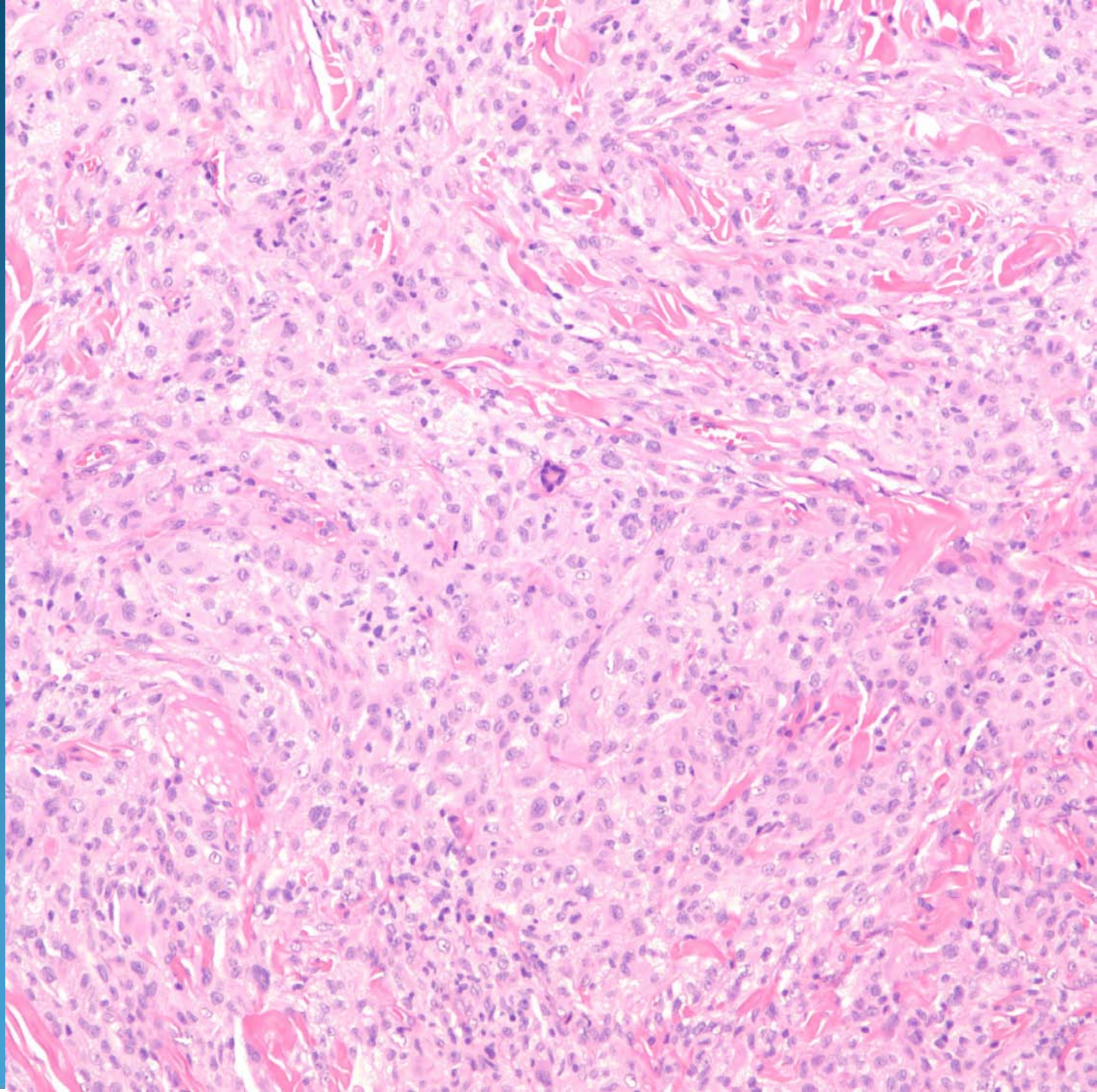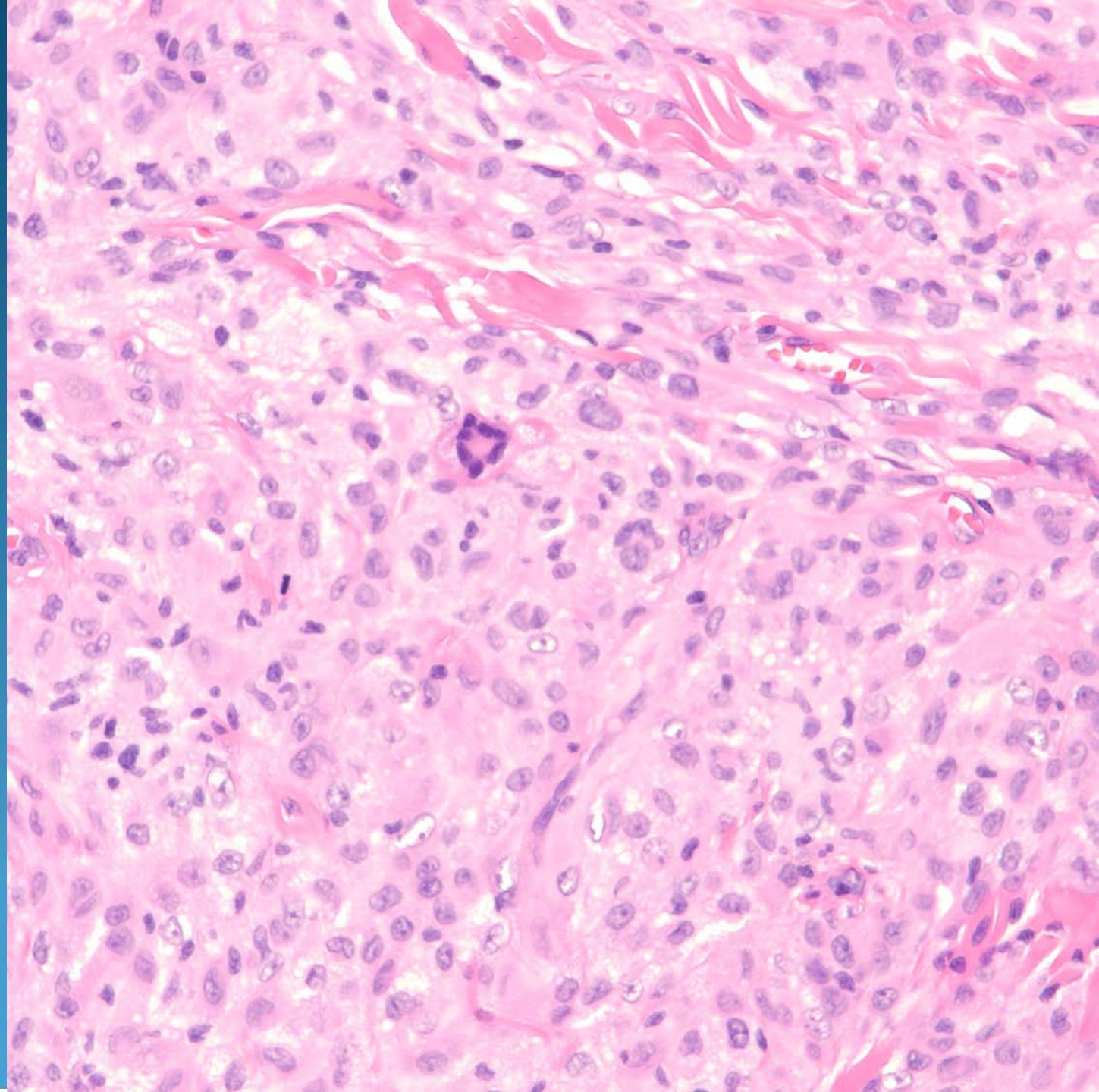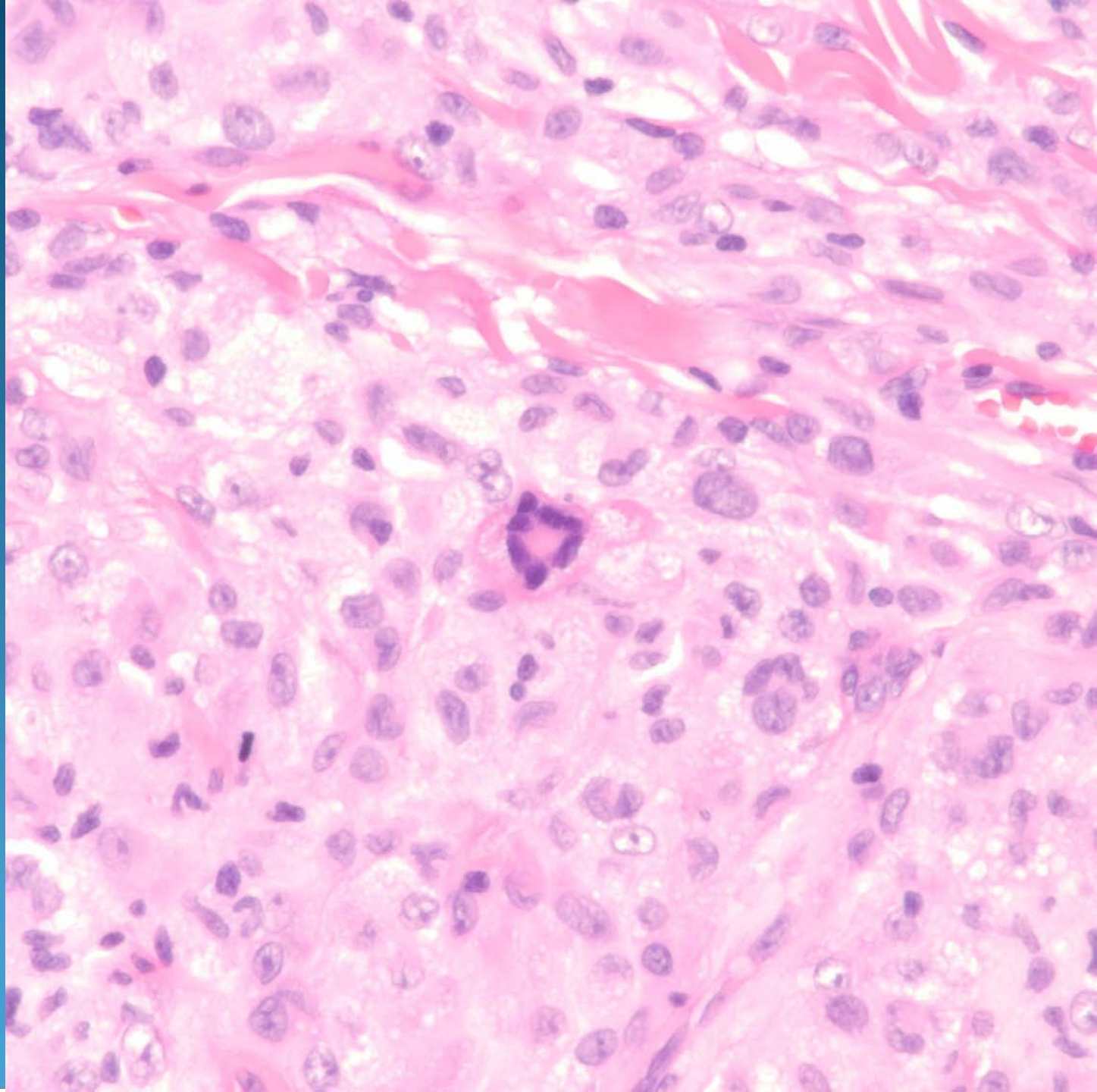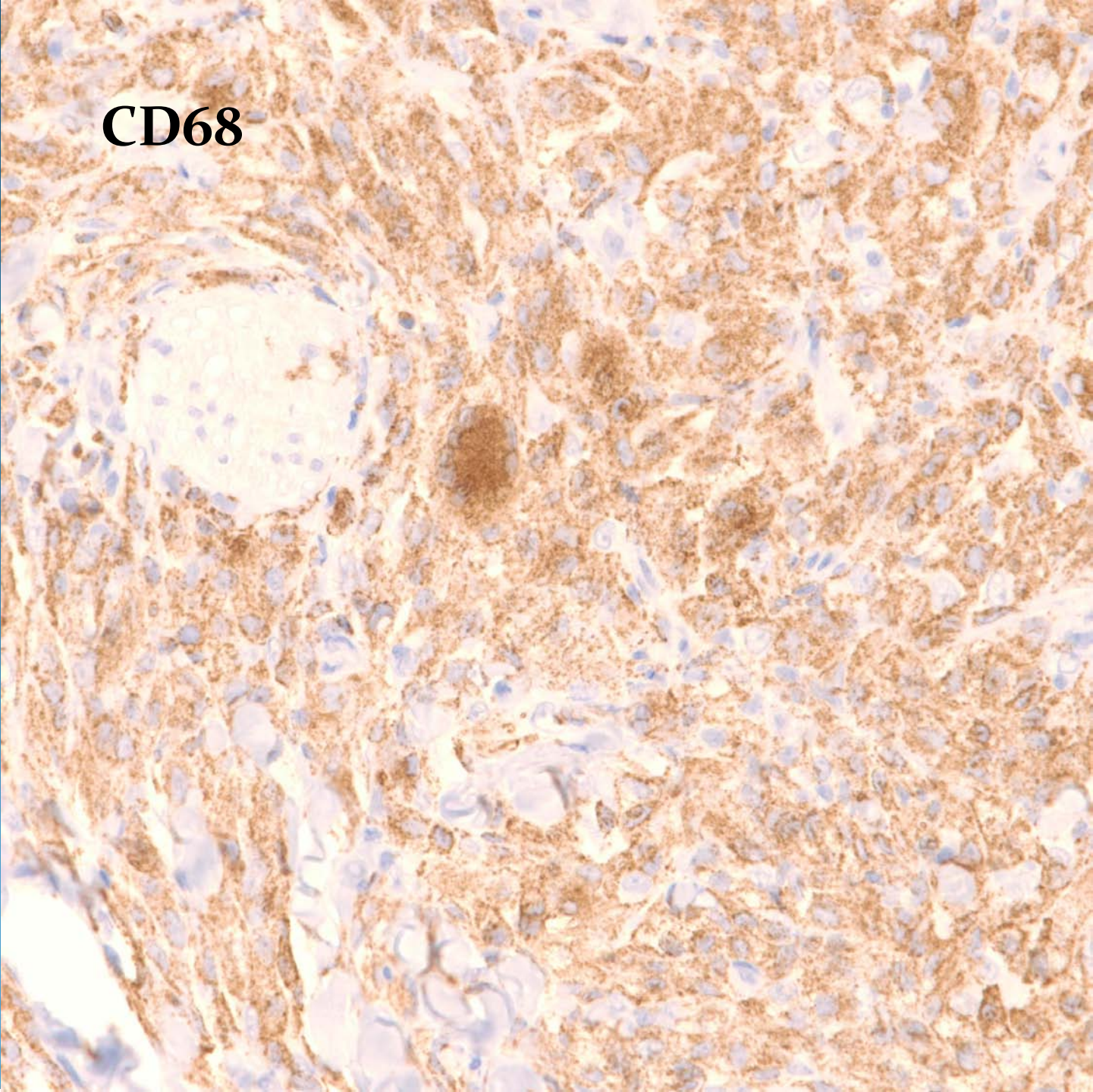
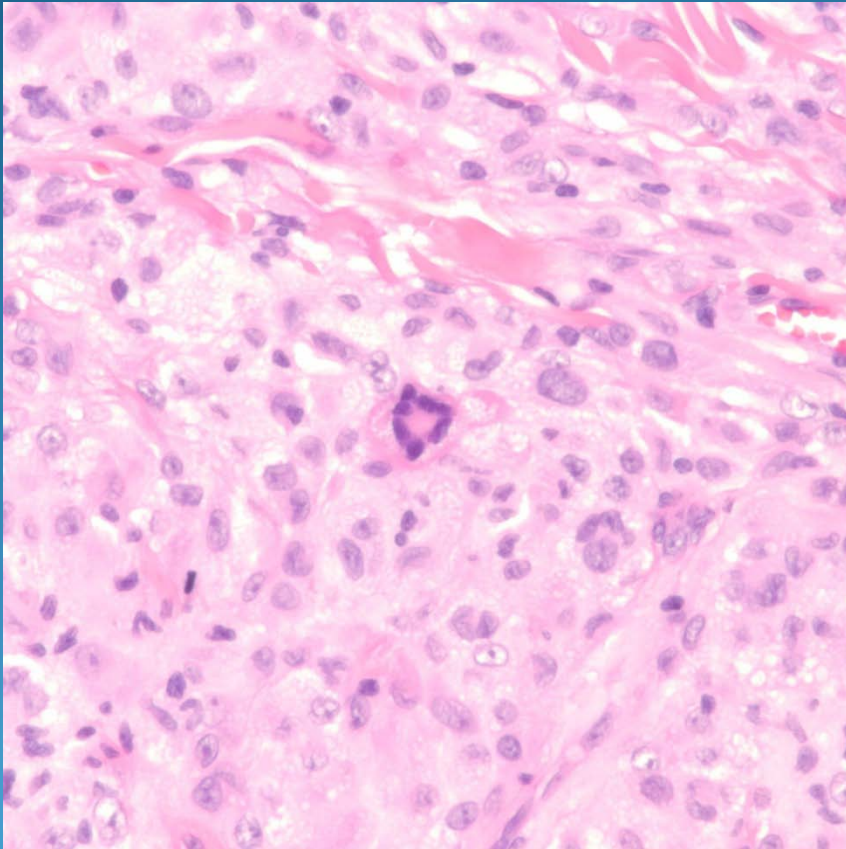


Juvenile Xanthogranuloma

CD68



Pearls



- Nodule of foamy histiocytes (look for bubbly cytoplasm)
- Should have numerous Touton-type giant cells
- Minimal chronic inflammation