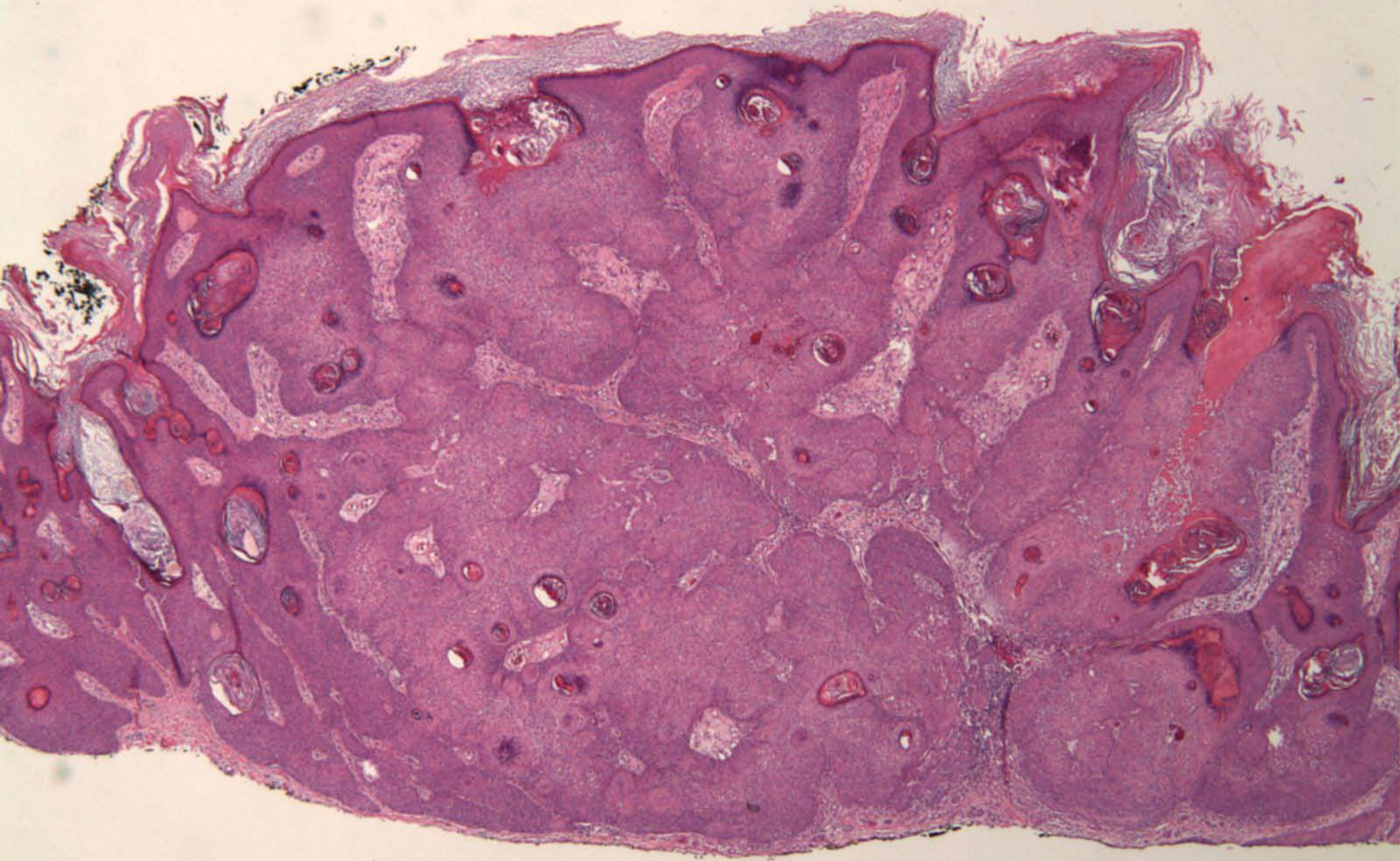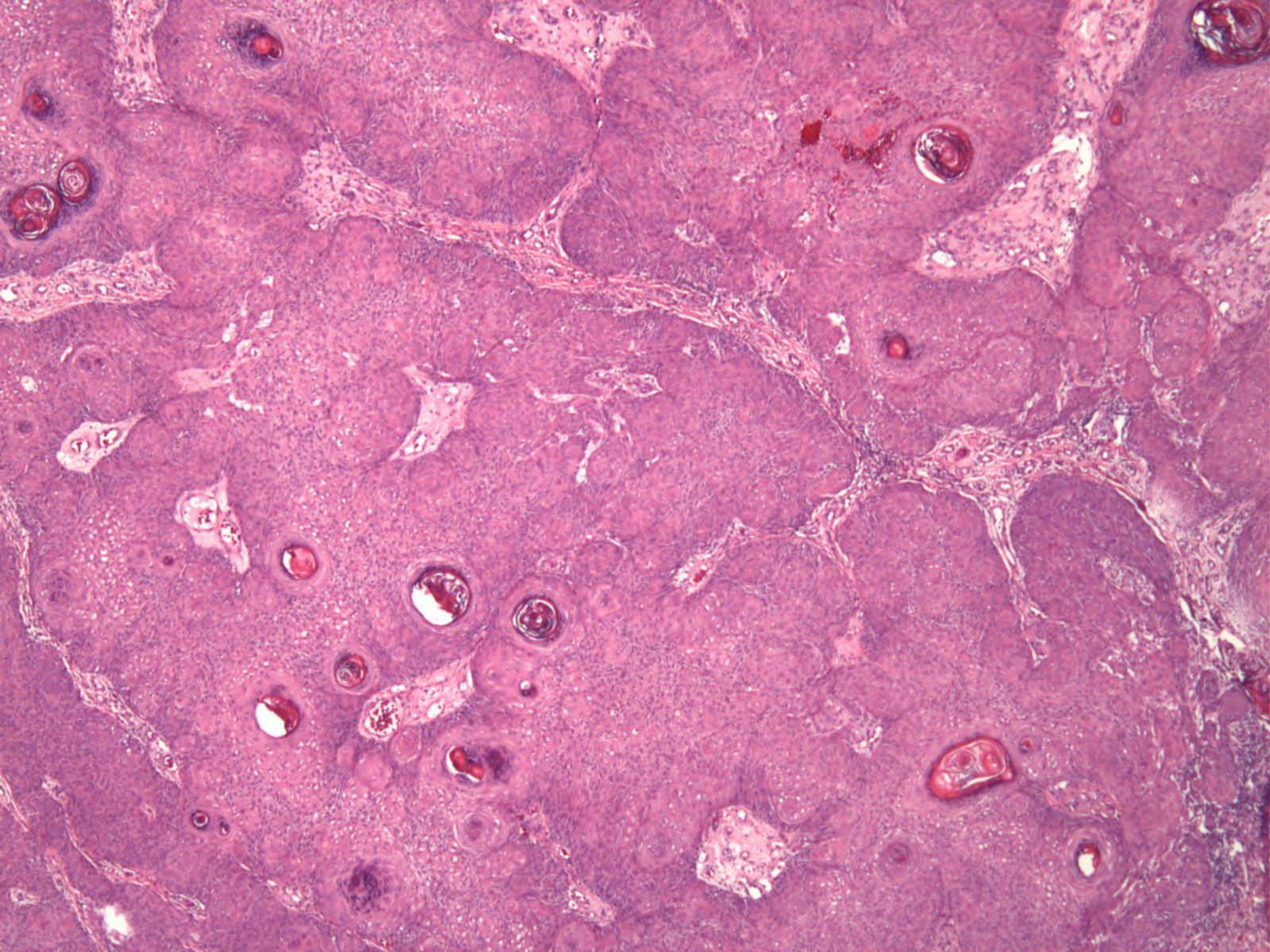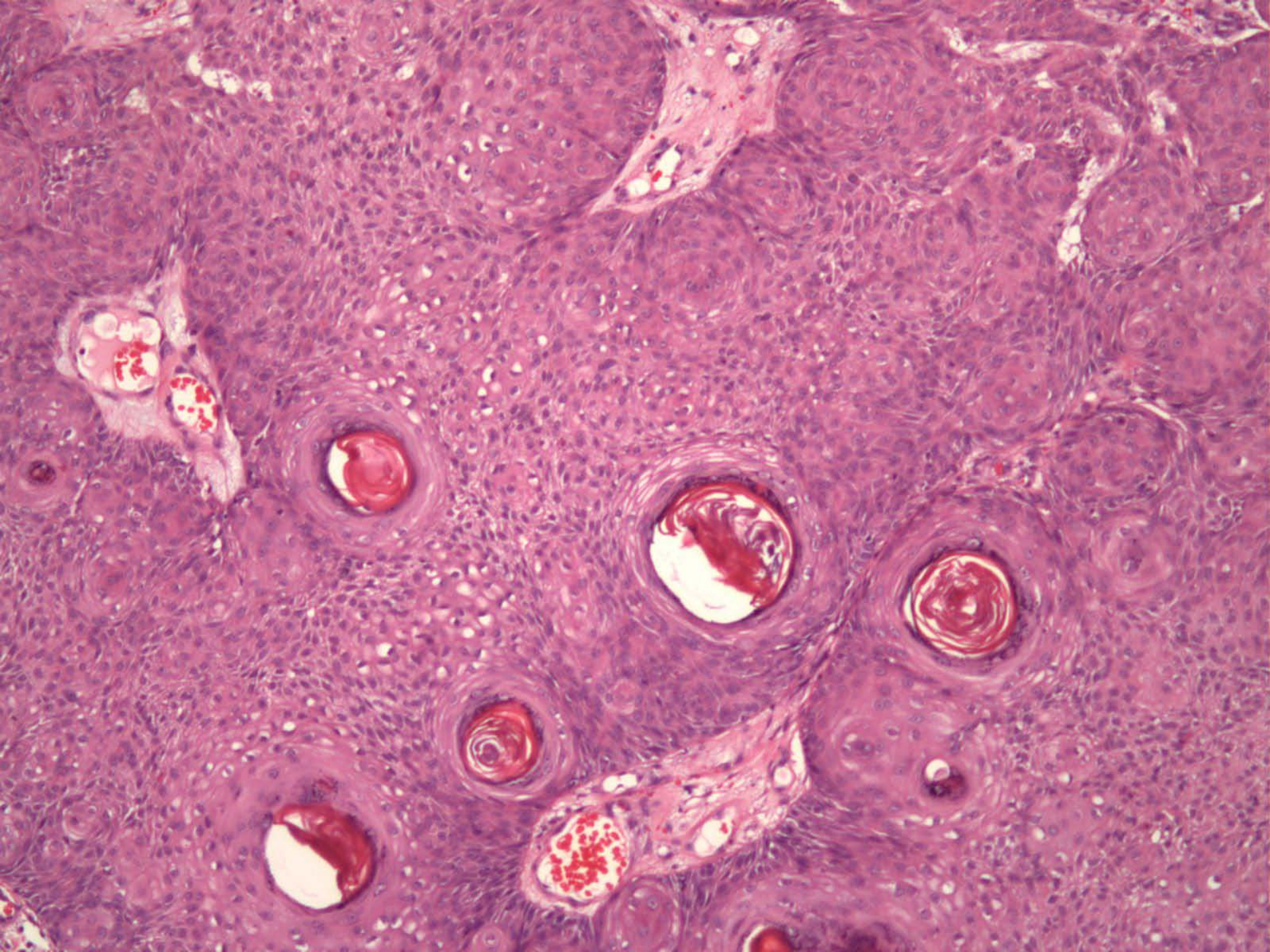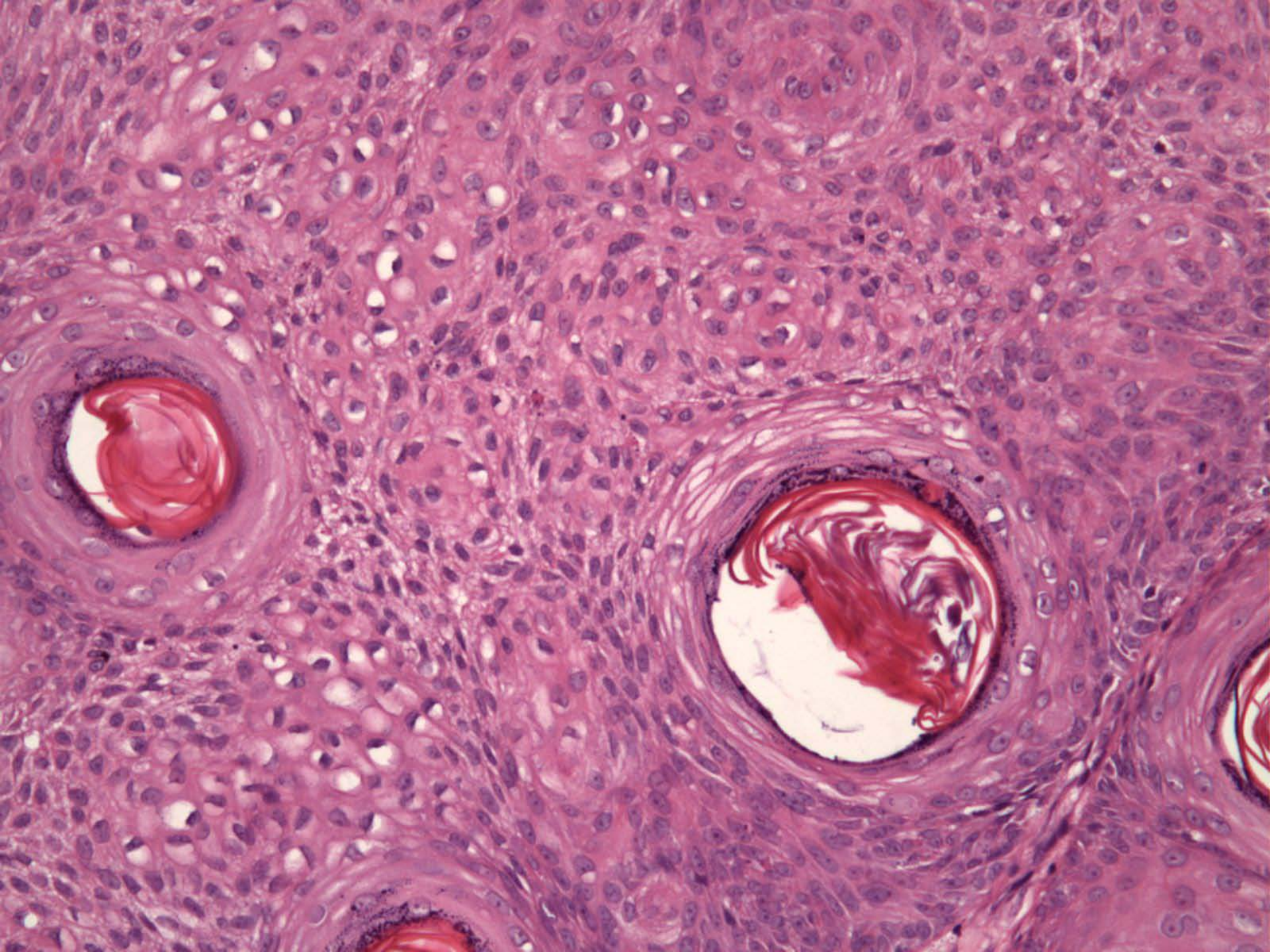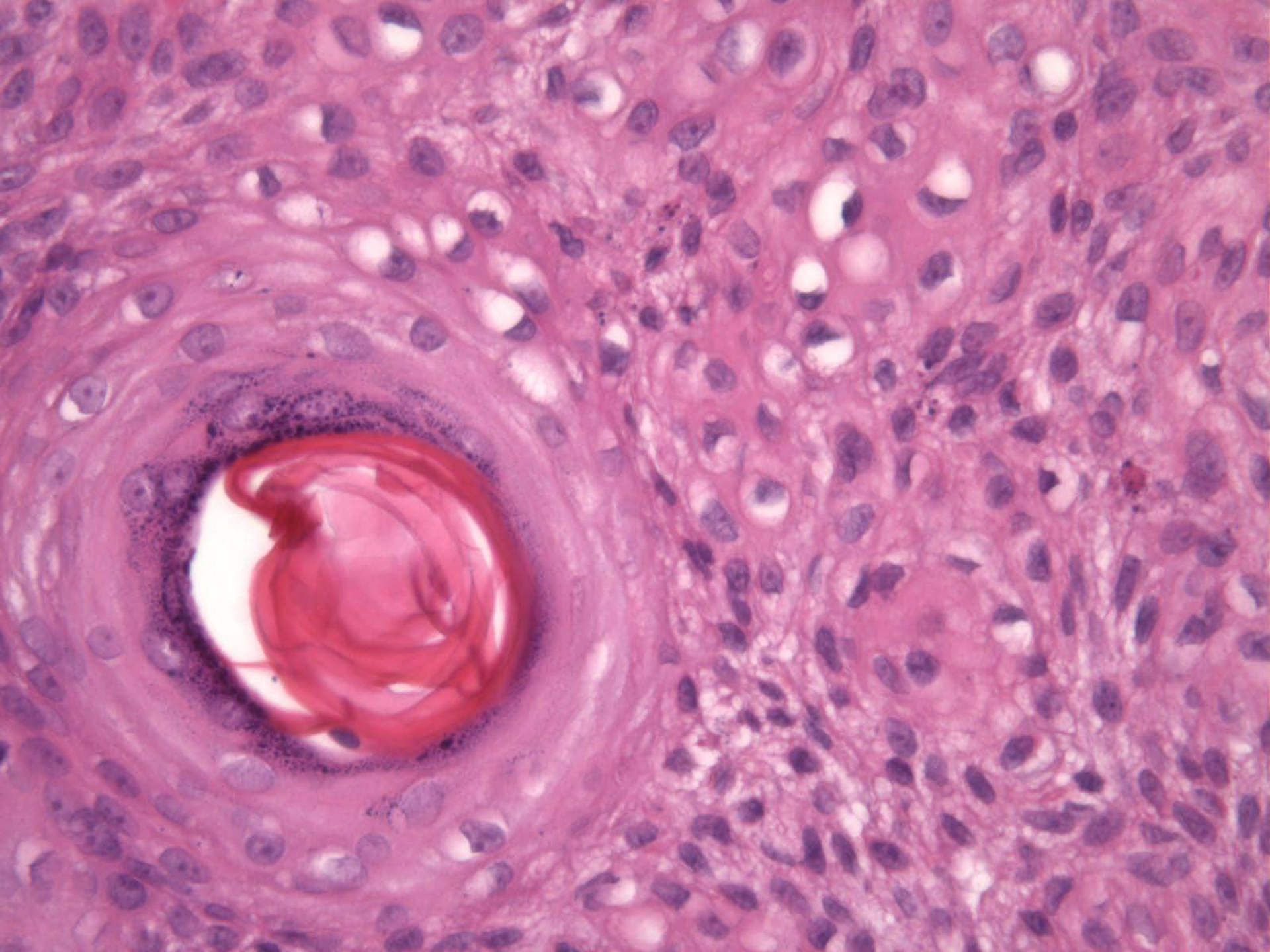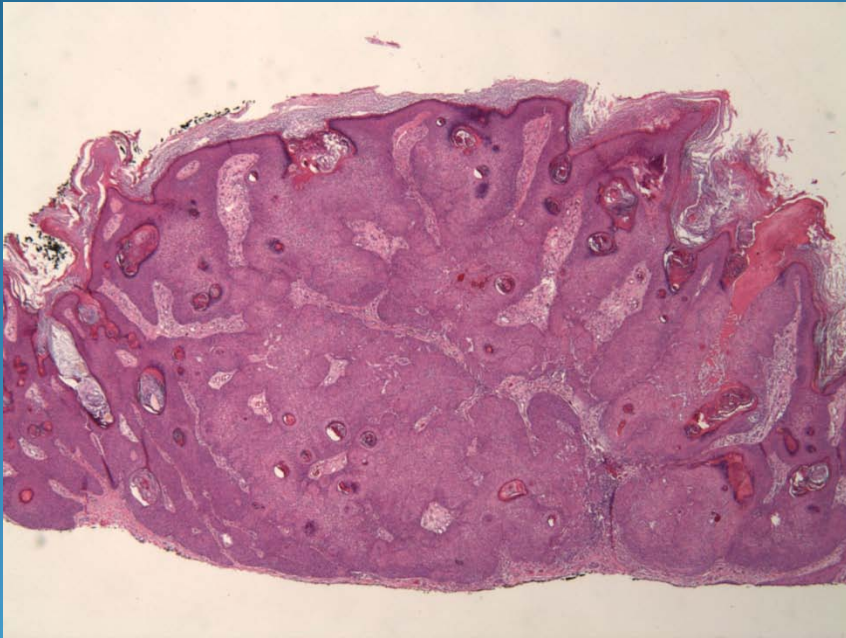


# Inverted Follicular Keratosis/ Irritated Seborrheic Keratosis

# Pearls



- Numerous squamous eddies
- No atypia
- Flat to rounded base
- Resembles a vertically oriented seborrheic keratosis growing into a hair follicle