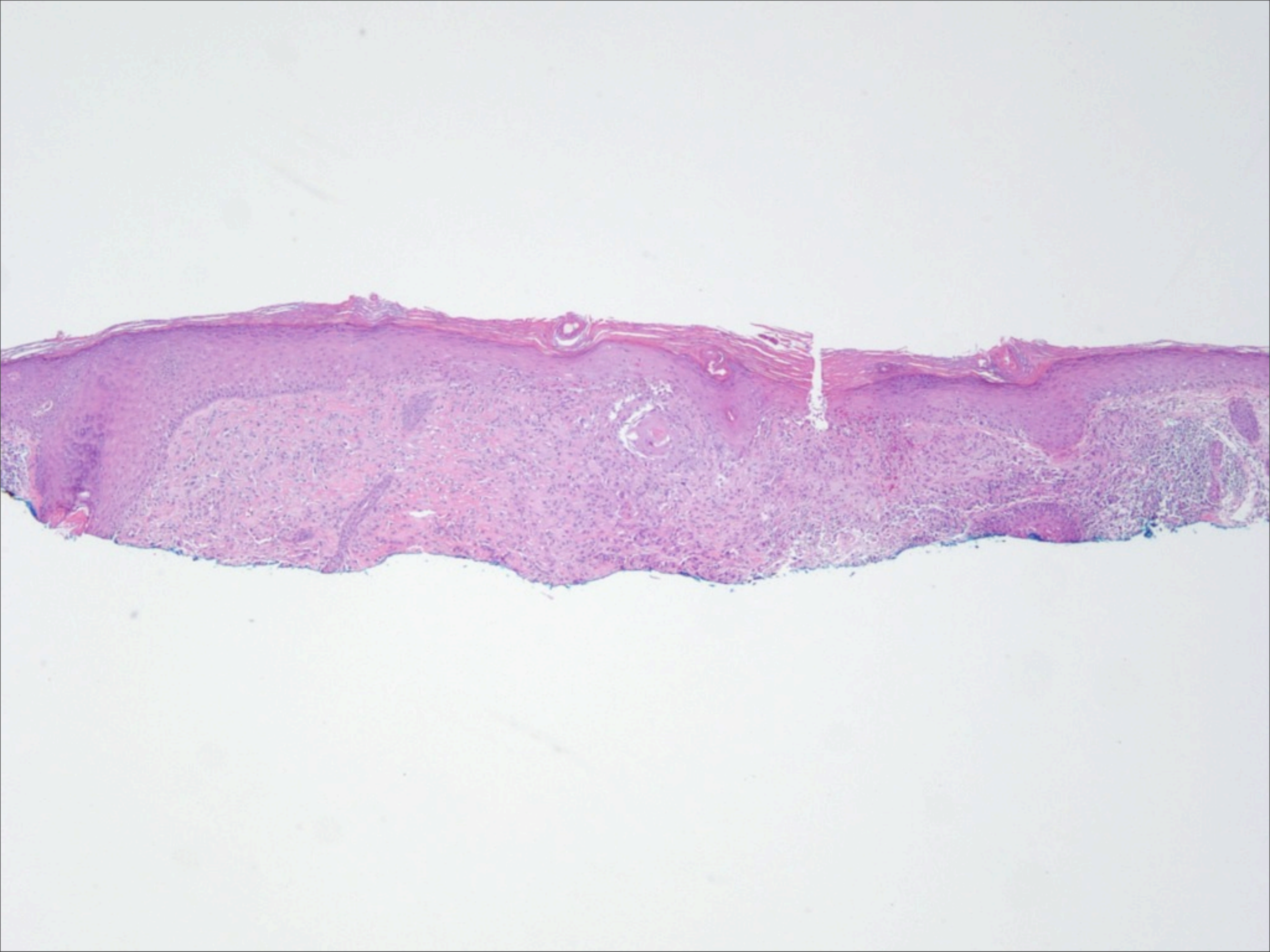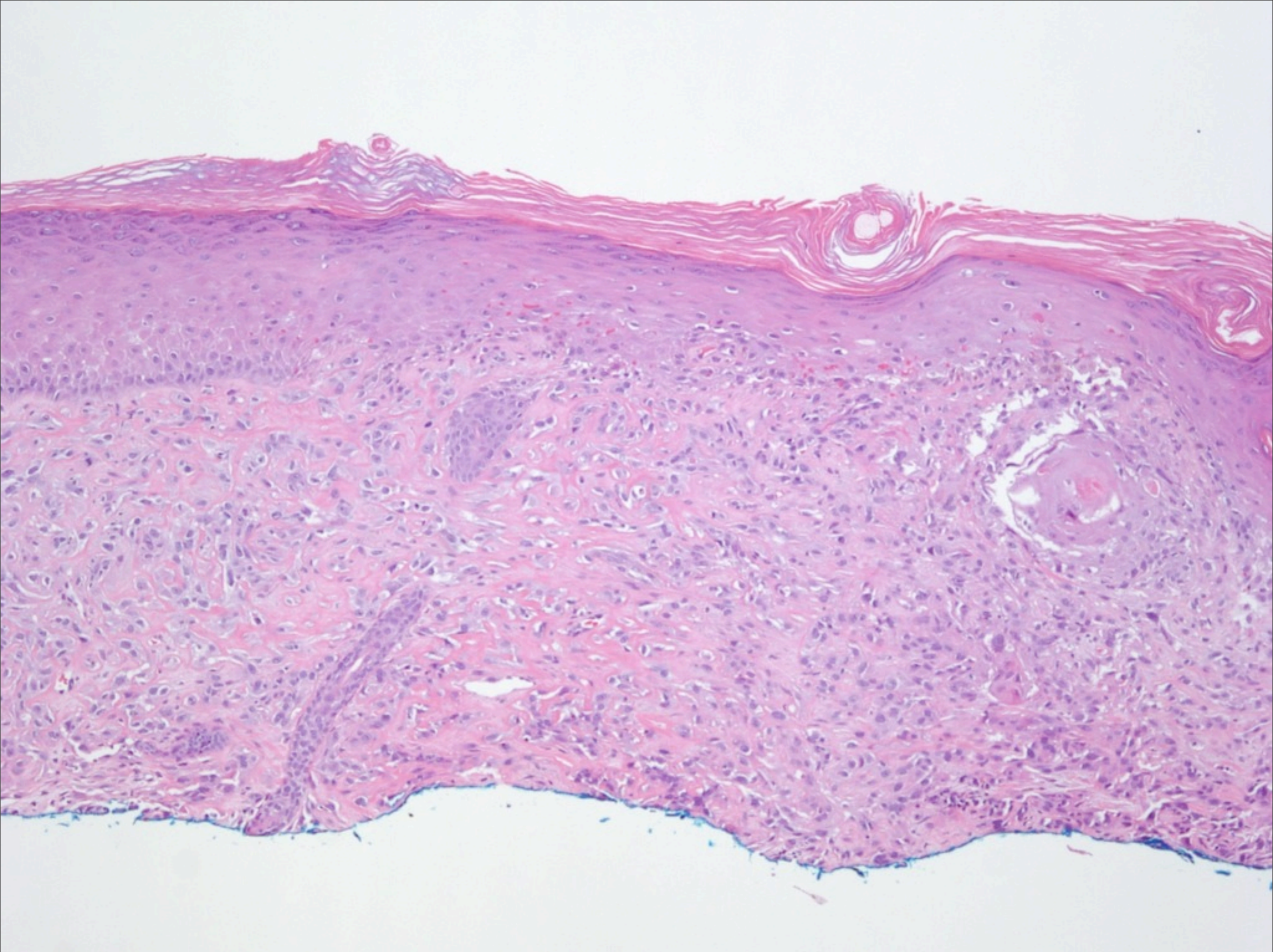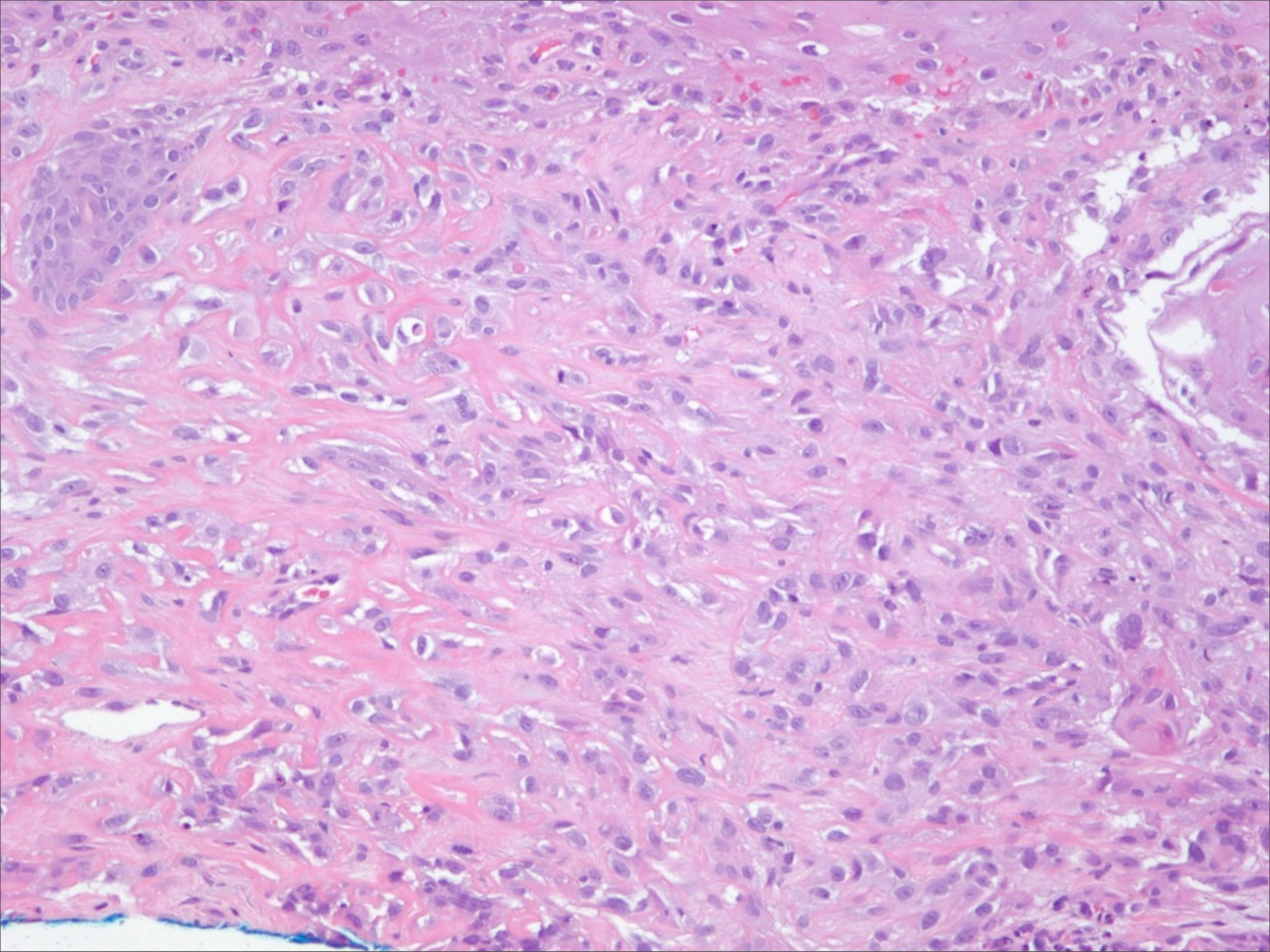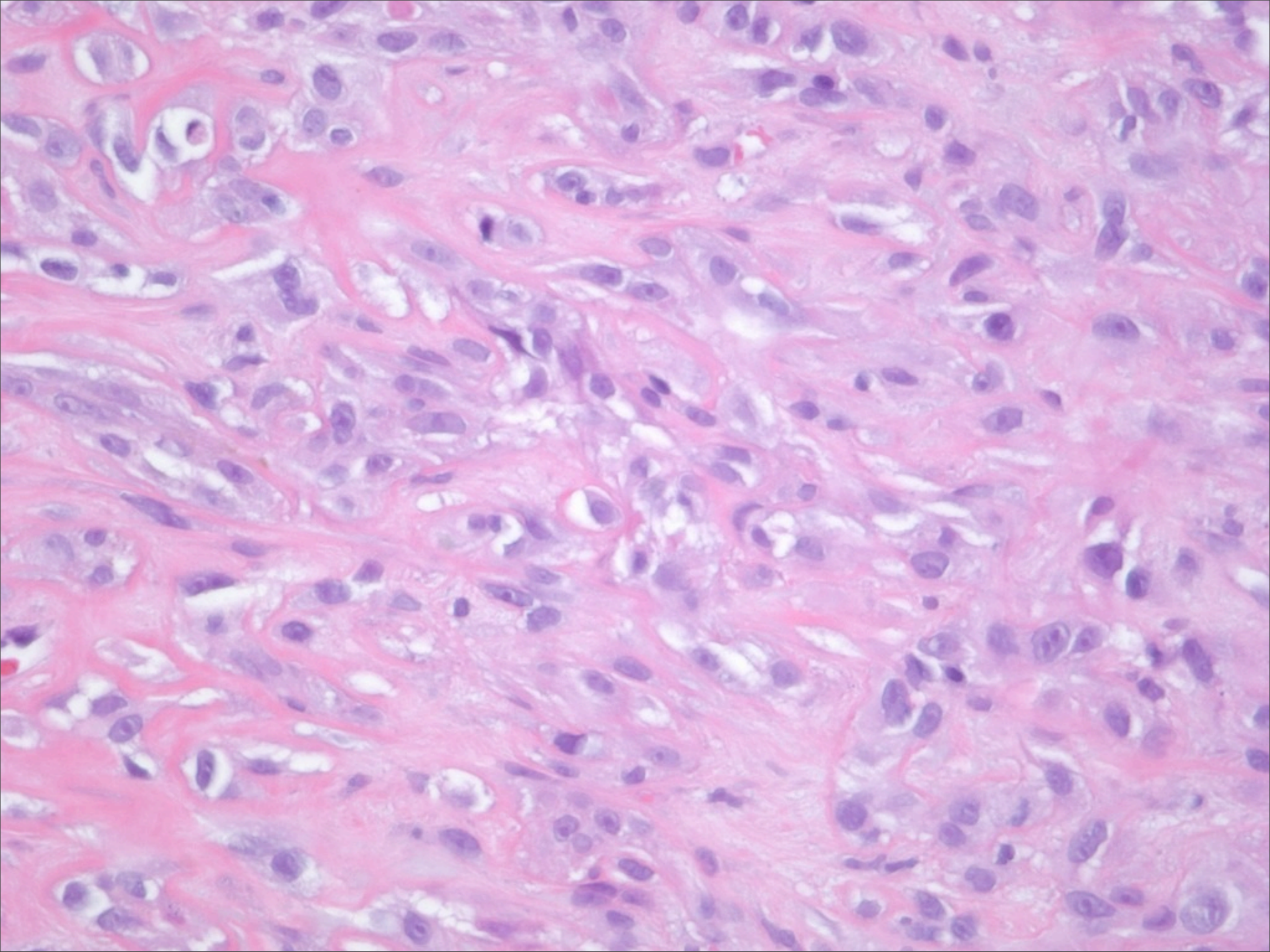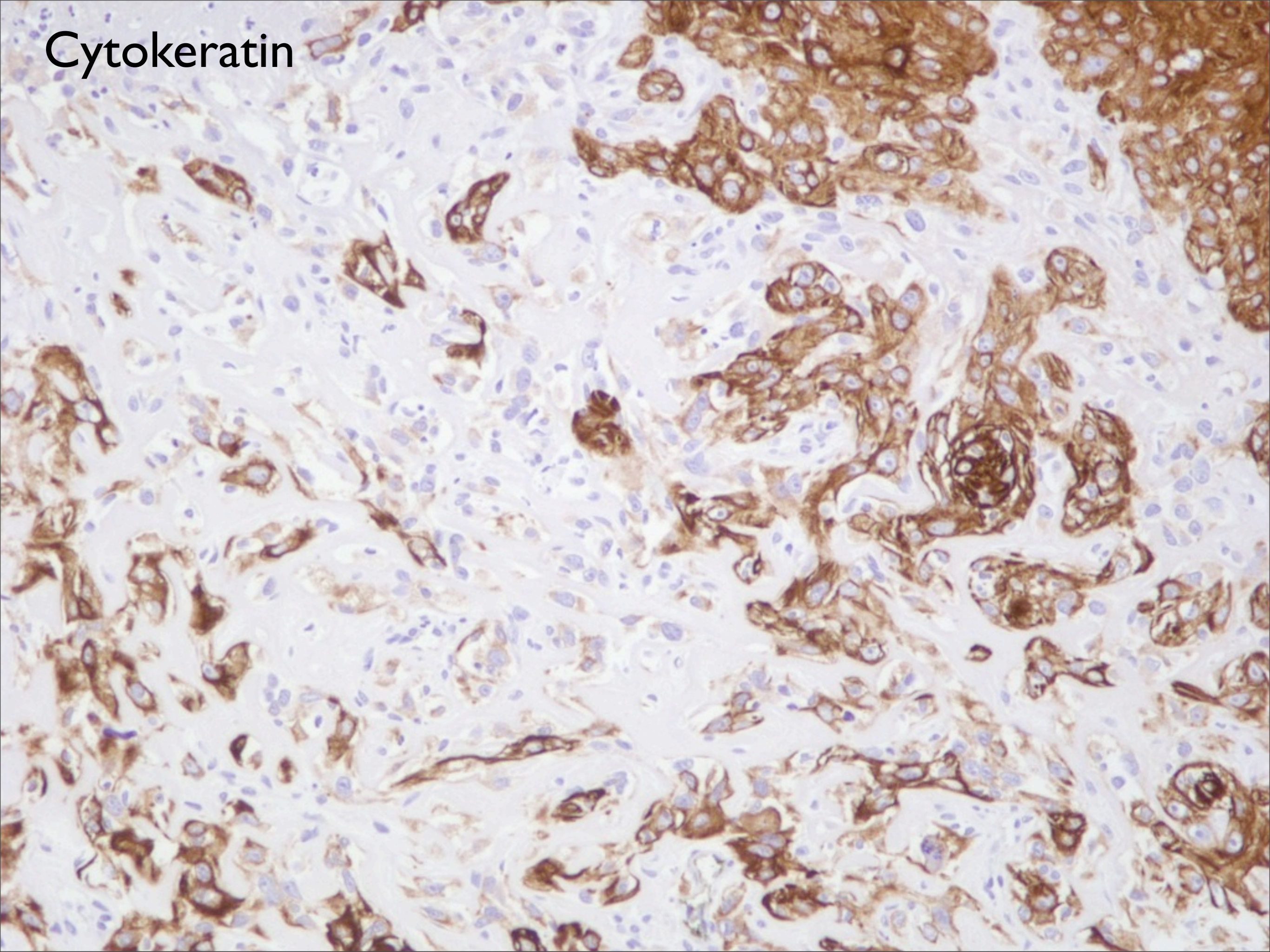


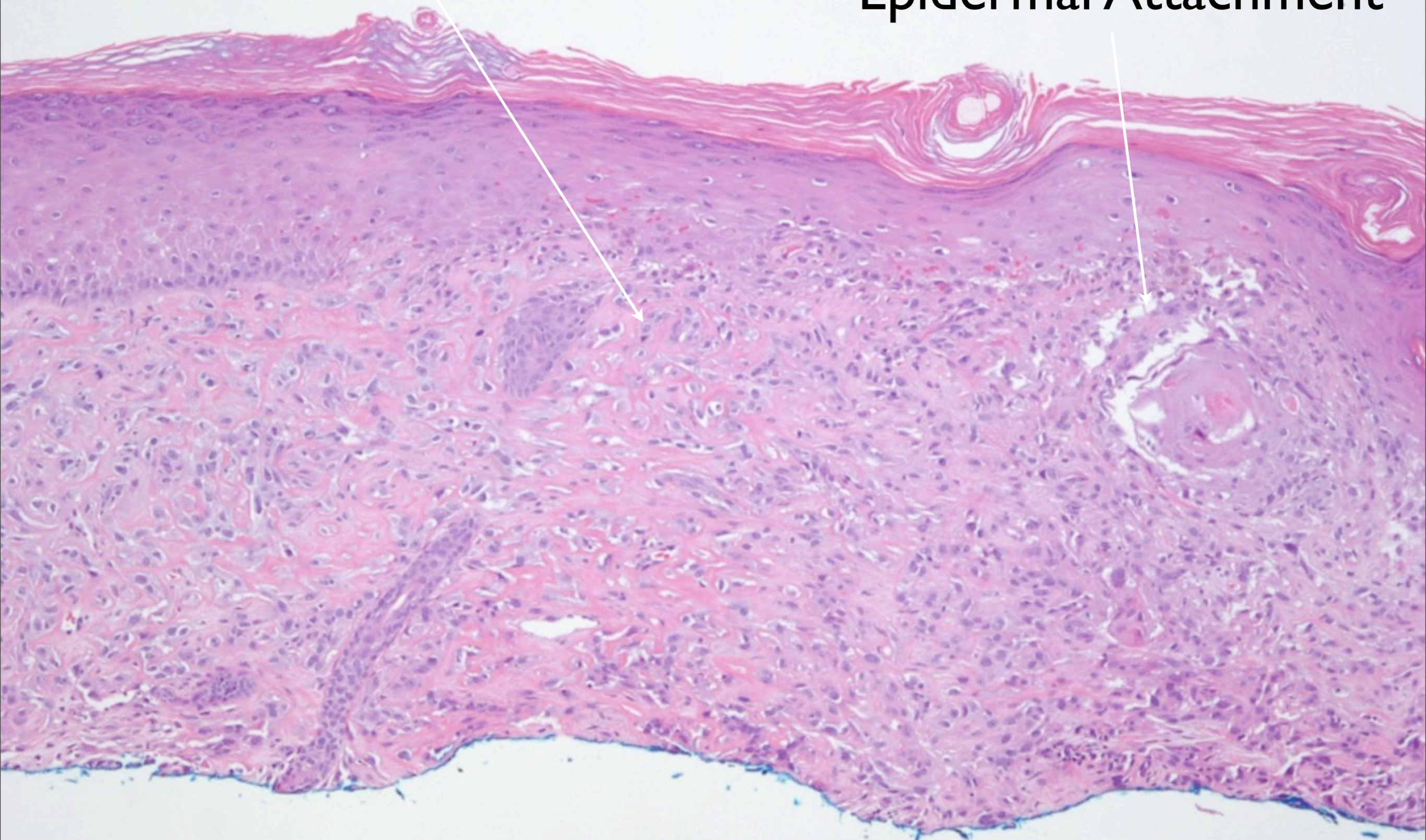
Cytokeratin



Invasive Squamous Cell Carcinoma, Poorly Differentiated

Infiltrative nest of pleomorphic cells

Epidermal Attachment



Confirm with Immunohistochemistry