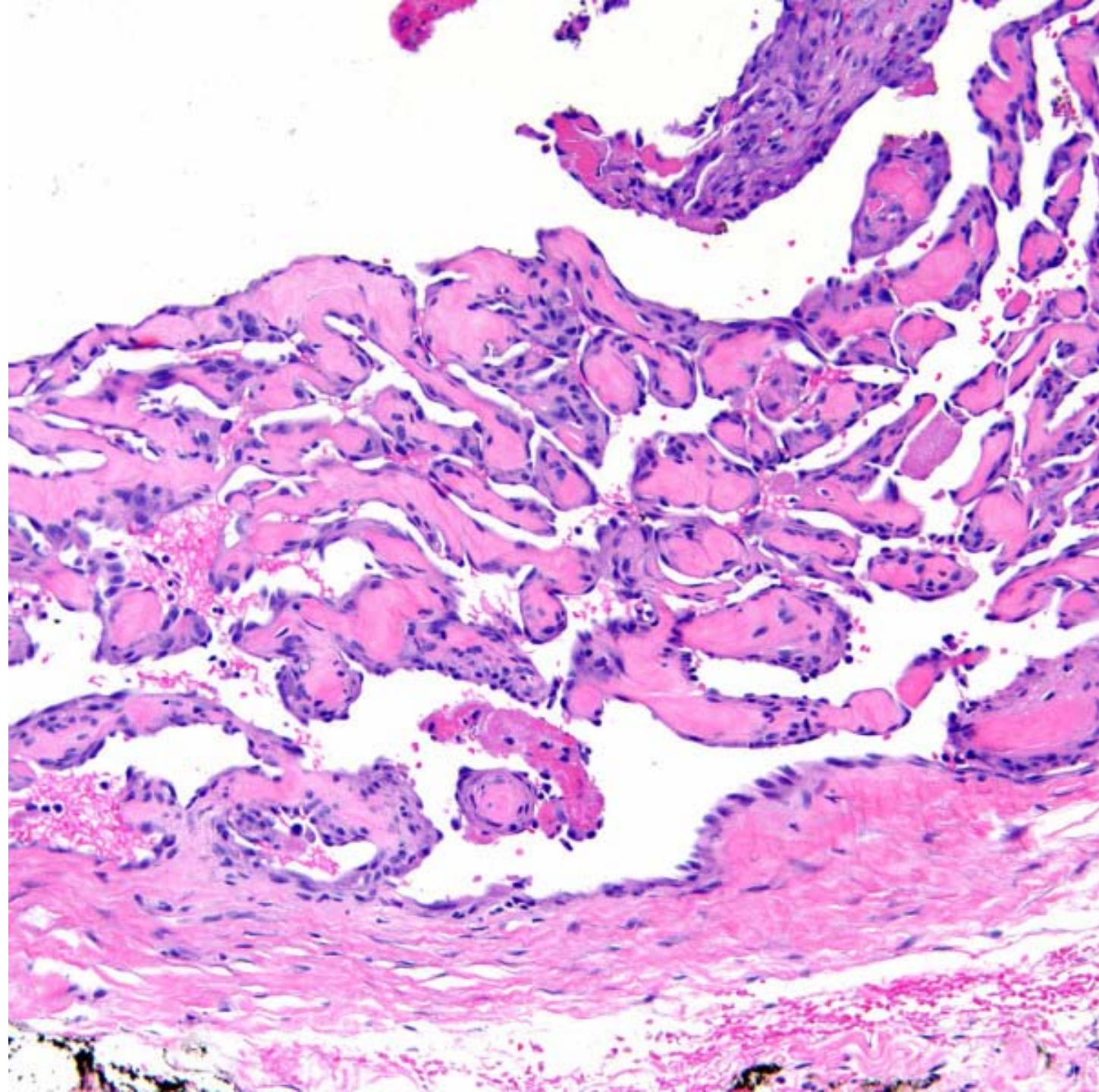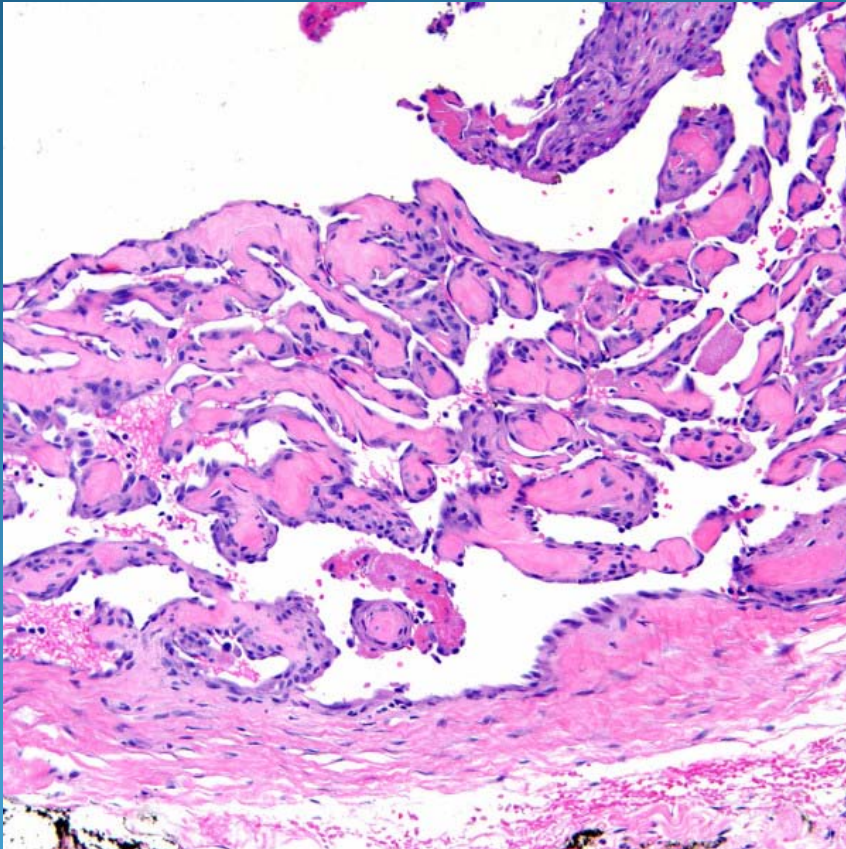


Intravascular Papillary Endothelial Hyperplasia (Masson's Tumor)

Pearls



- Look for large lumen or edge of muscular vessel wall
- Papillary outgrowths from wall associated with fibrin
- This is an exuberant organizing thrombus