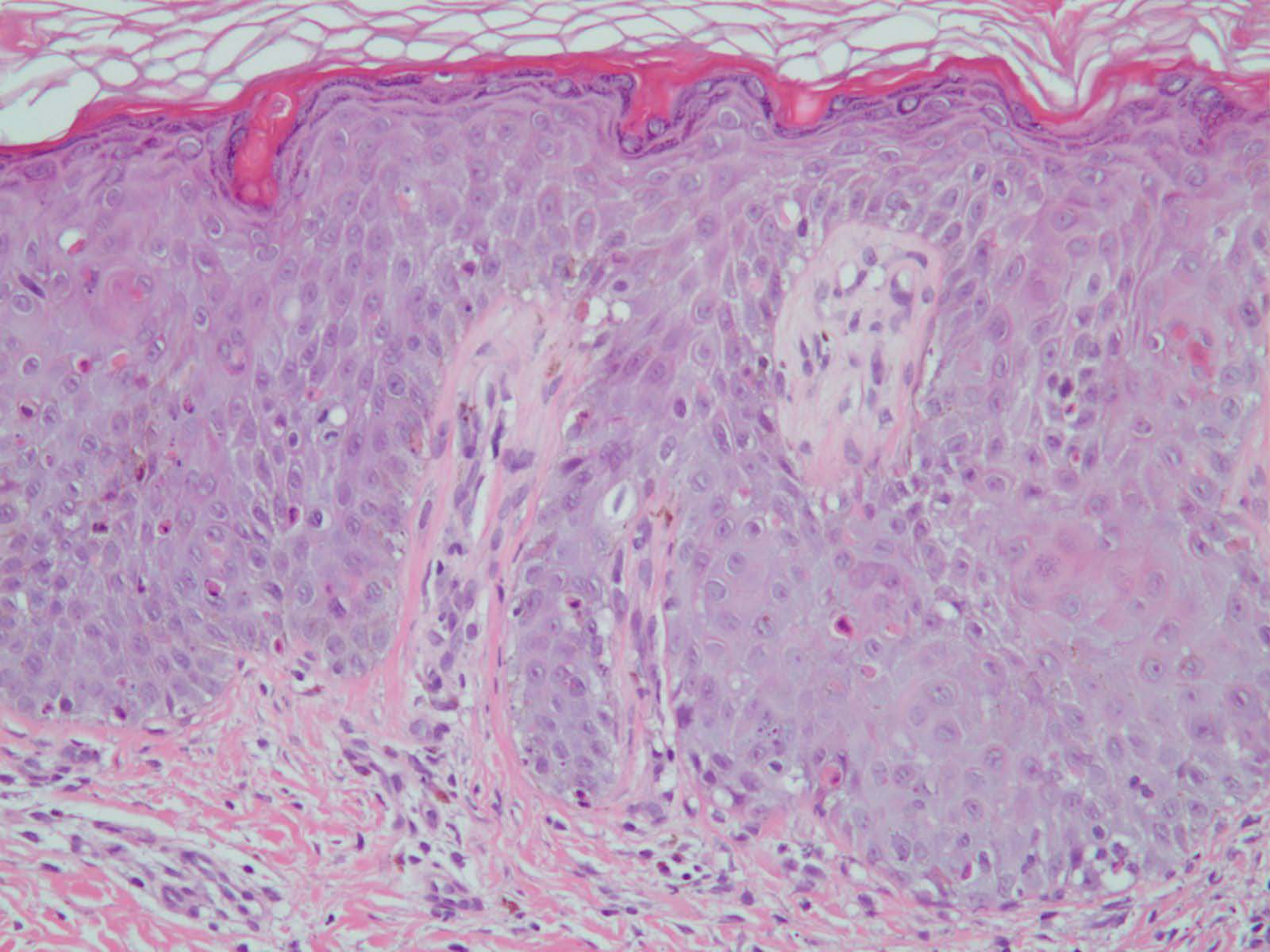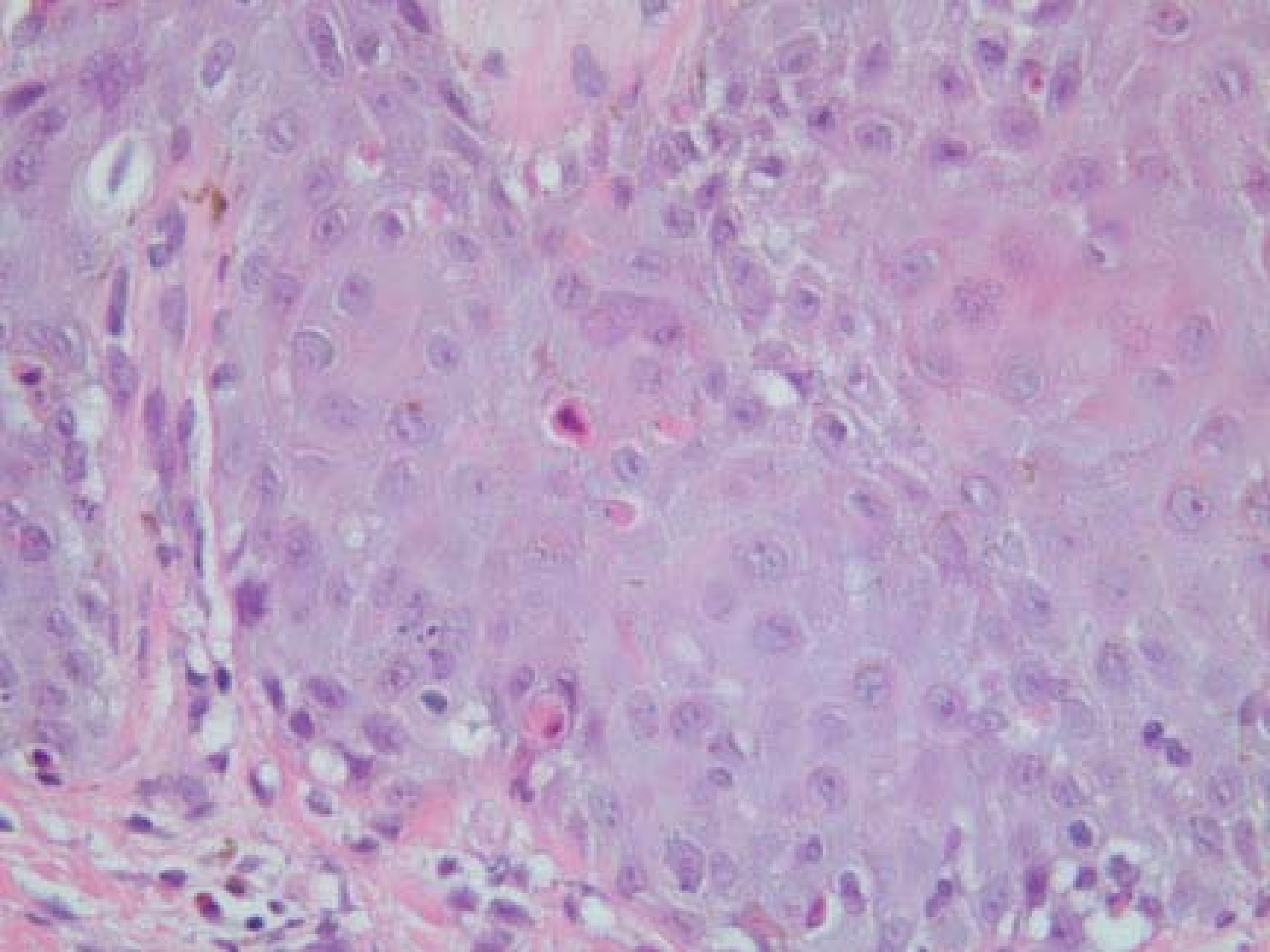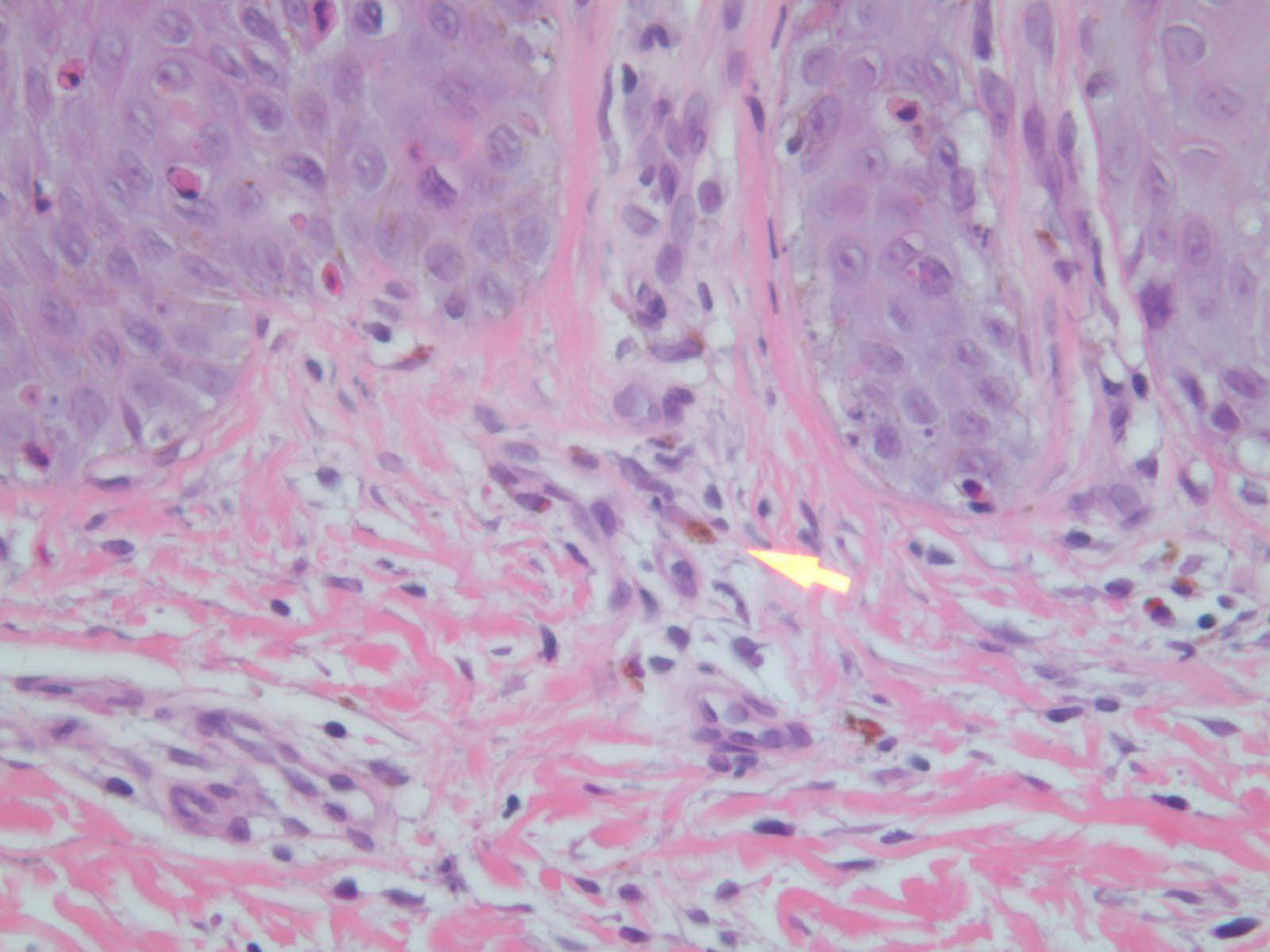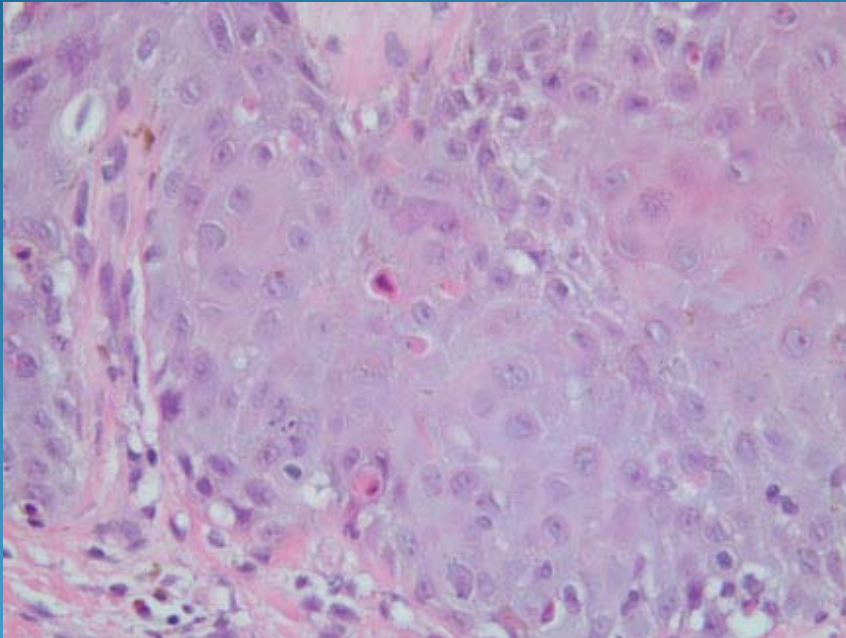


Incontinentia pigmenti

Pearls



- Eosinophilic spongiosis with dyskeratotic keratinocytes
- Must have pigment incontinence
- Classic histopathology varies with clinical stage of disease