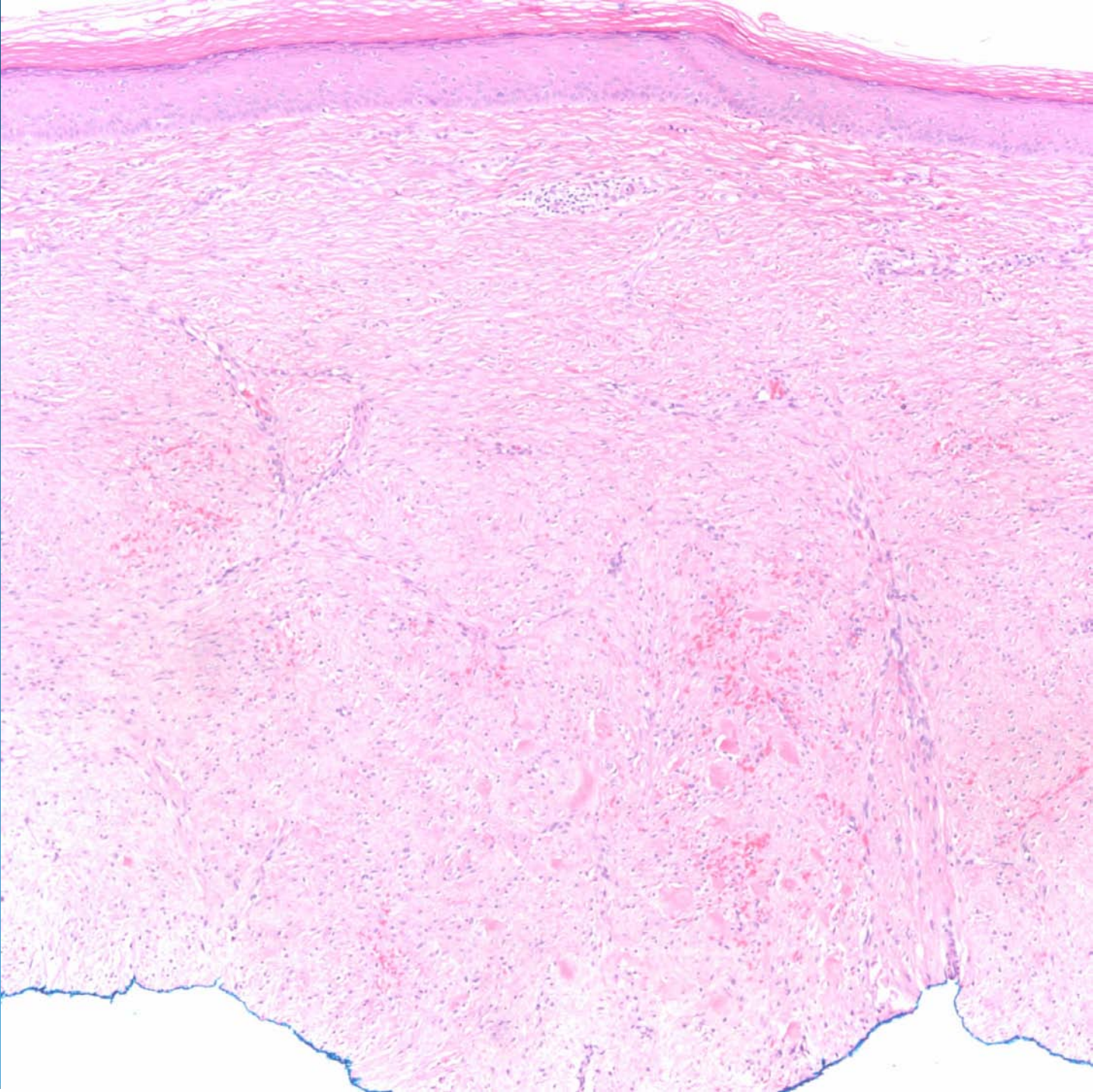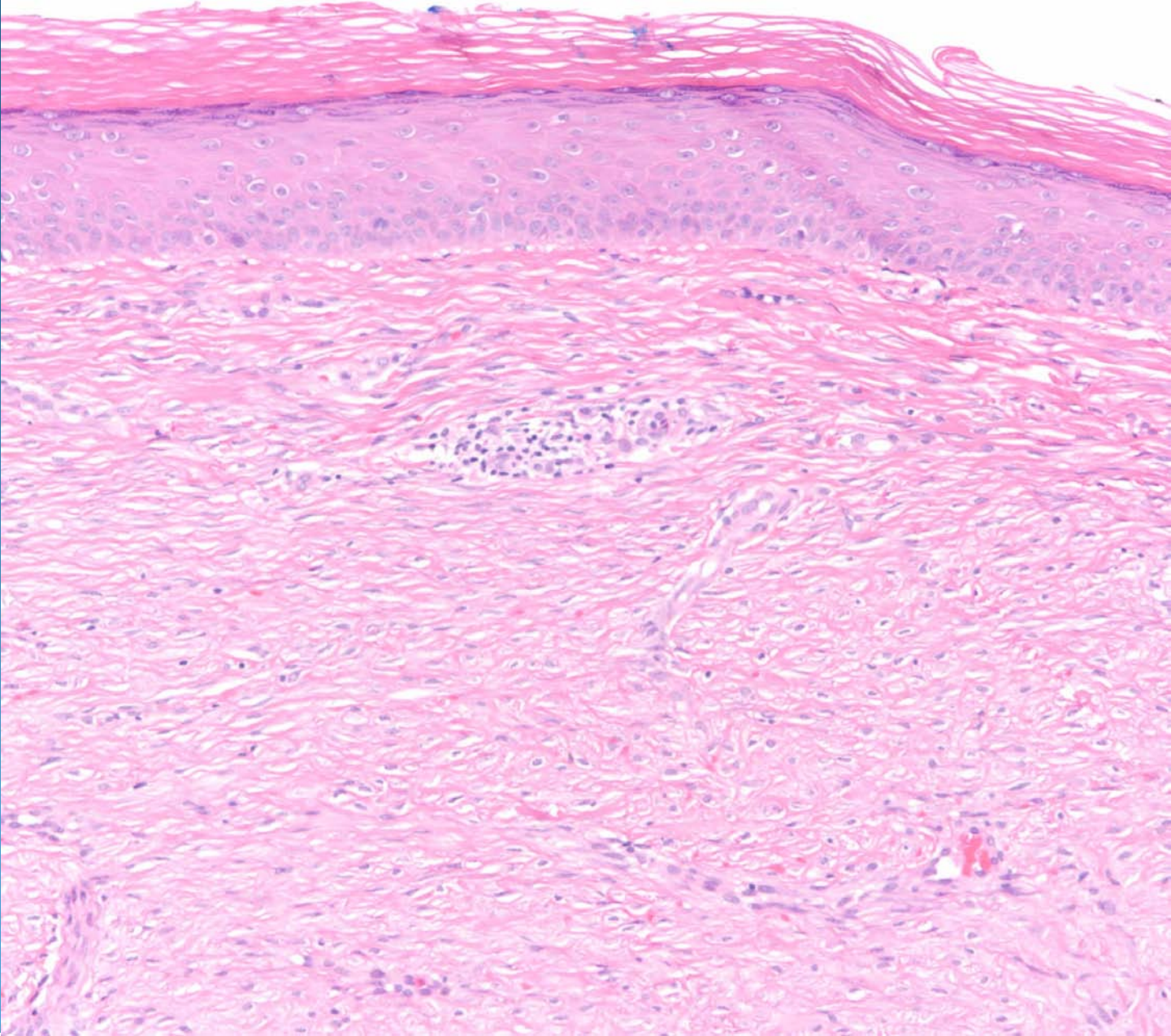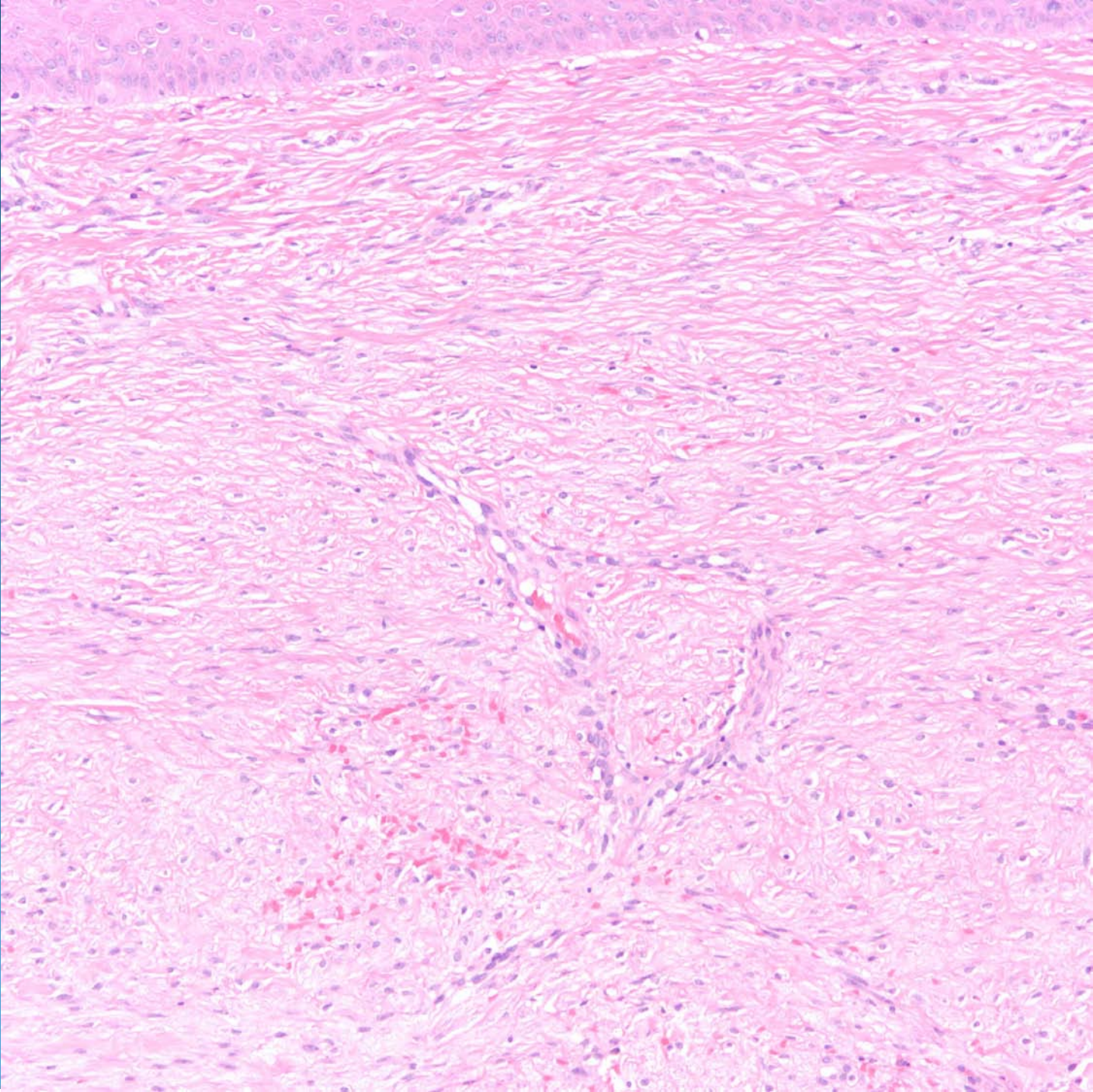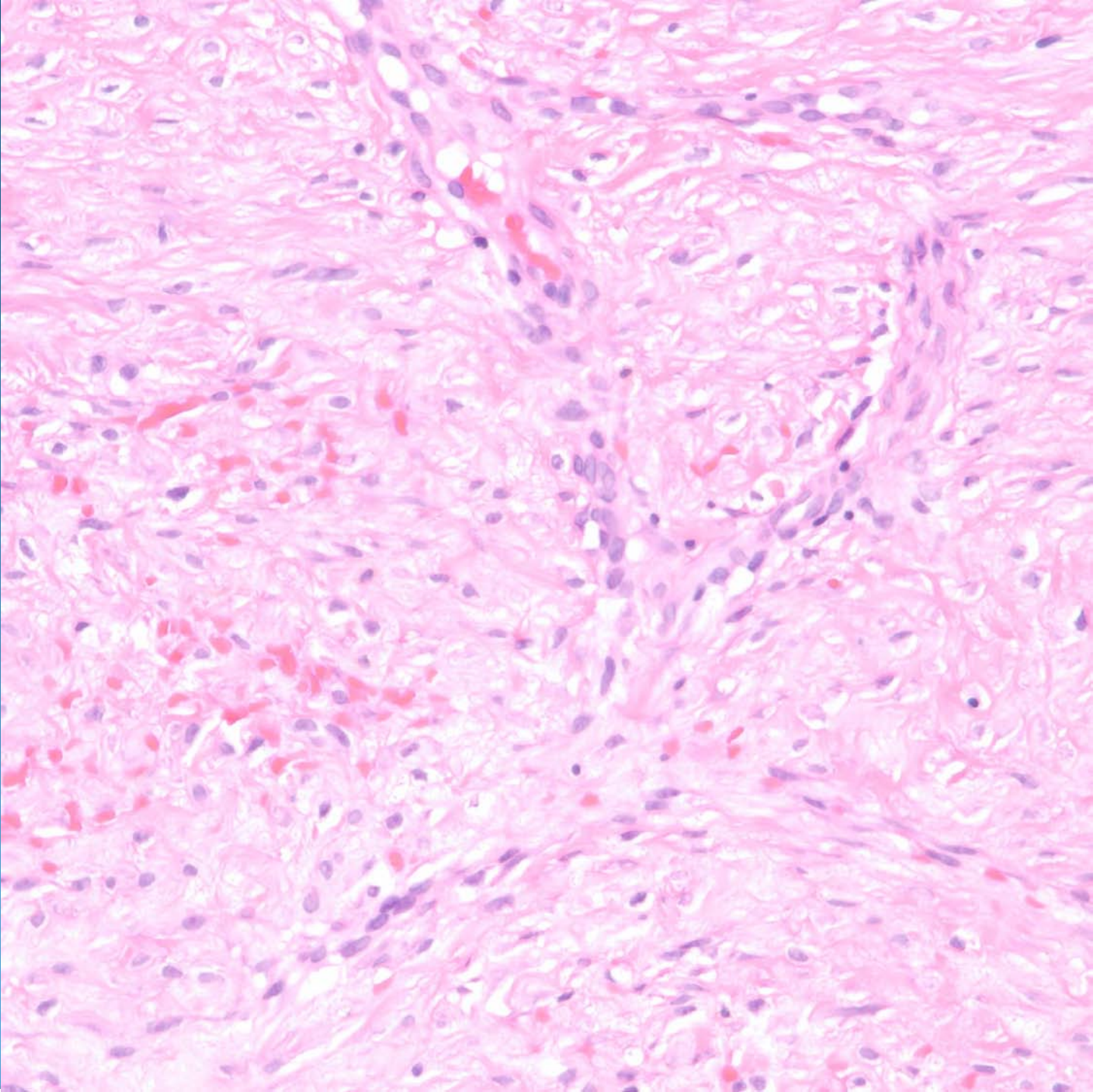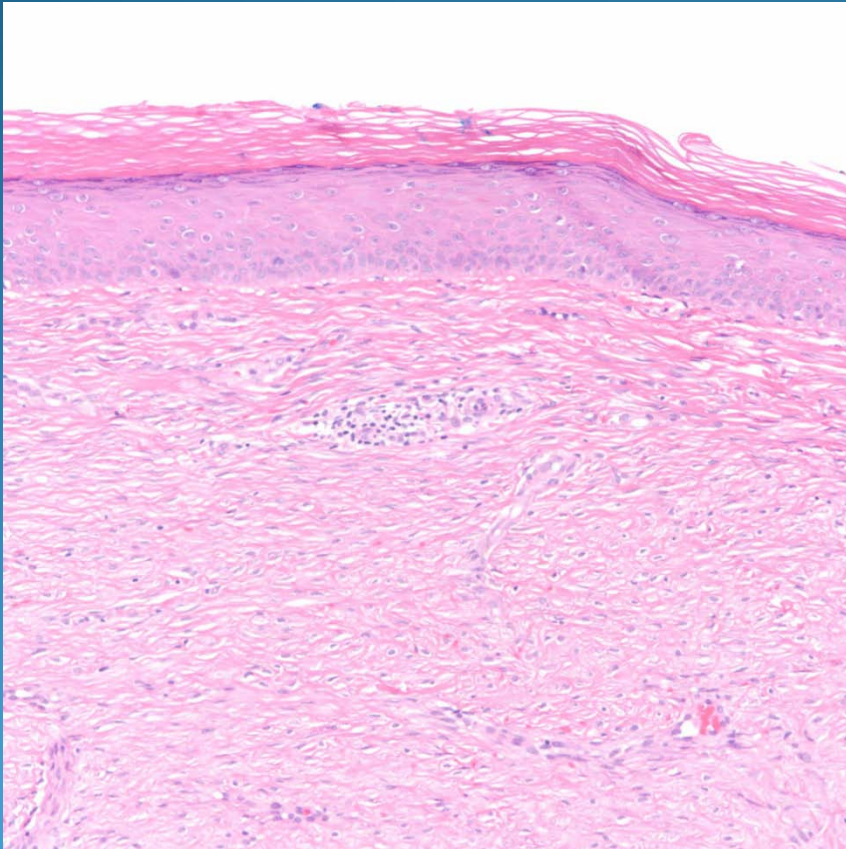


Hypertrophic Scar

Pearls



- Rete ridges usually effaced
- Diffuse dermal fibrosis with blood vessels arranged in perpendicular orientation with respect to horizontal axis of epidermis
- May have dermal hemorrhage