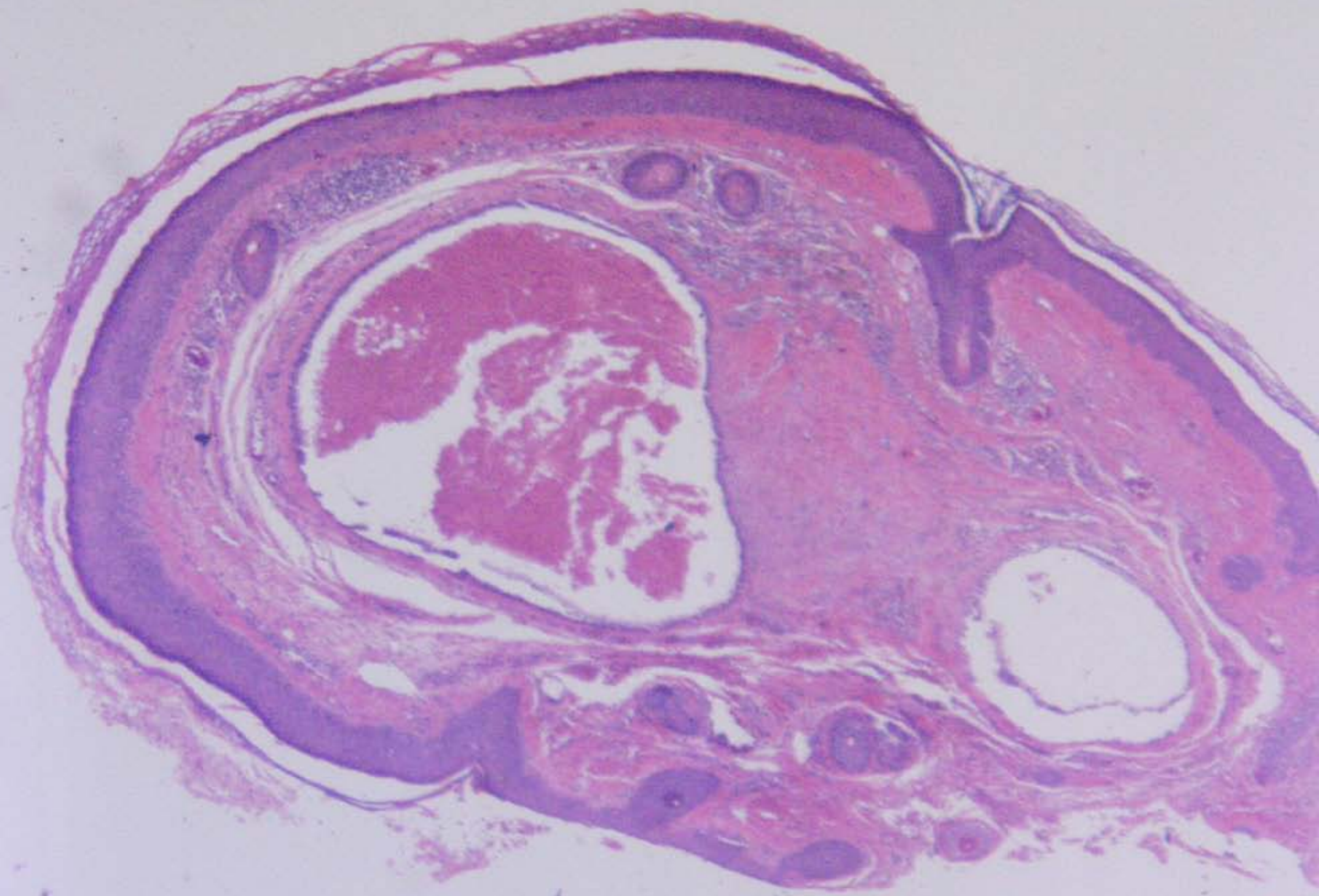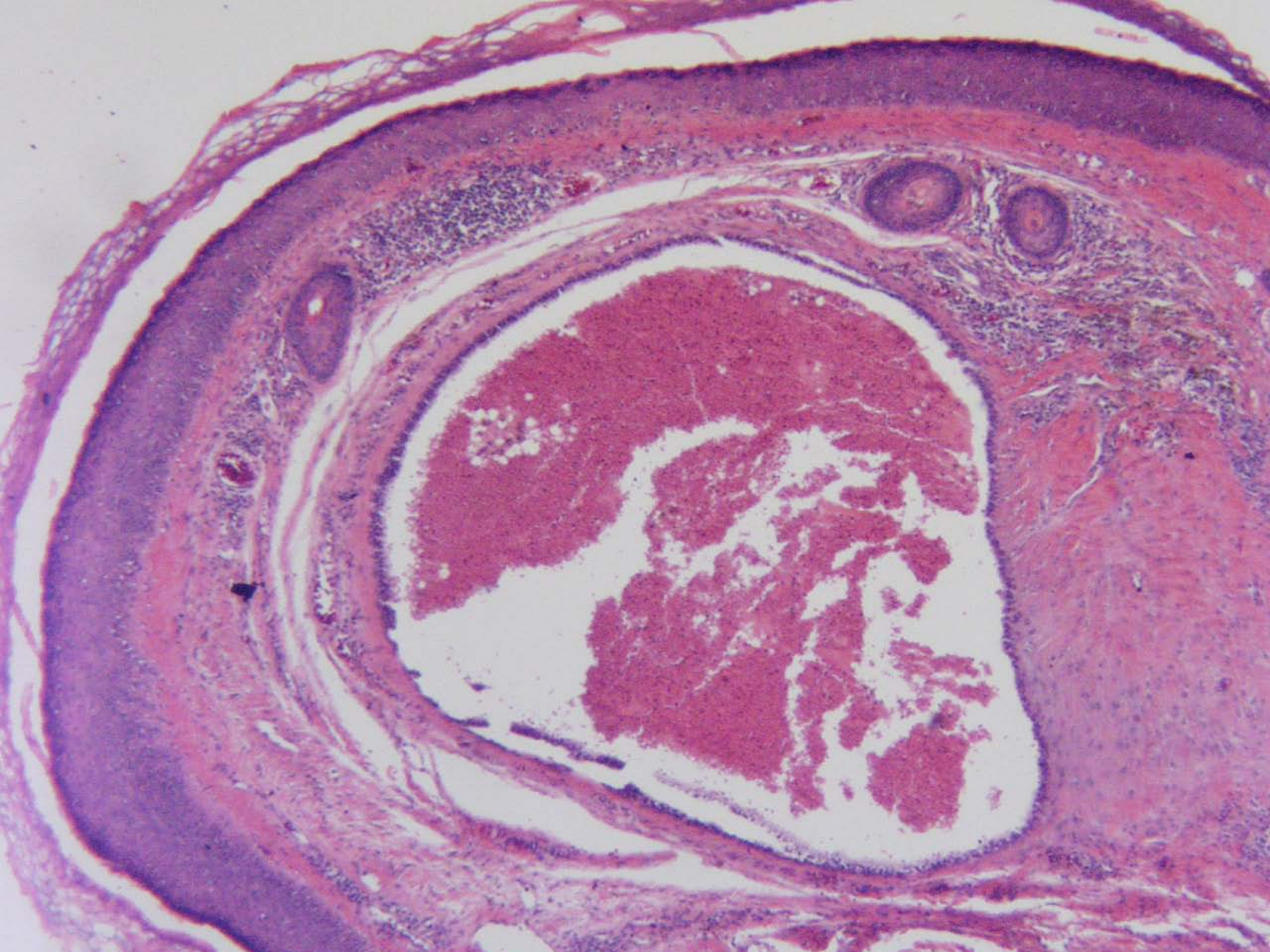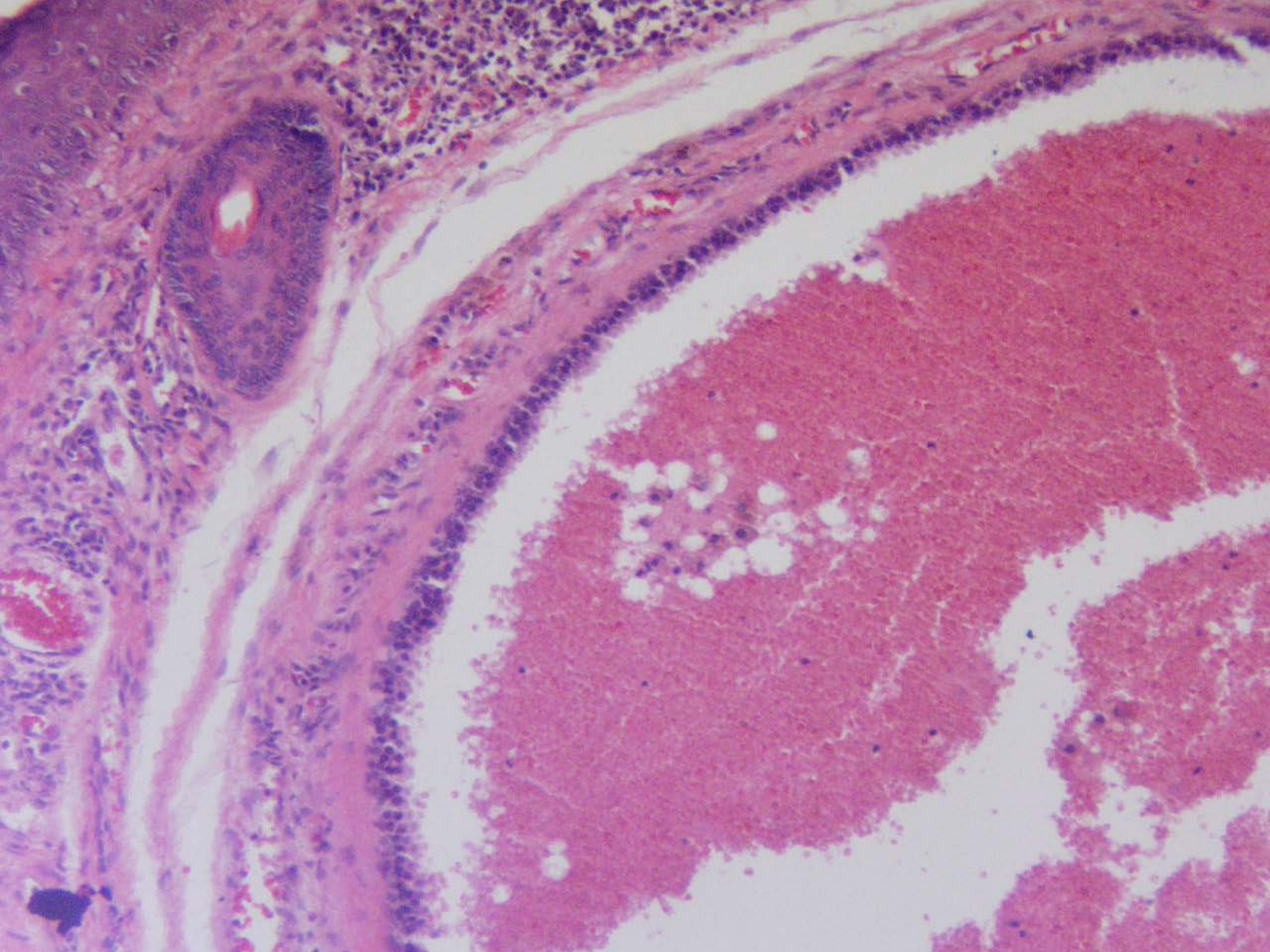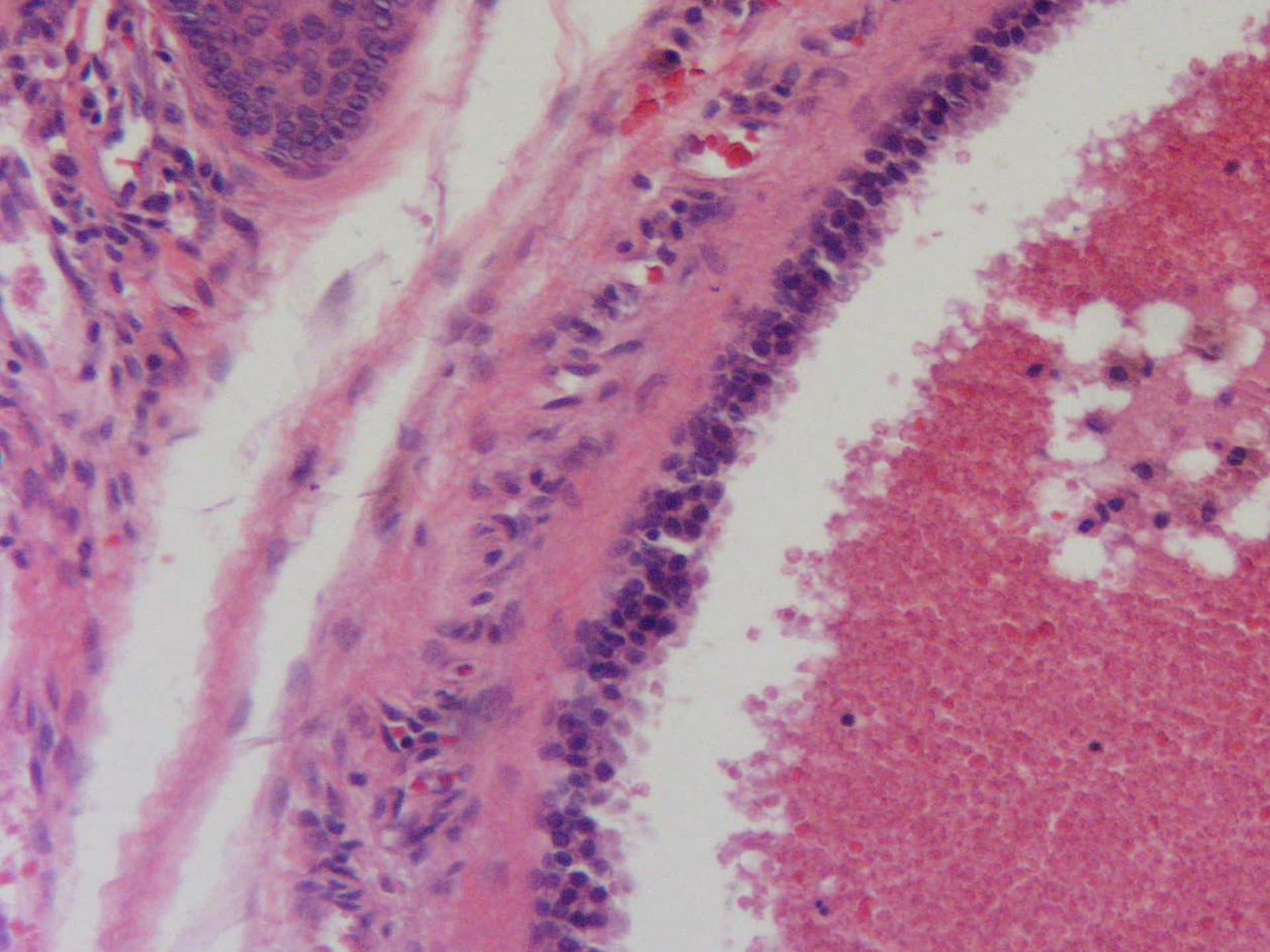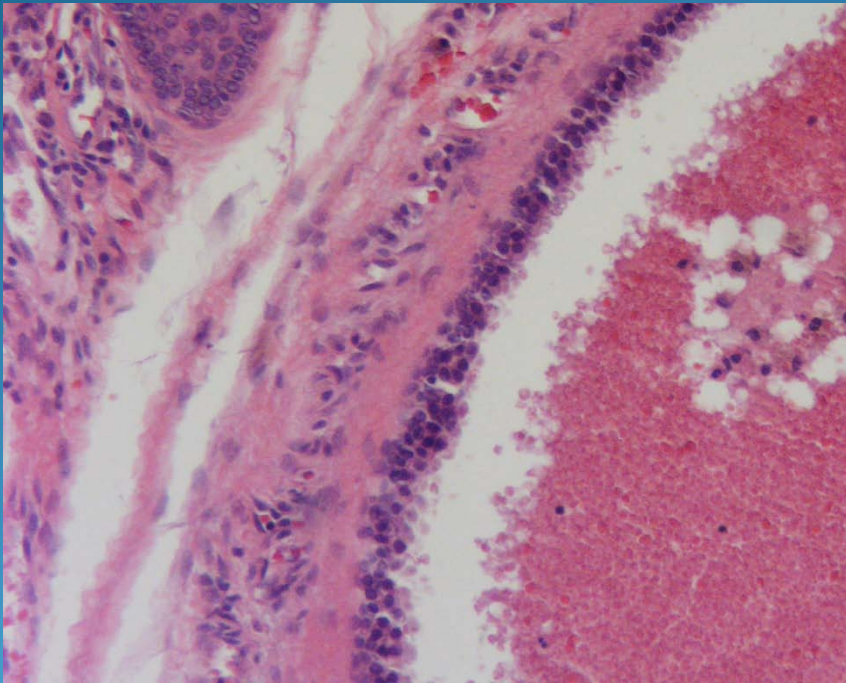


Hidrocystoma, Apocrine

Pearls



- Dermal cyst lined by apocrine epithelium
- Look for apocrine snouting