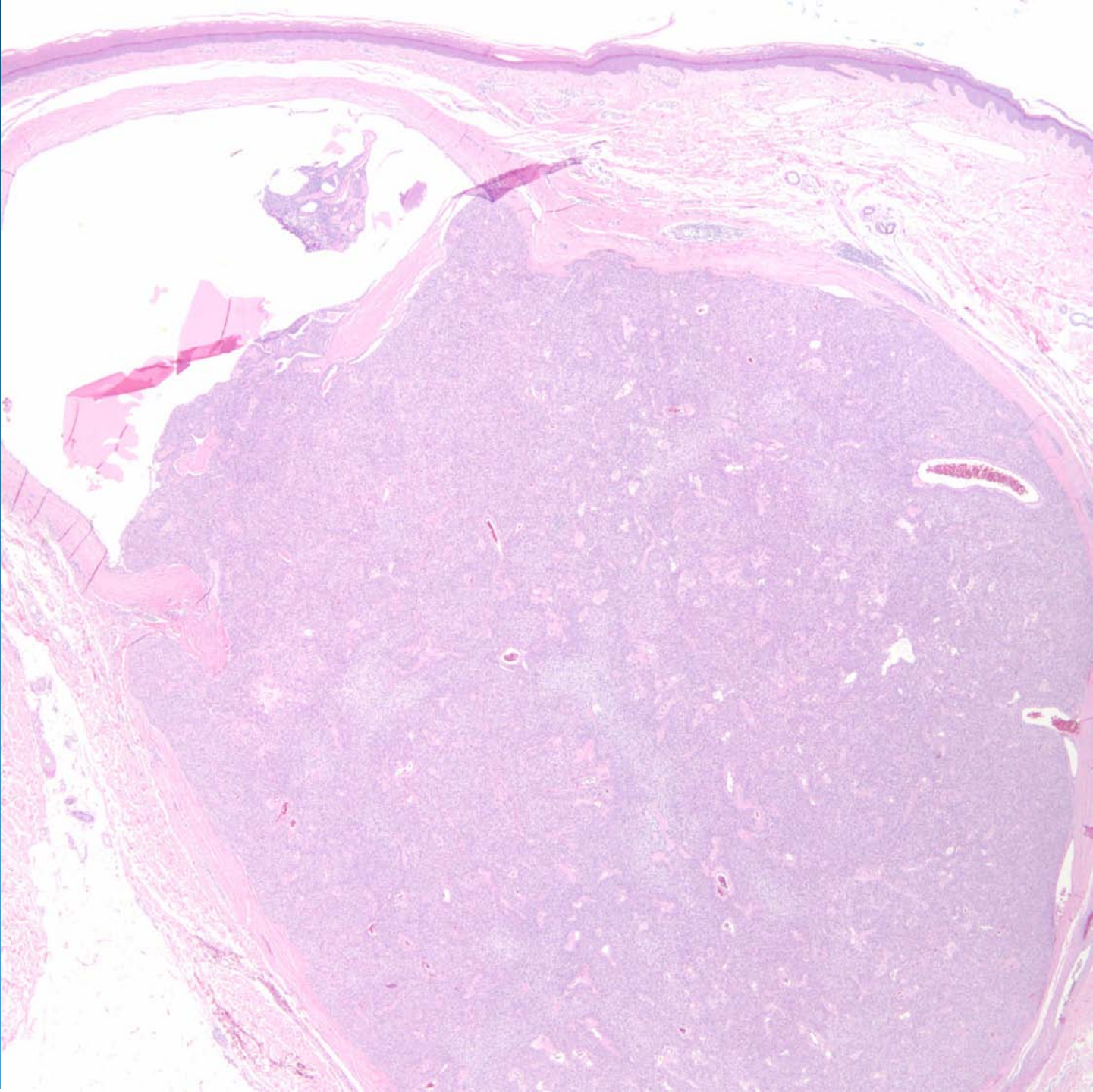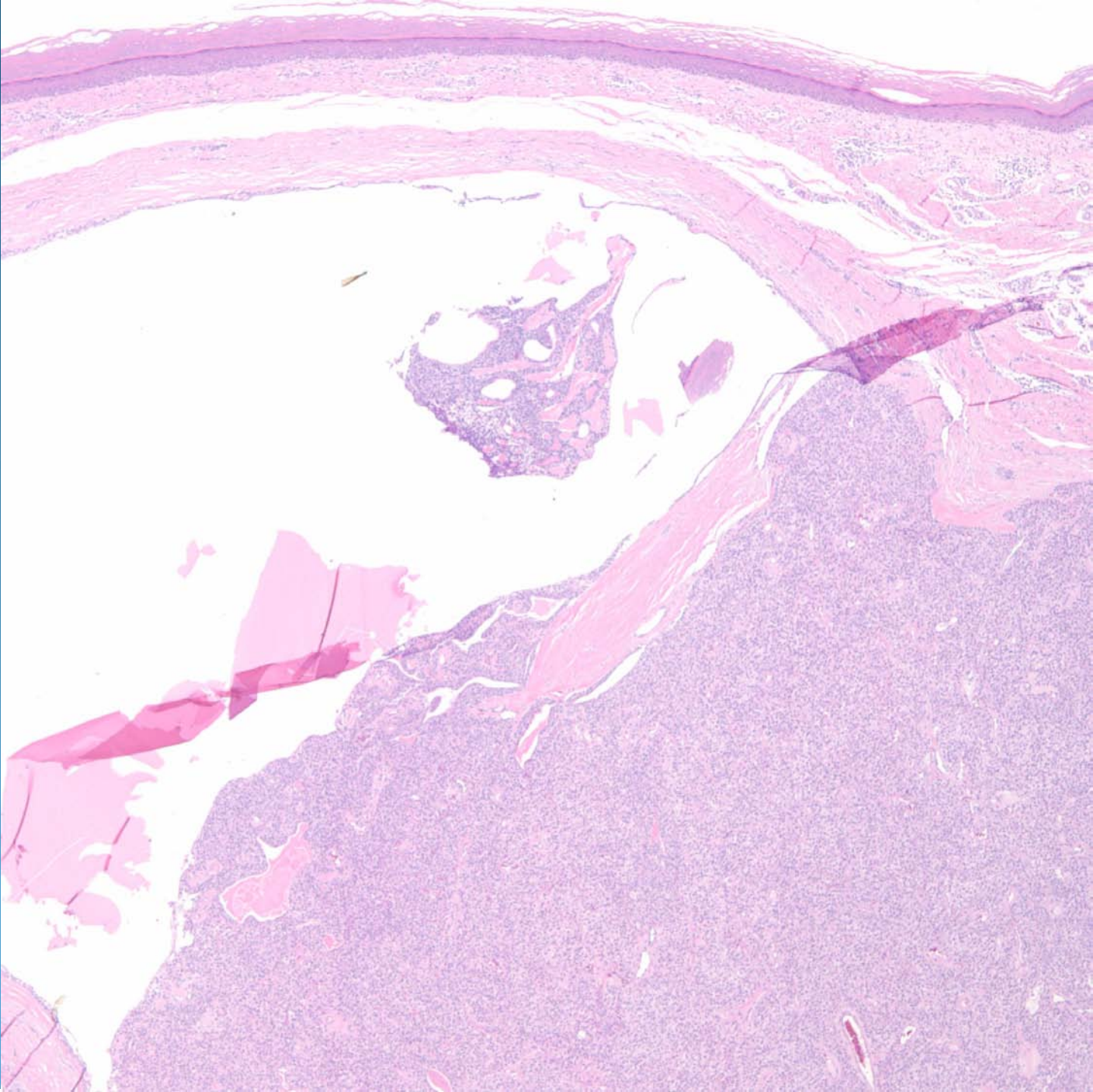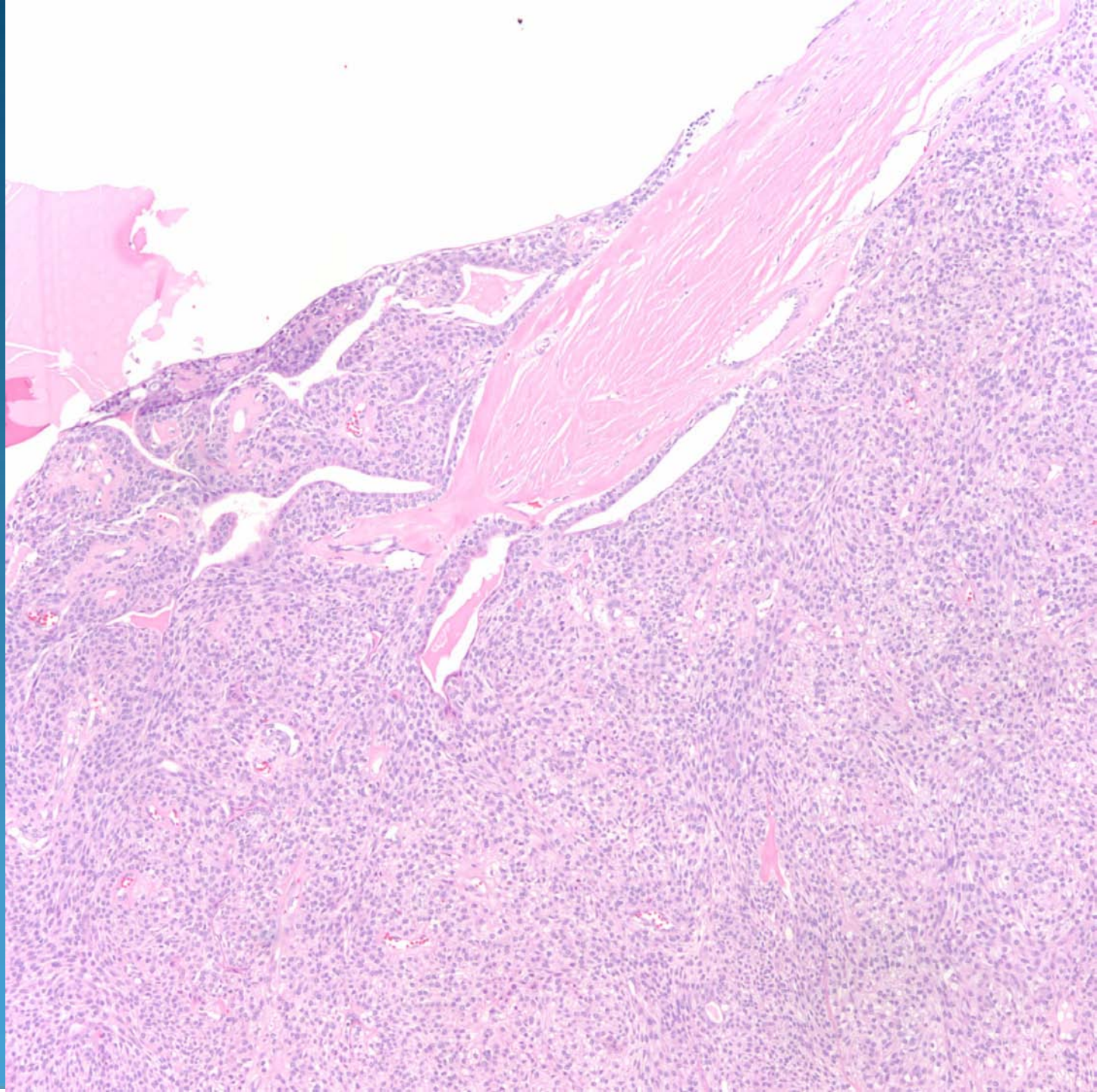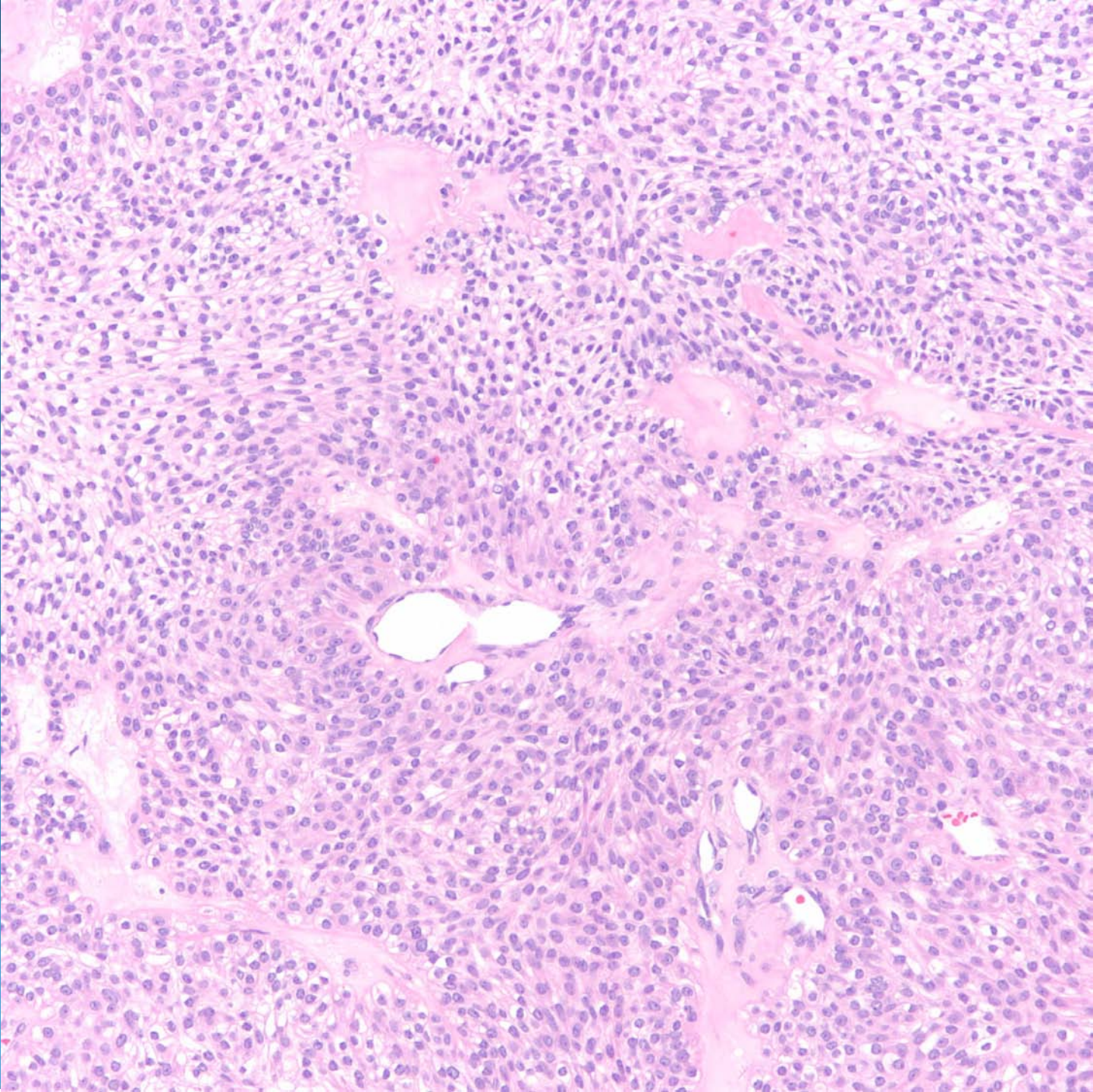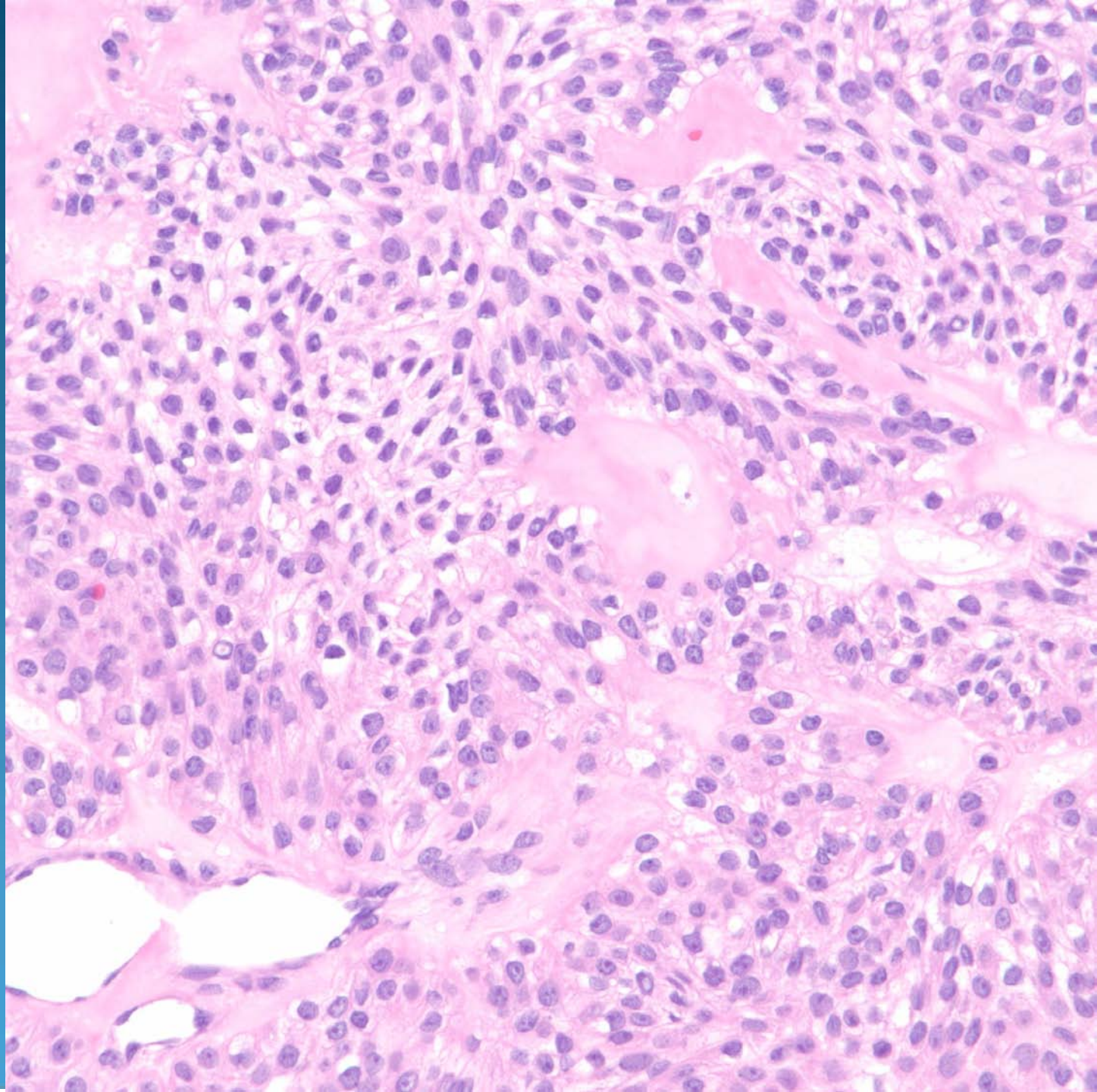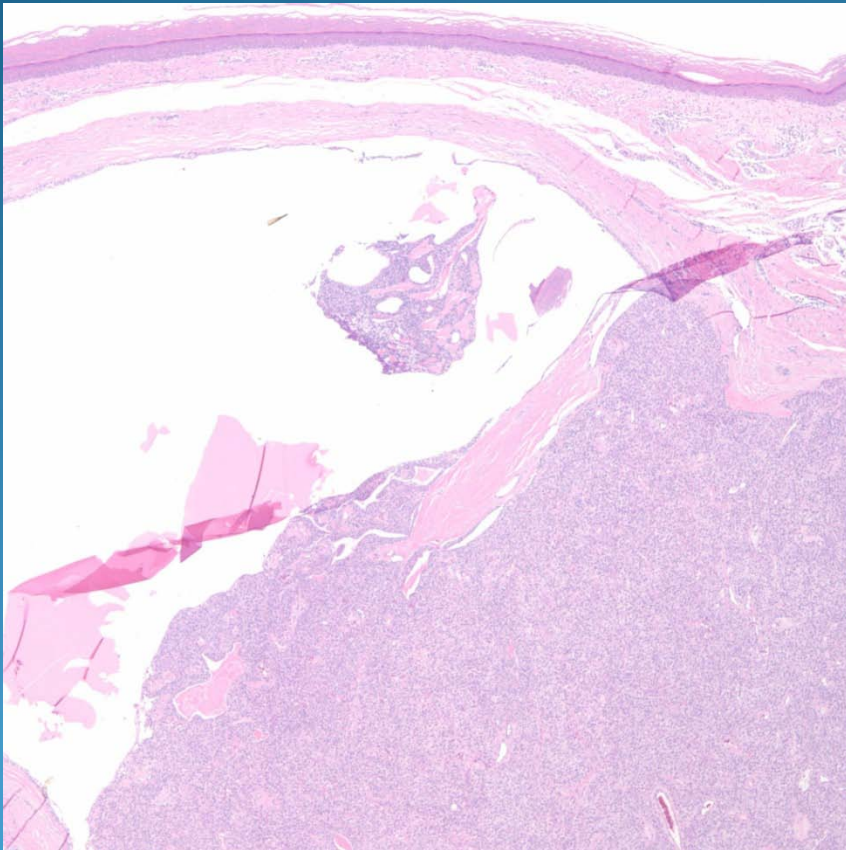


Nodular and Cystic Hidradenoma

Pearls



- Circumscribed dermal nodule with varying solid and cystic change
- Squamous epithelial cells with clear cell changes admixed with small vessels
- Hyalinization around vessels