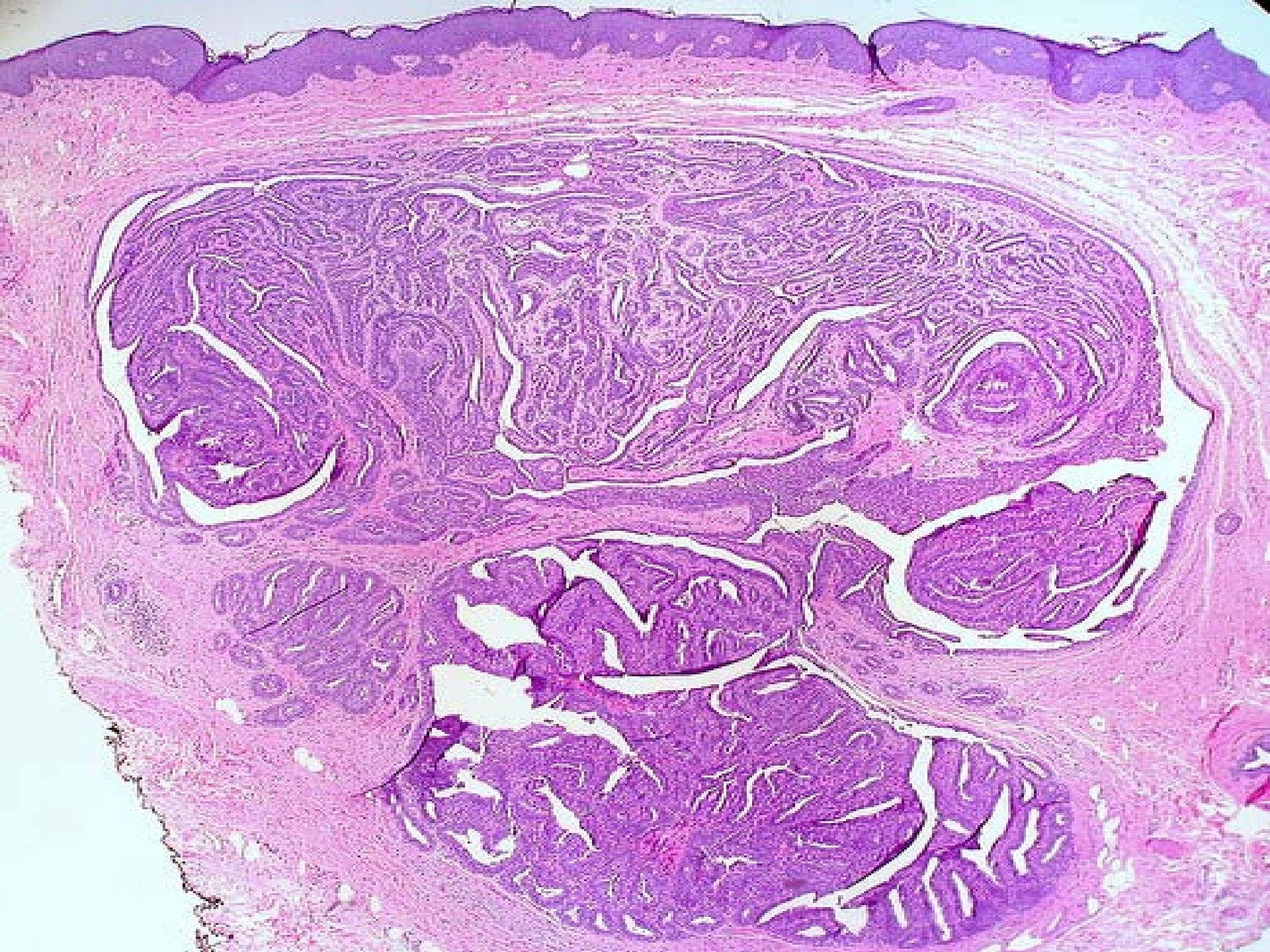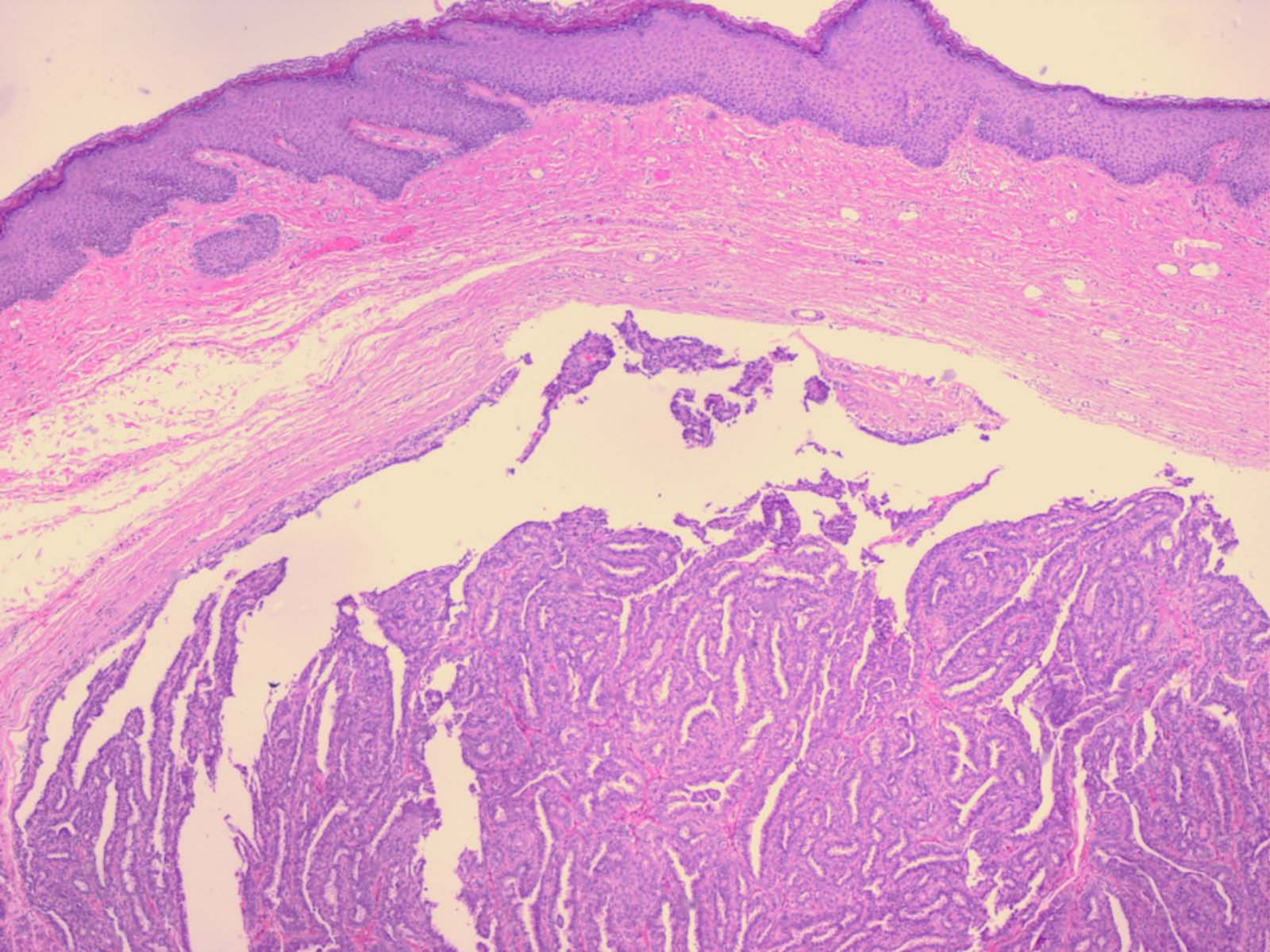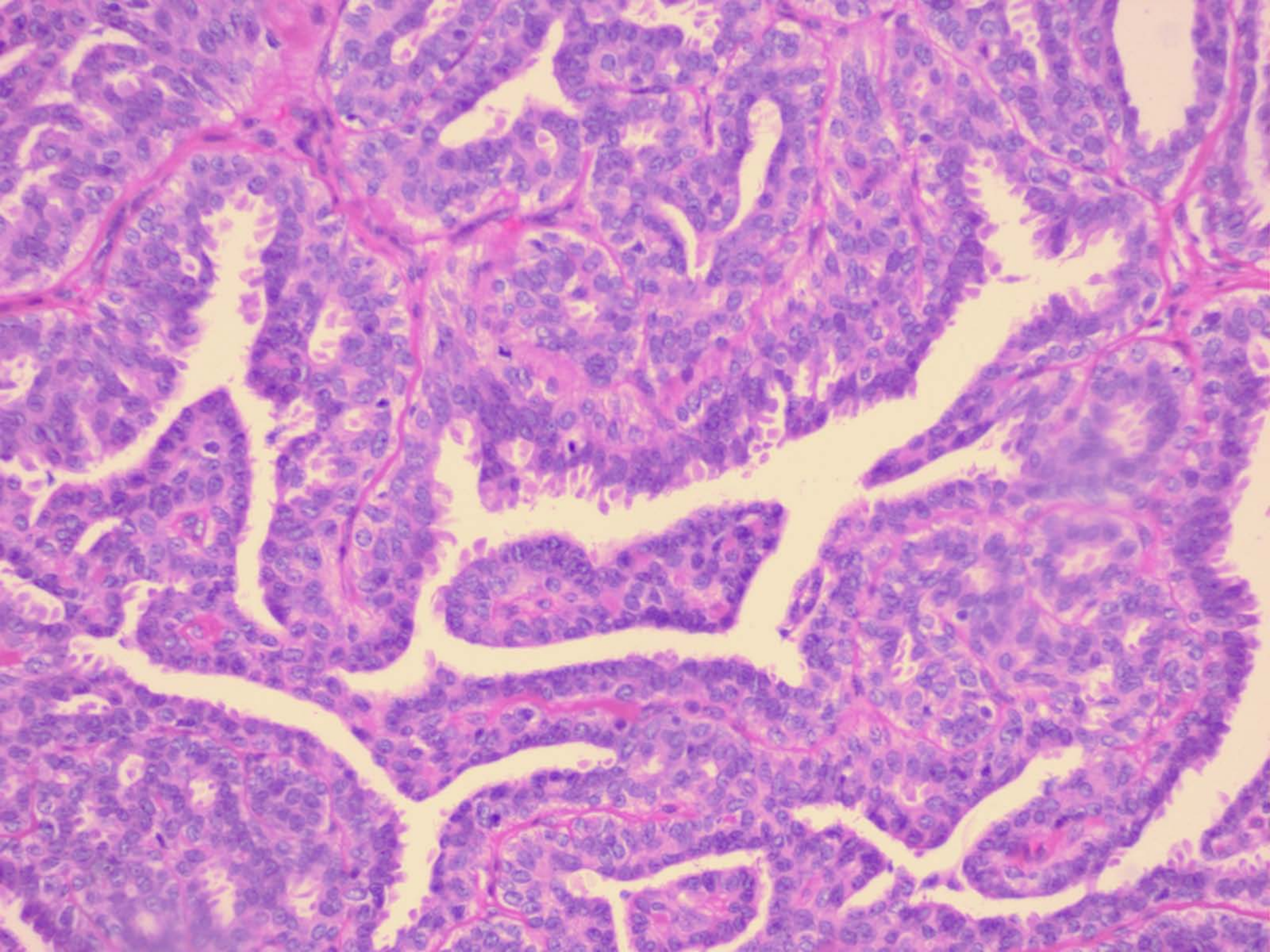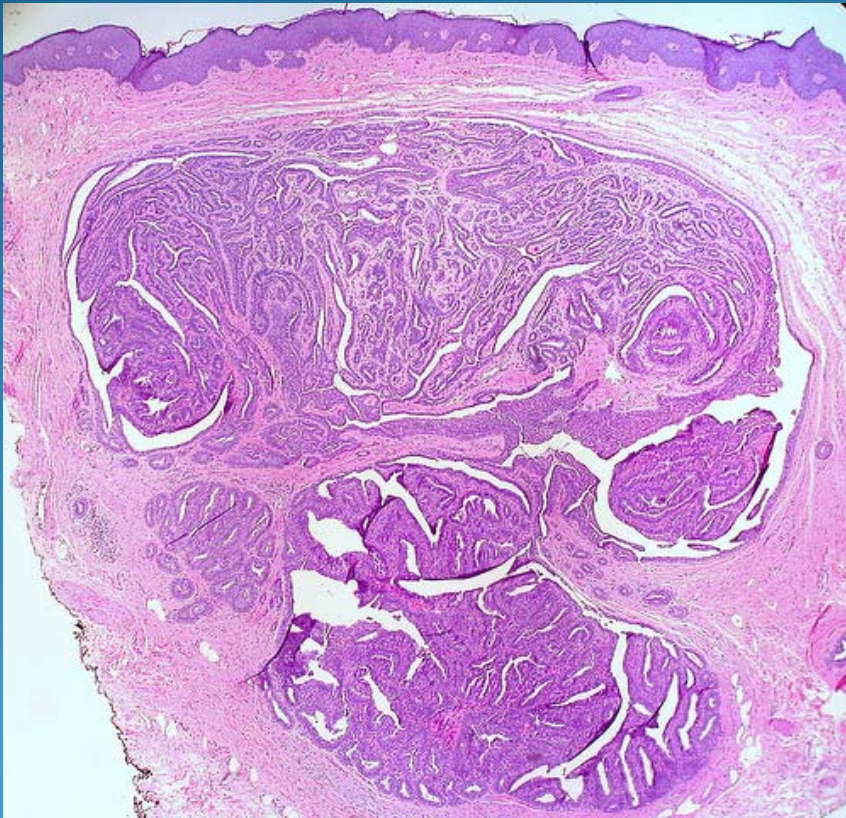


Hidradenoma Papilliferum

Pearls



- Dermal nodule
- Multiple cysts and papillary projections
- Lined by apocrine cells