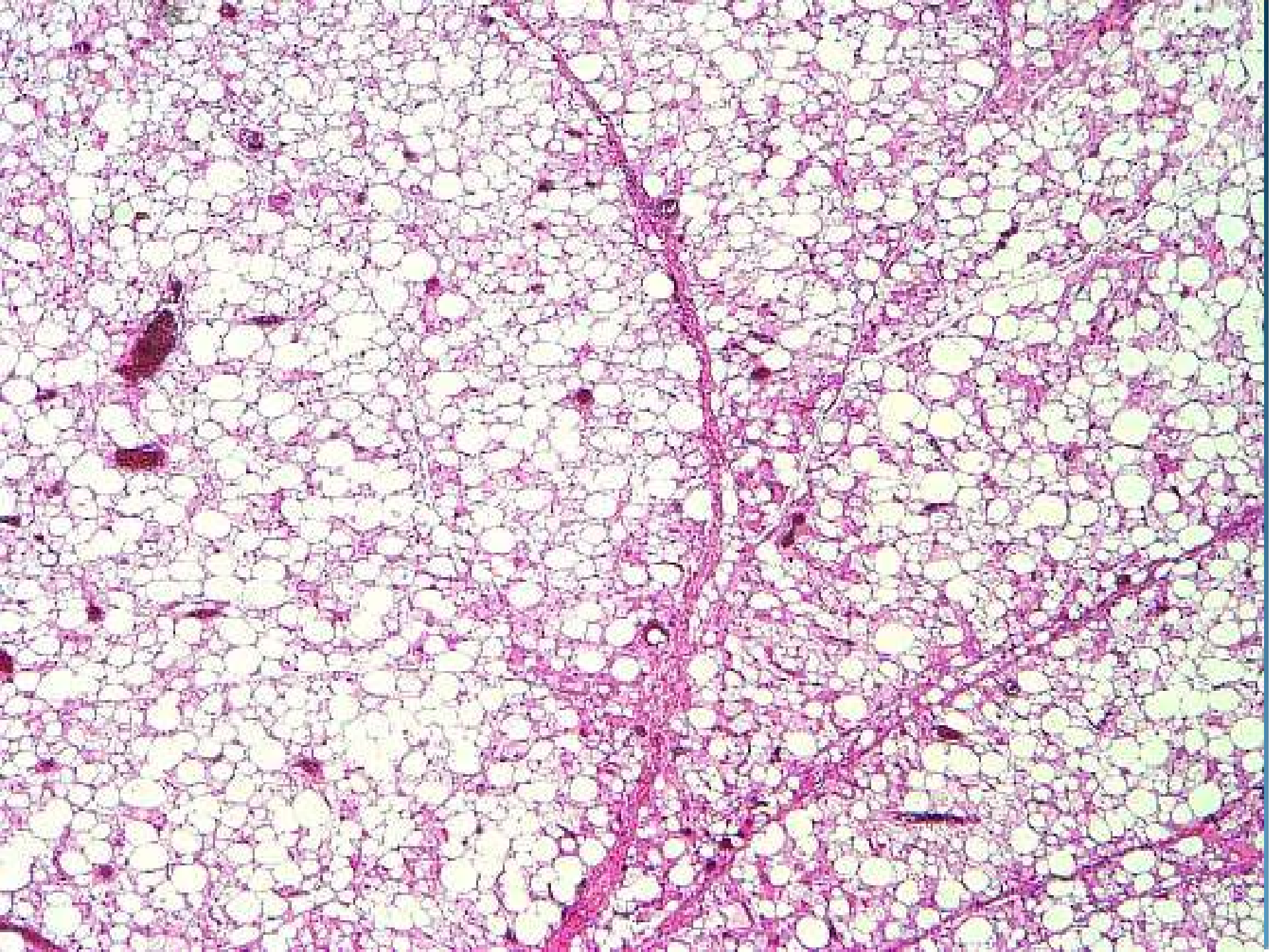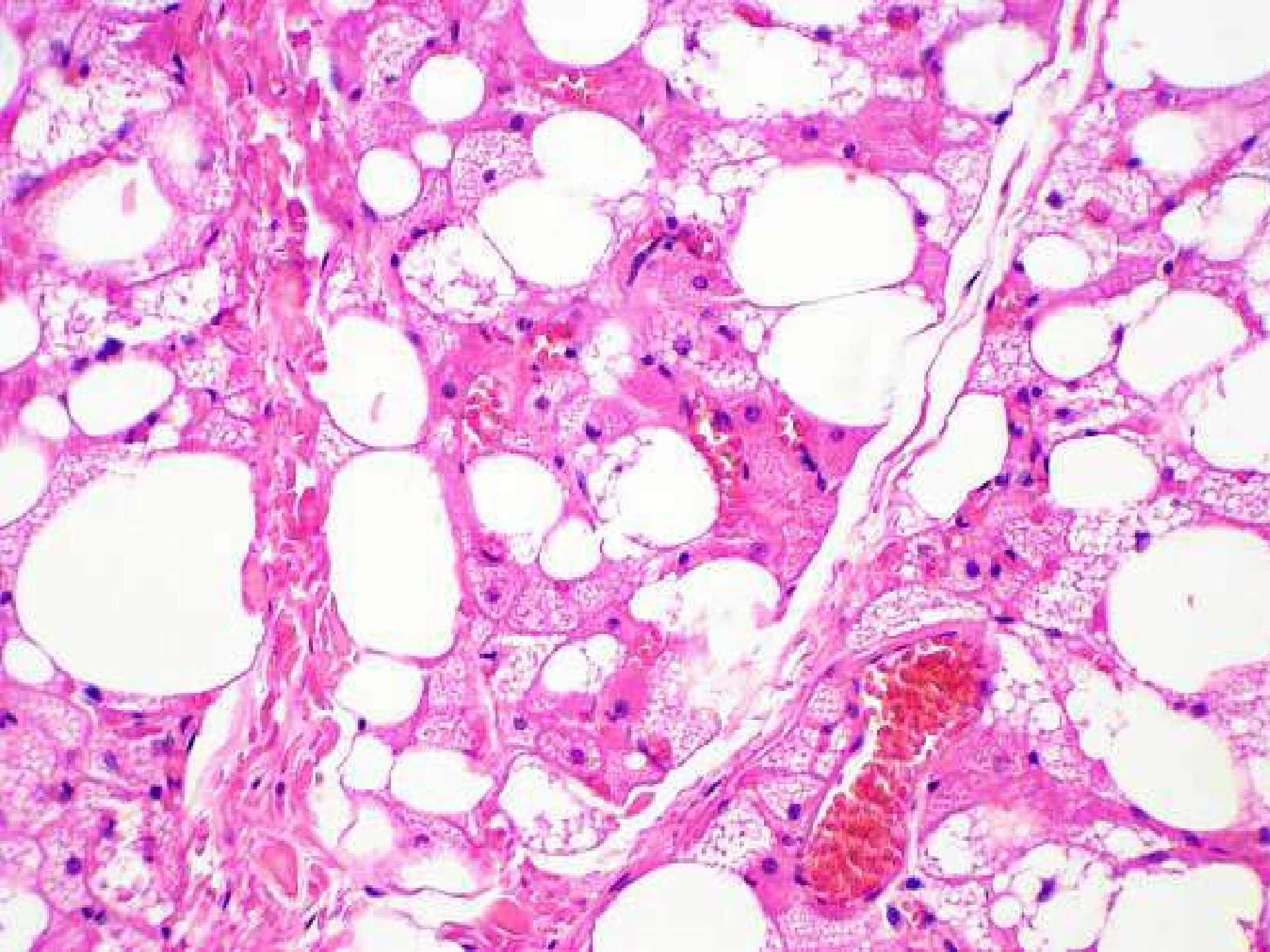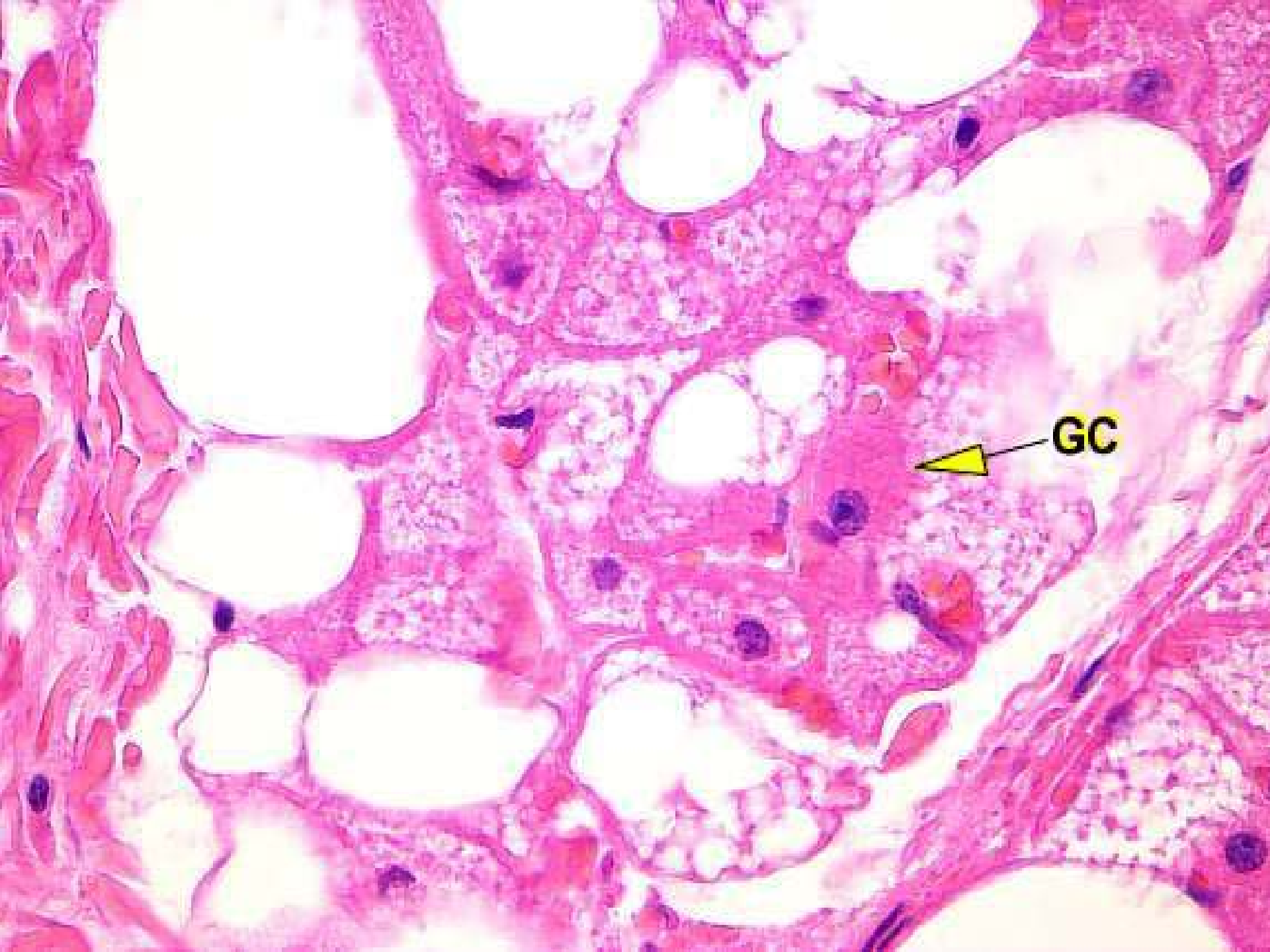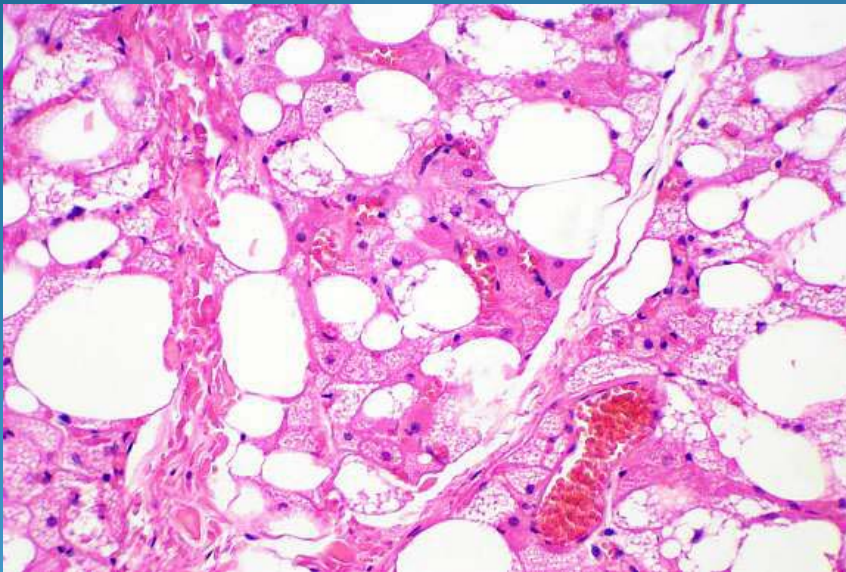




GC

Hibernoma

Pearls



- Fatty tumor with eosinophilic granular cells
- Resembles ping-pong balls
- Rule out granular tumor which is usually not deep