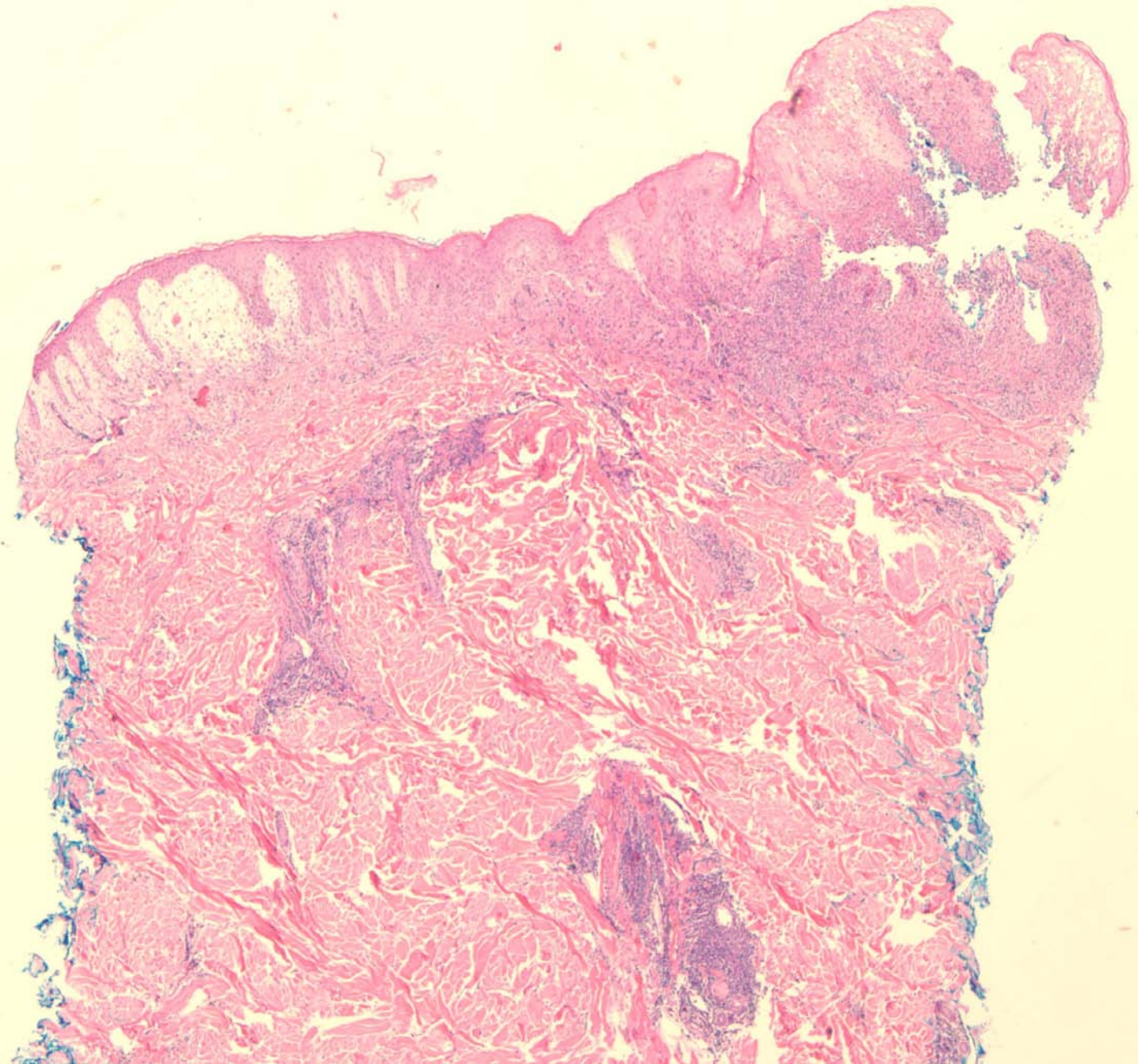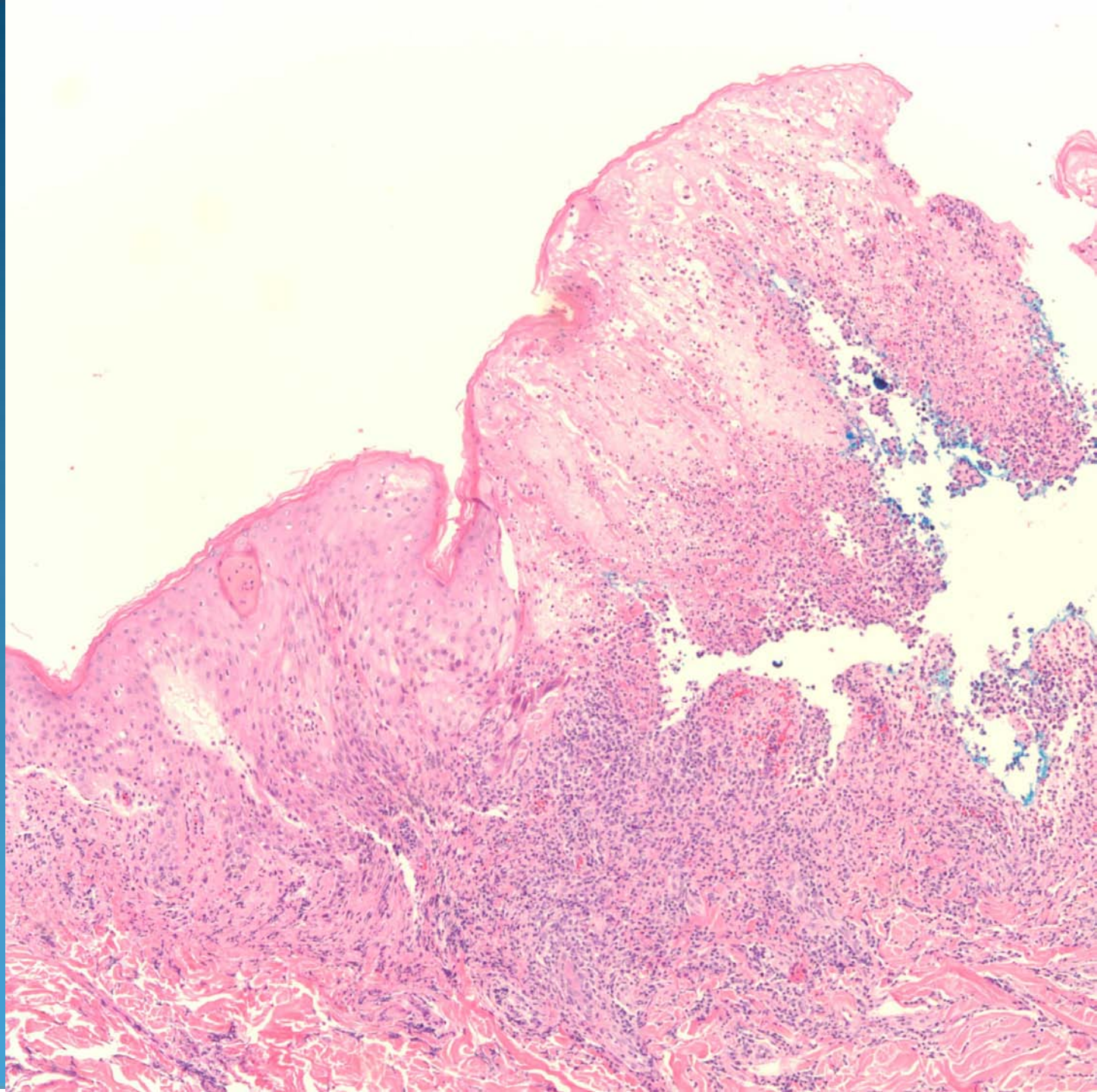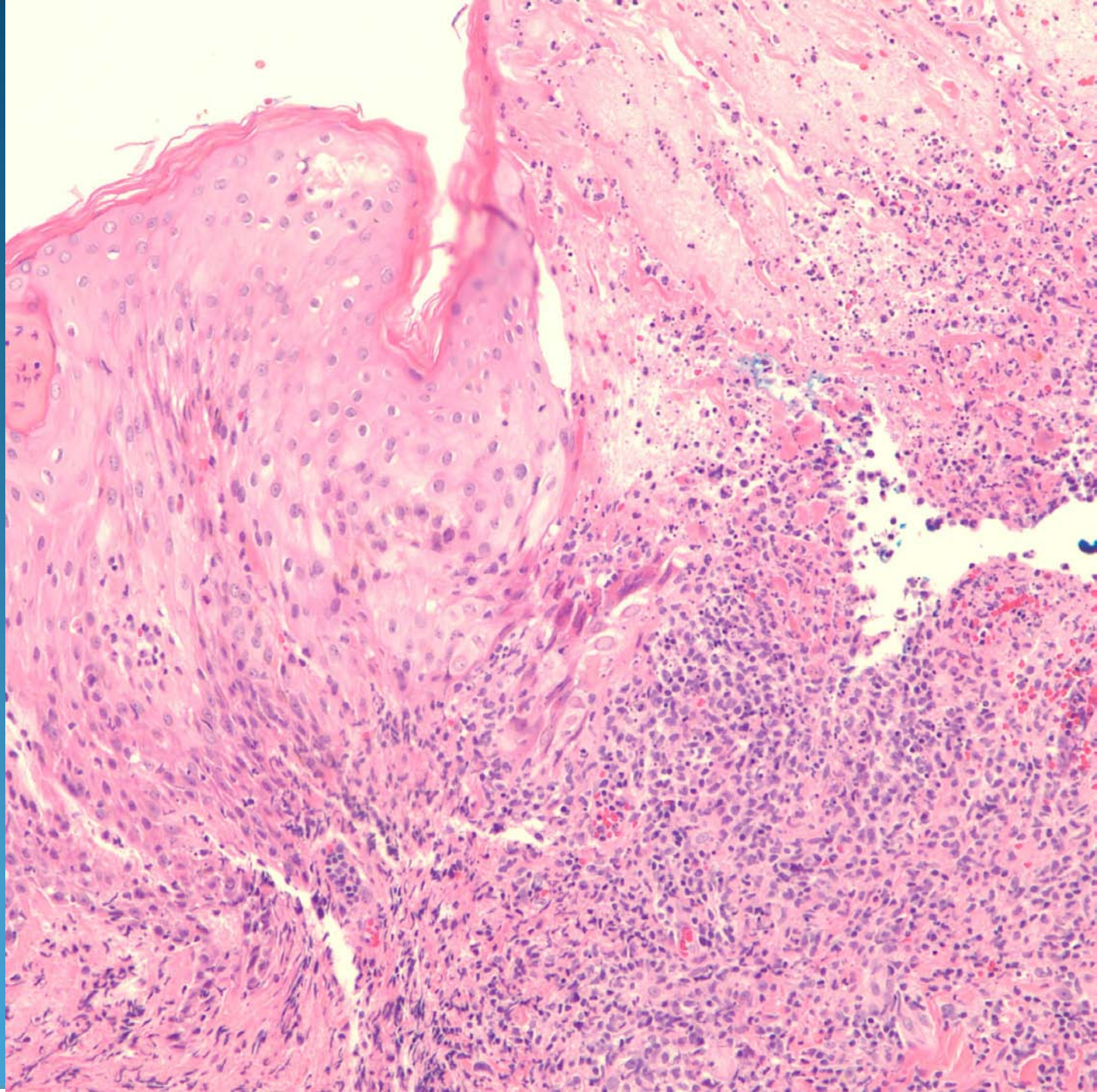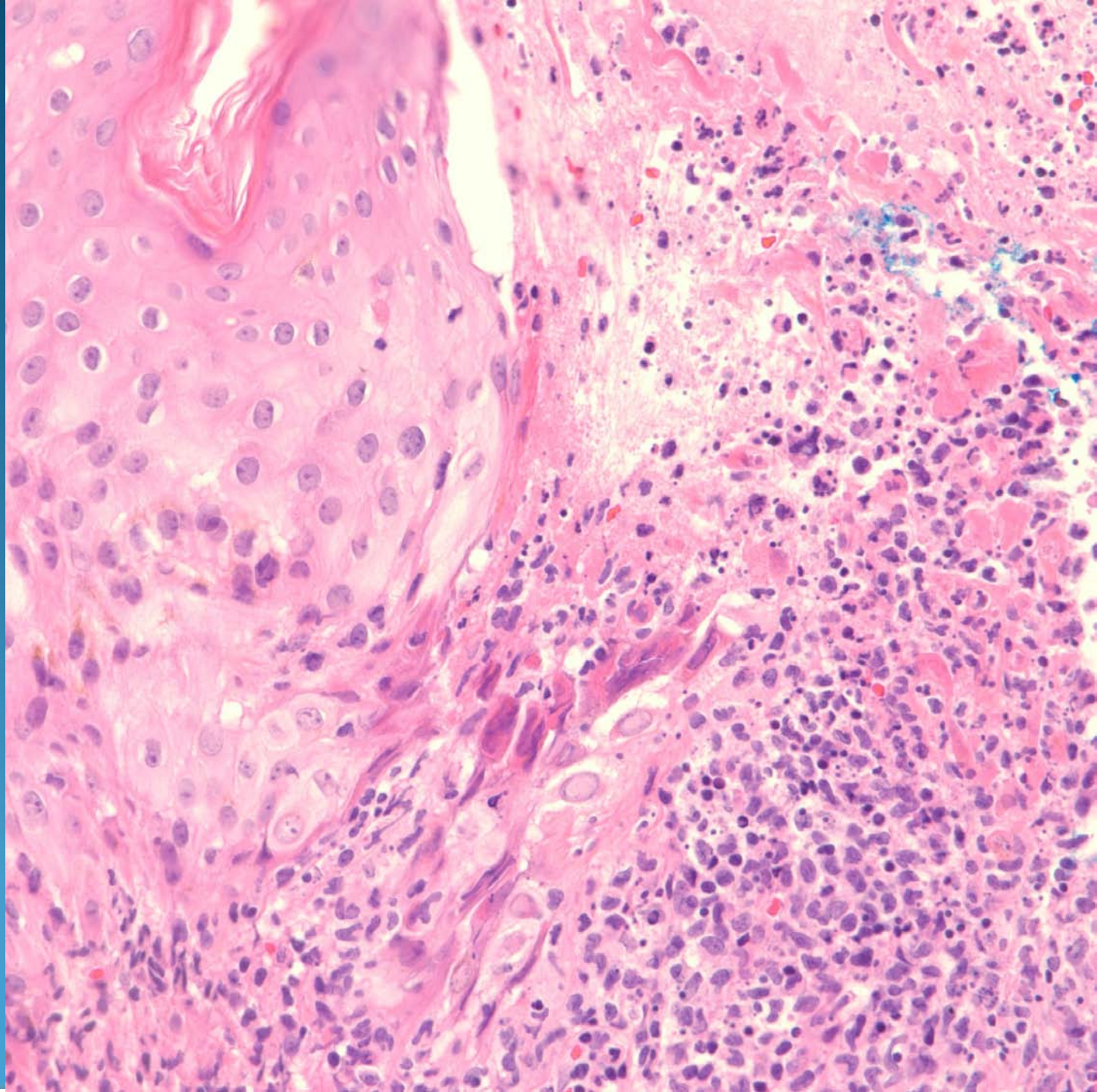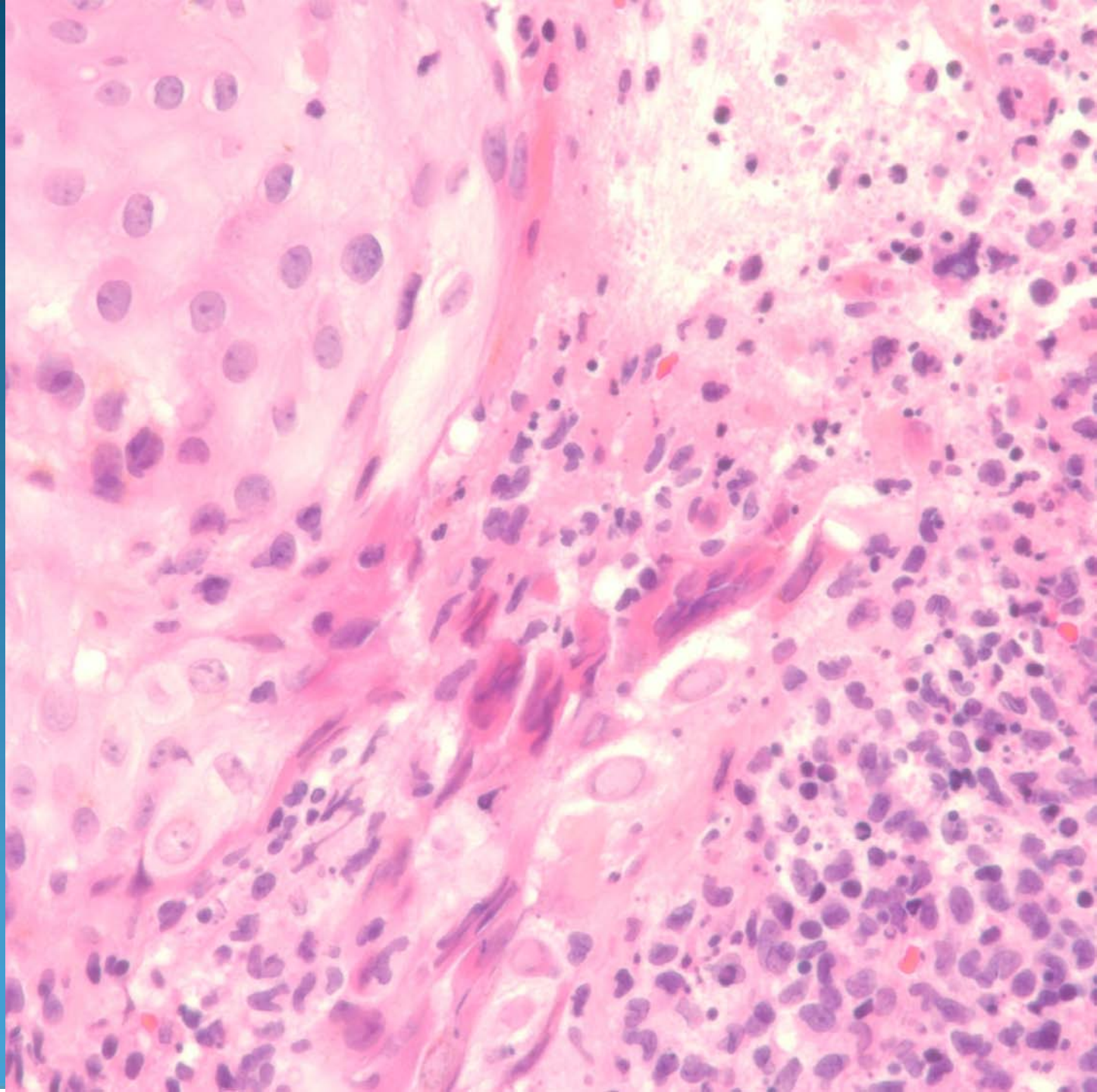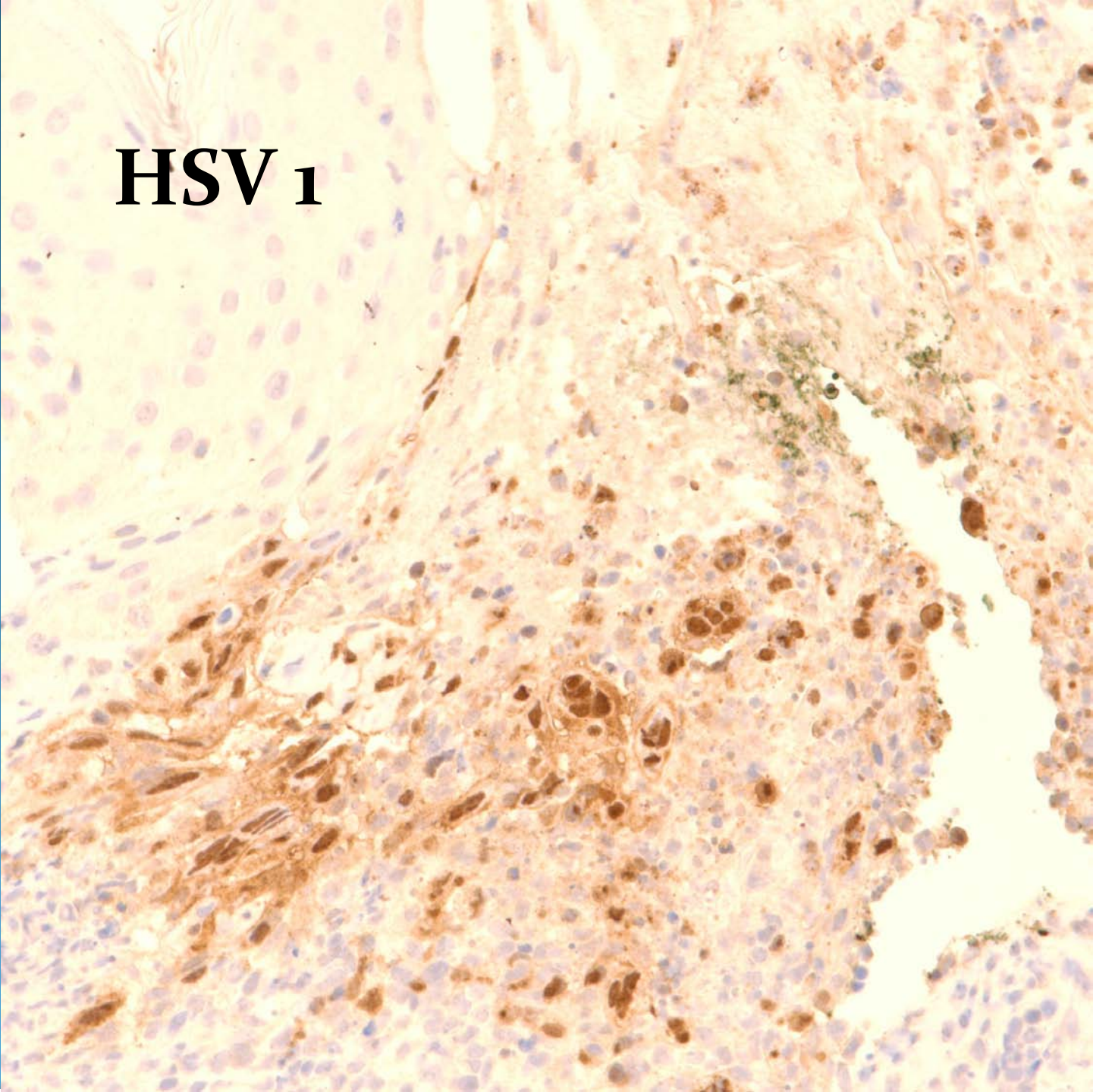
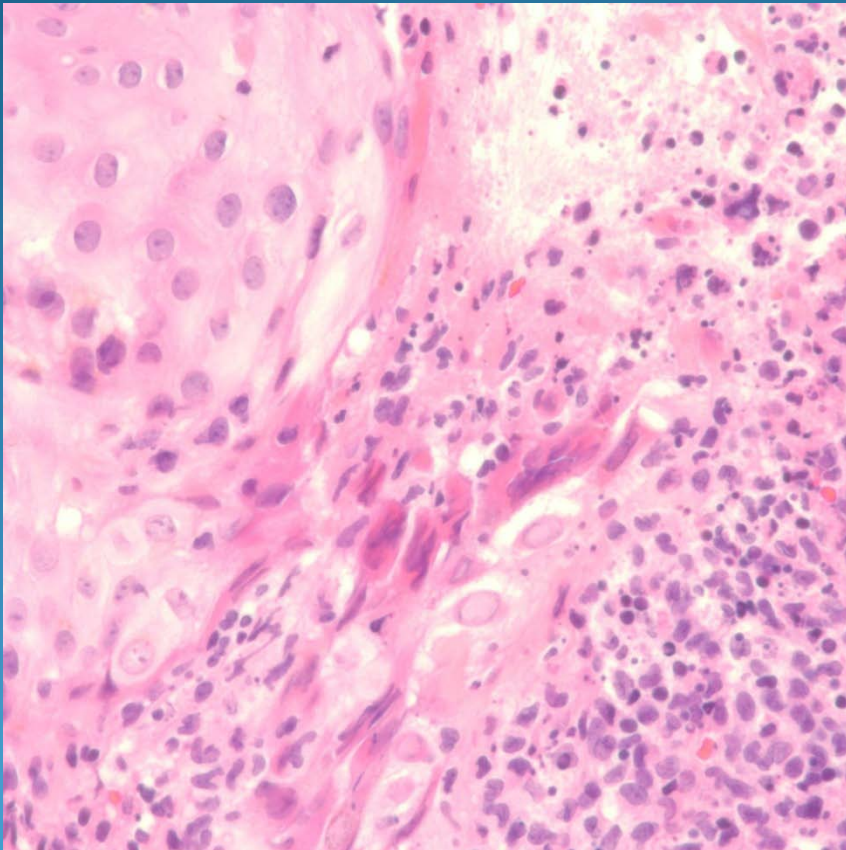


HSV 1



Herpes Simplex Virus Infection

Pearls



- Ulcer with acantholytic cells showing multinucleation and nuclear chromatin margination
- Look in base and edge of ulcer
- May confirm with Ab to HSV₁/HSV₂