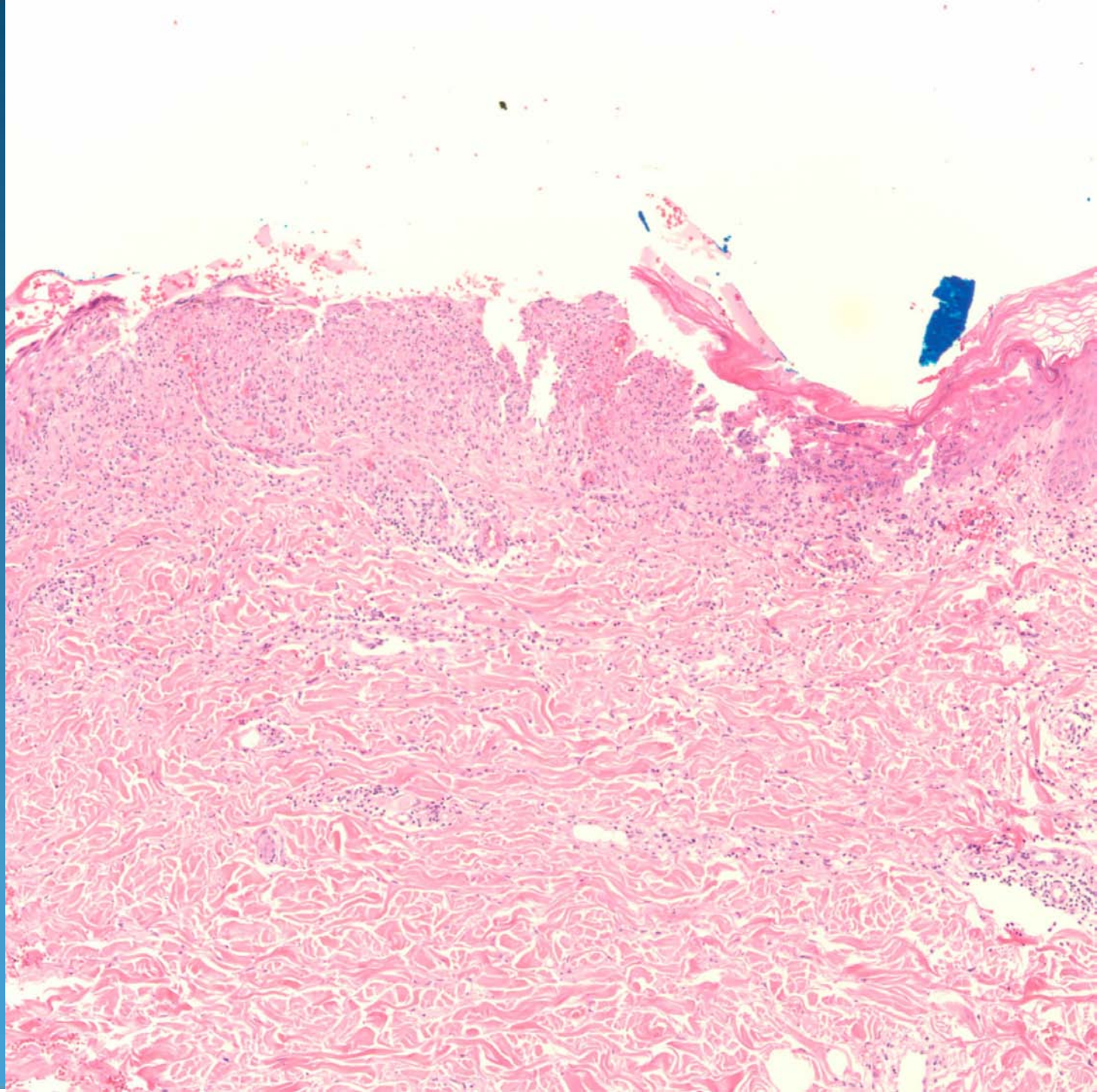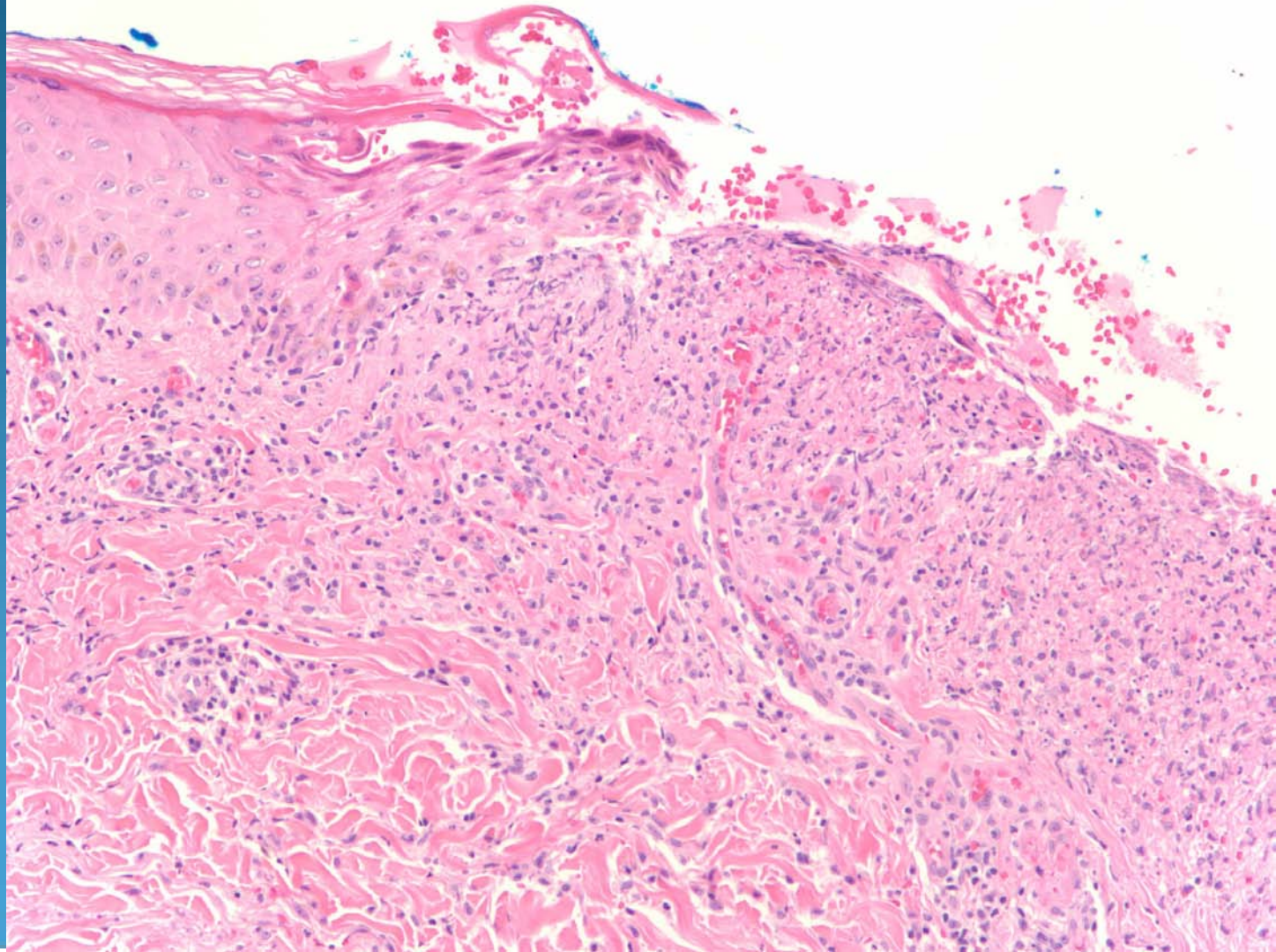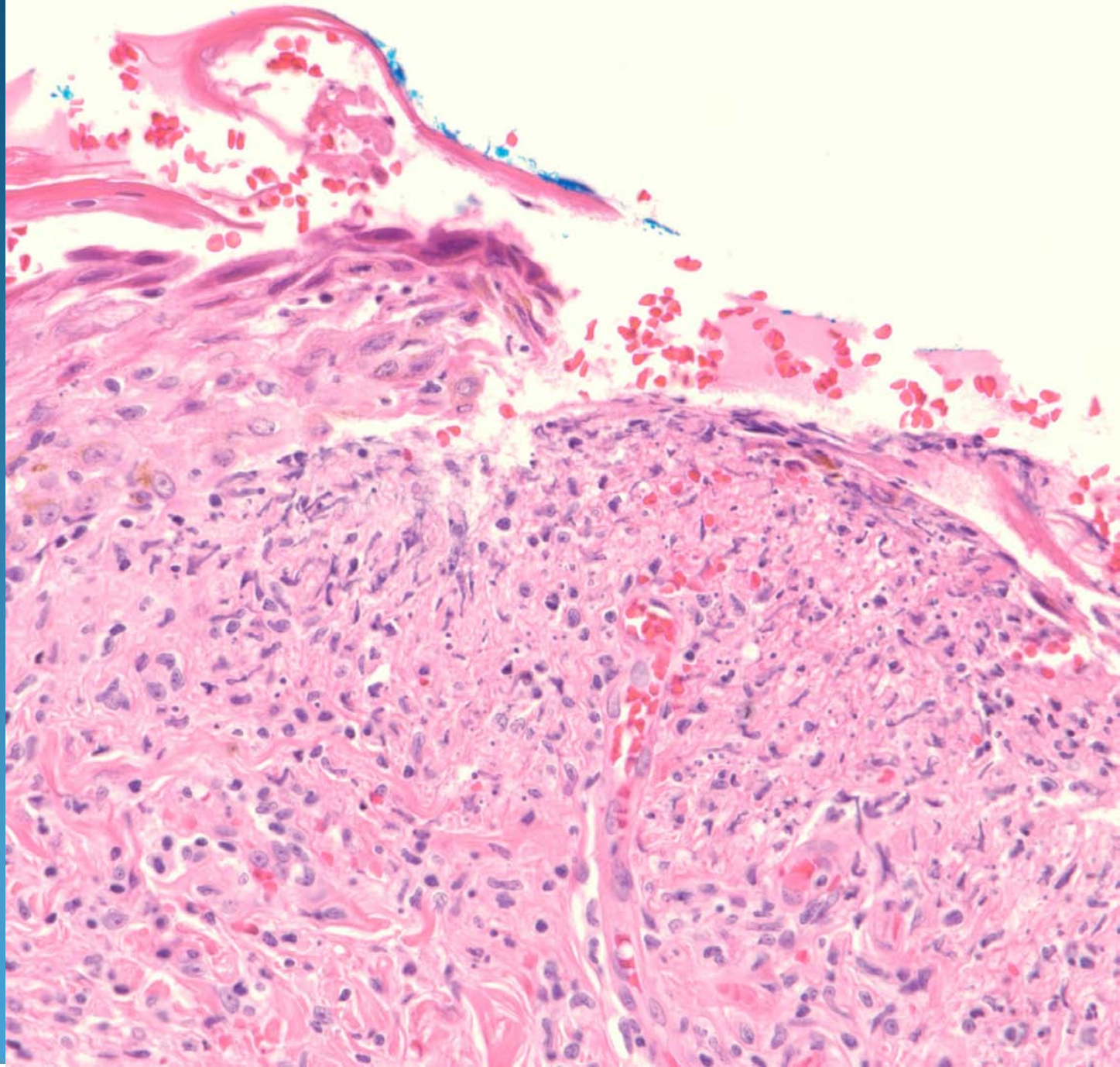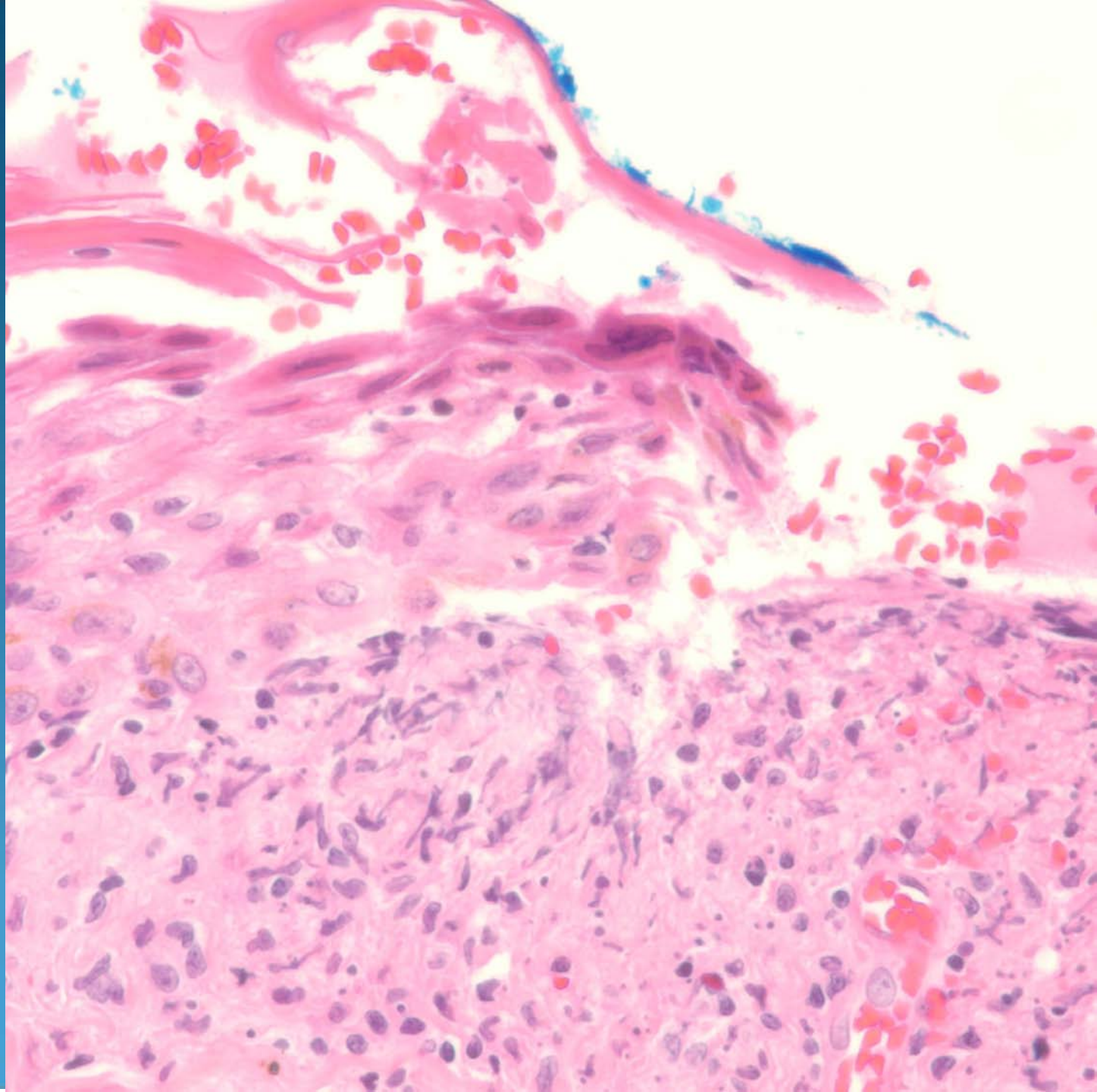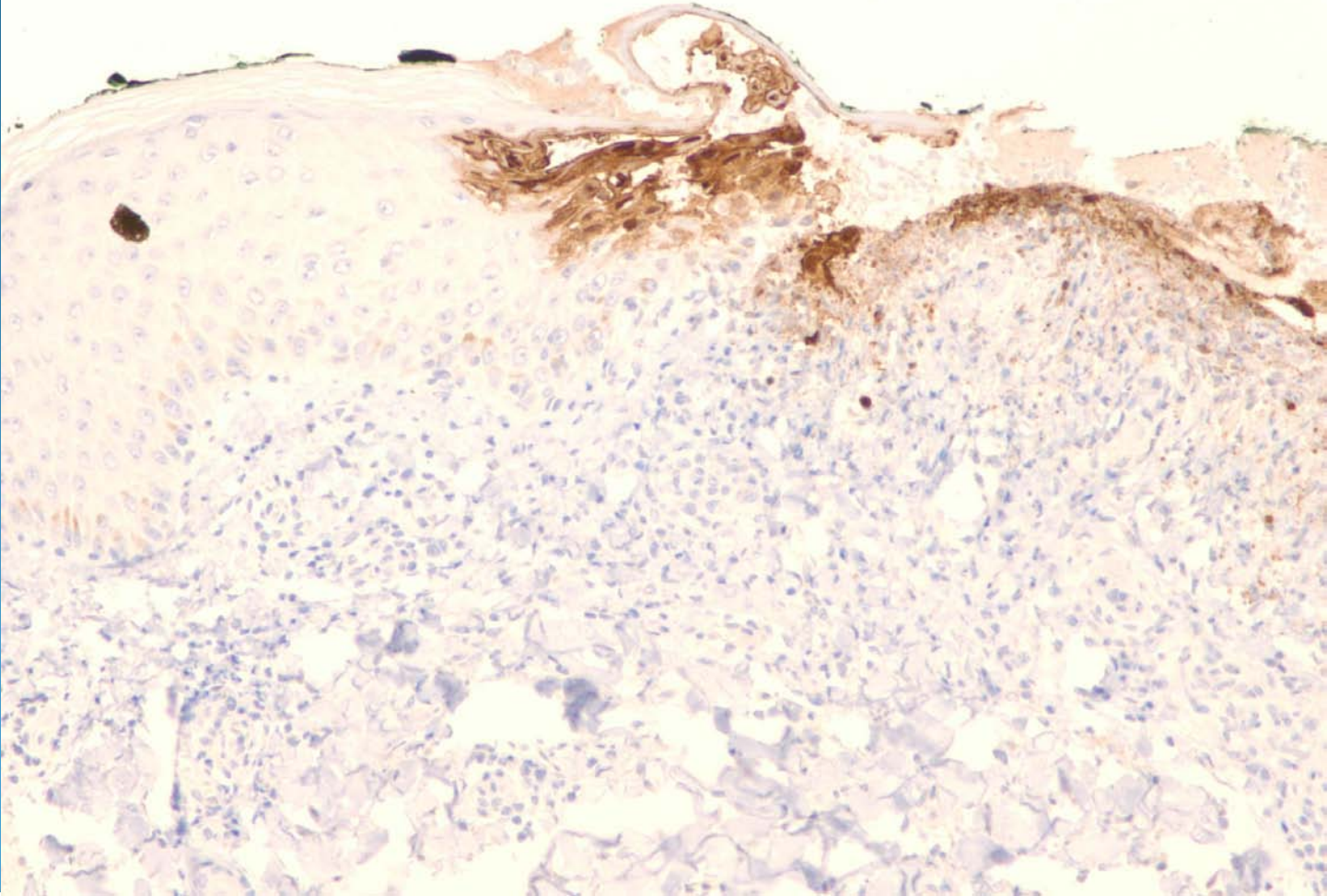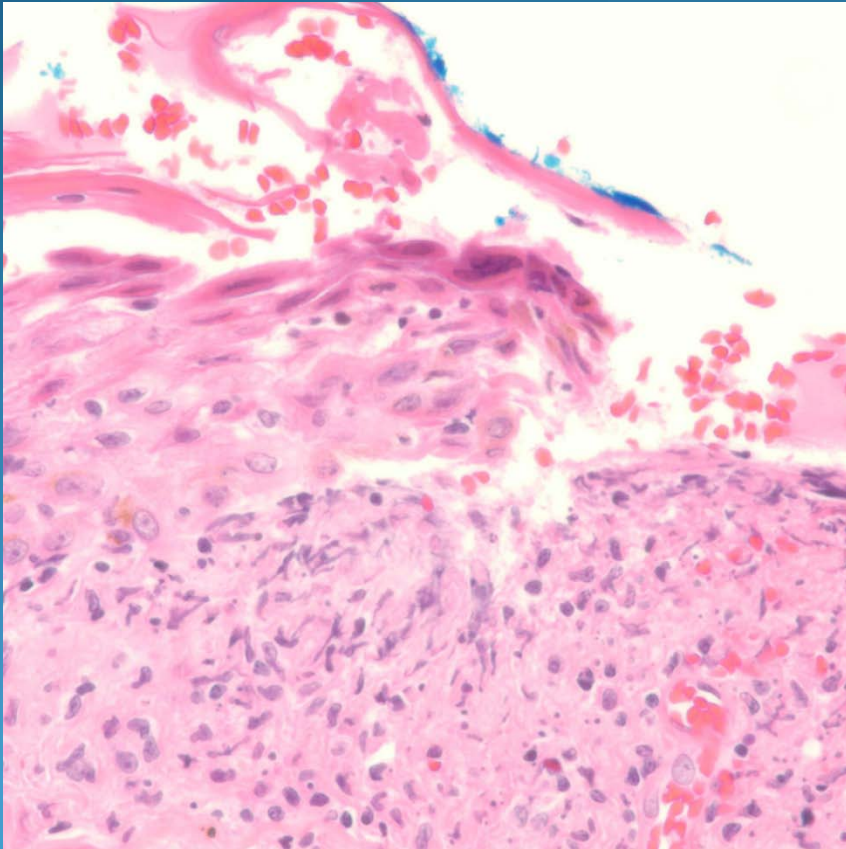


Herpes Simplex Virus Infection

Pearls



- Intraepidermal blister with acantholytic cells
- Viral cytopathic changes with multinucleation and chromatin margination
- May confirm with Ab to HSV 1/2