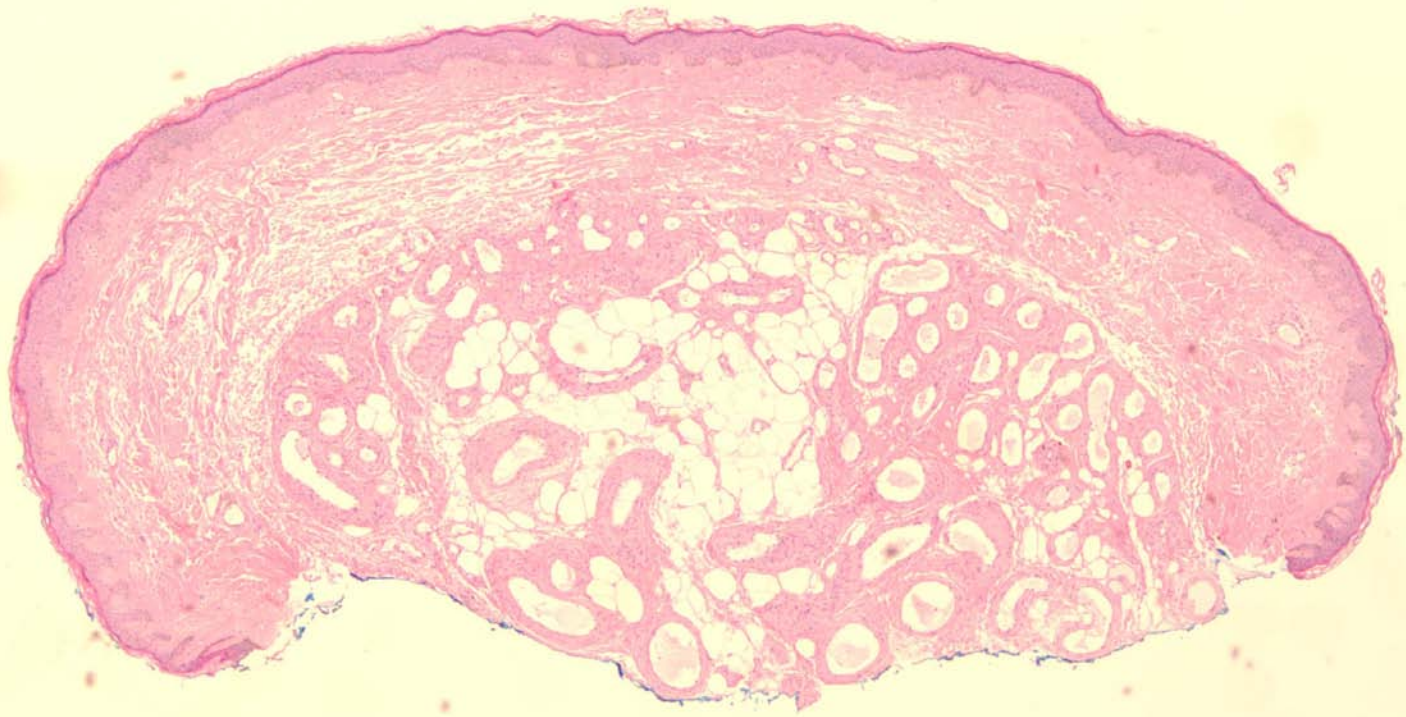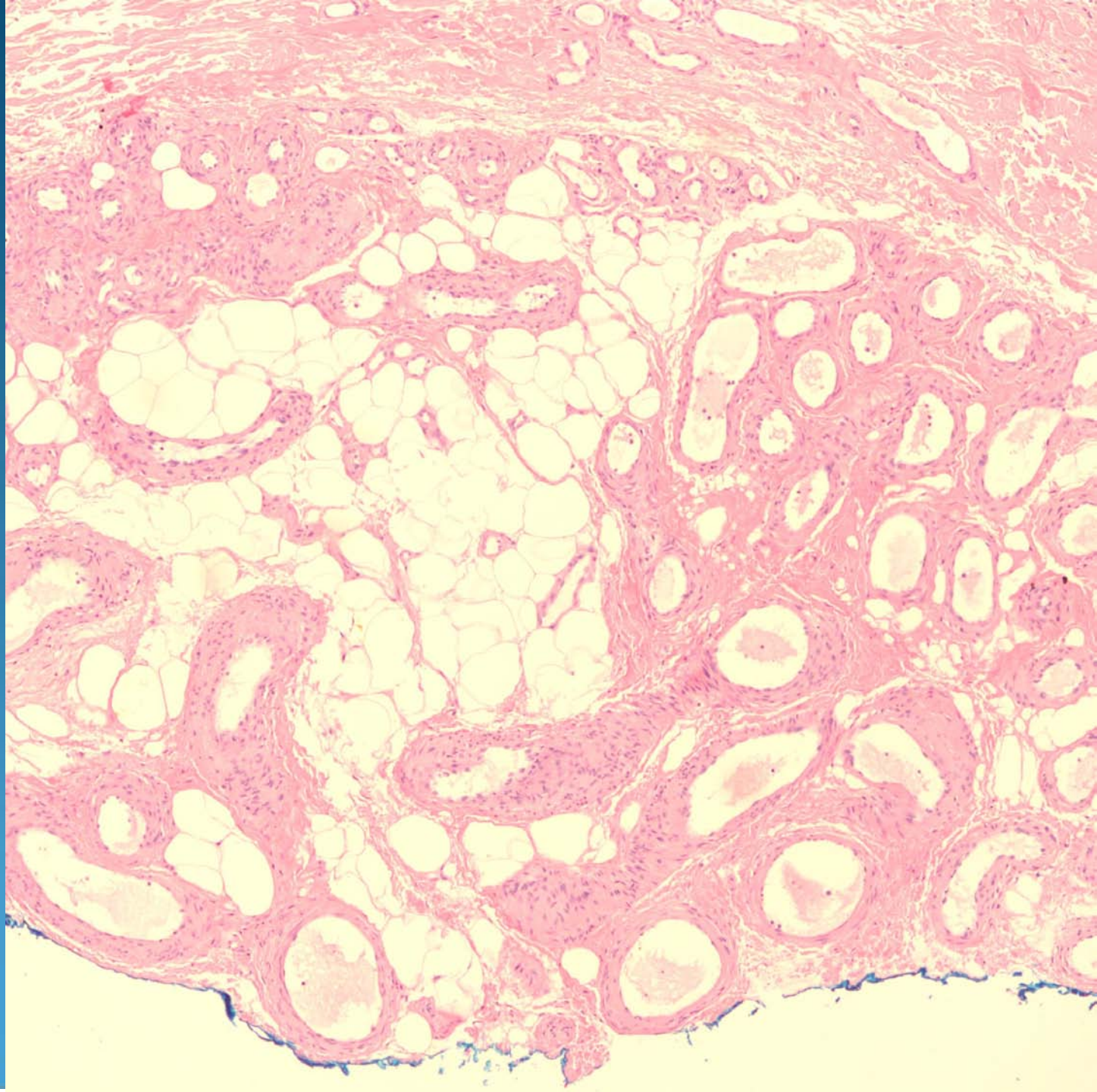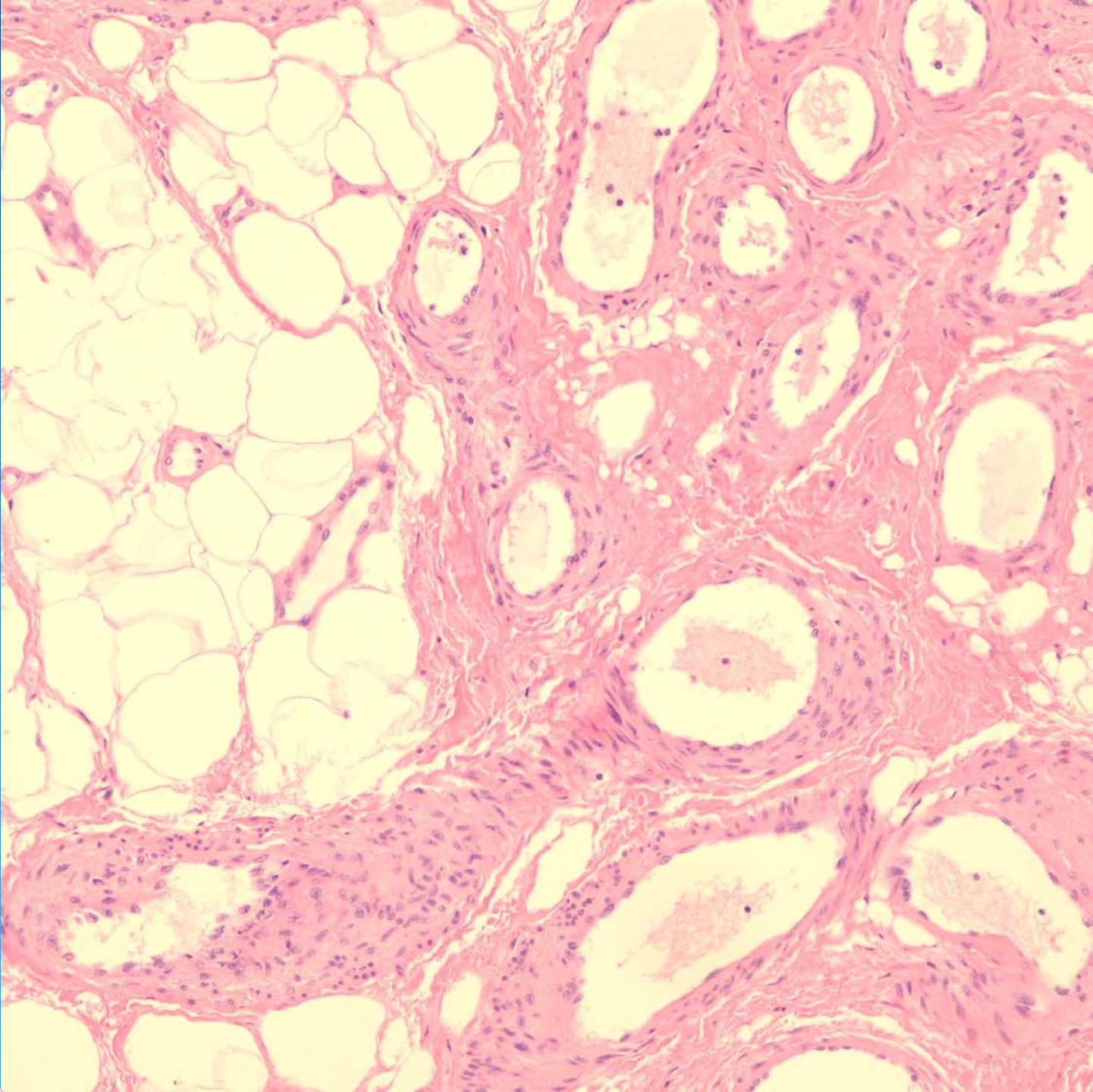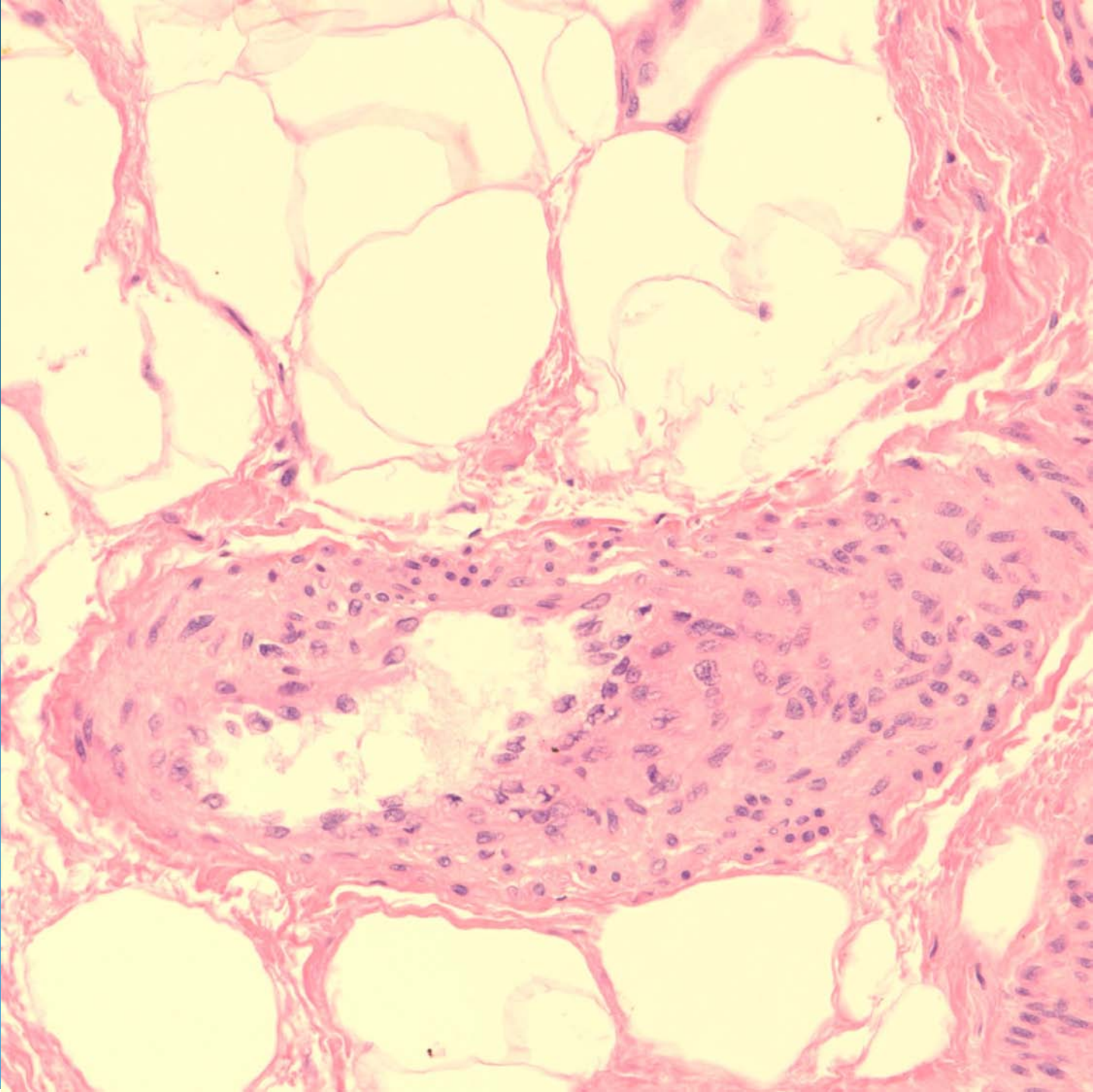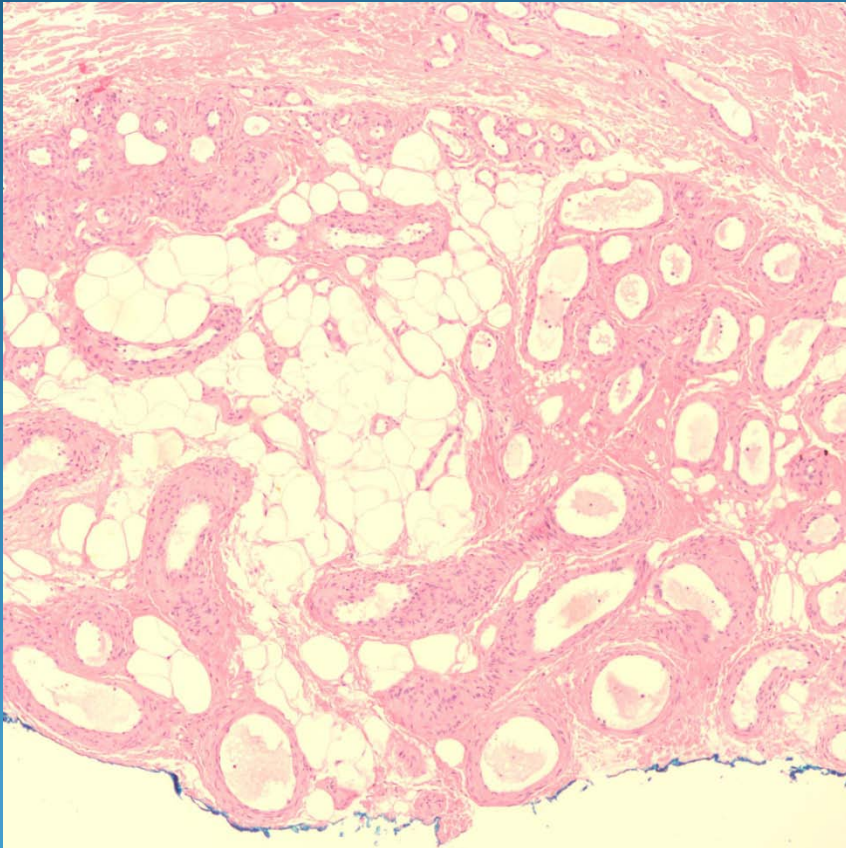


Hemangioma, Cirroid Type

Pearls



- Large muscular thick-walled vessels within superficial dermis
- Tortuous and convoluted contours