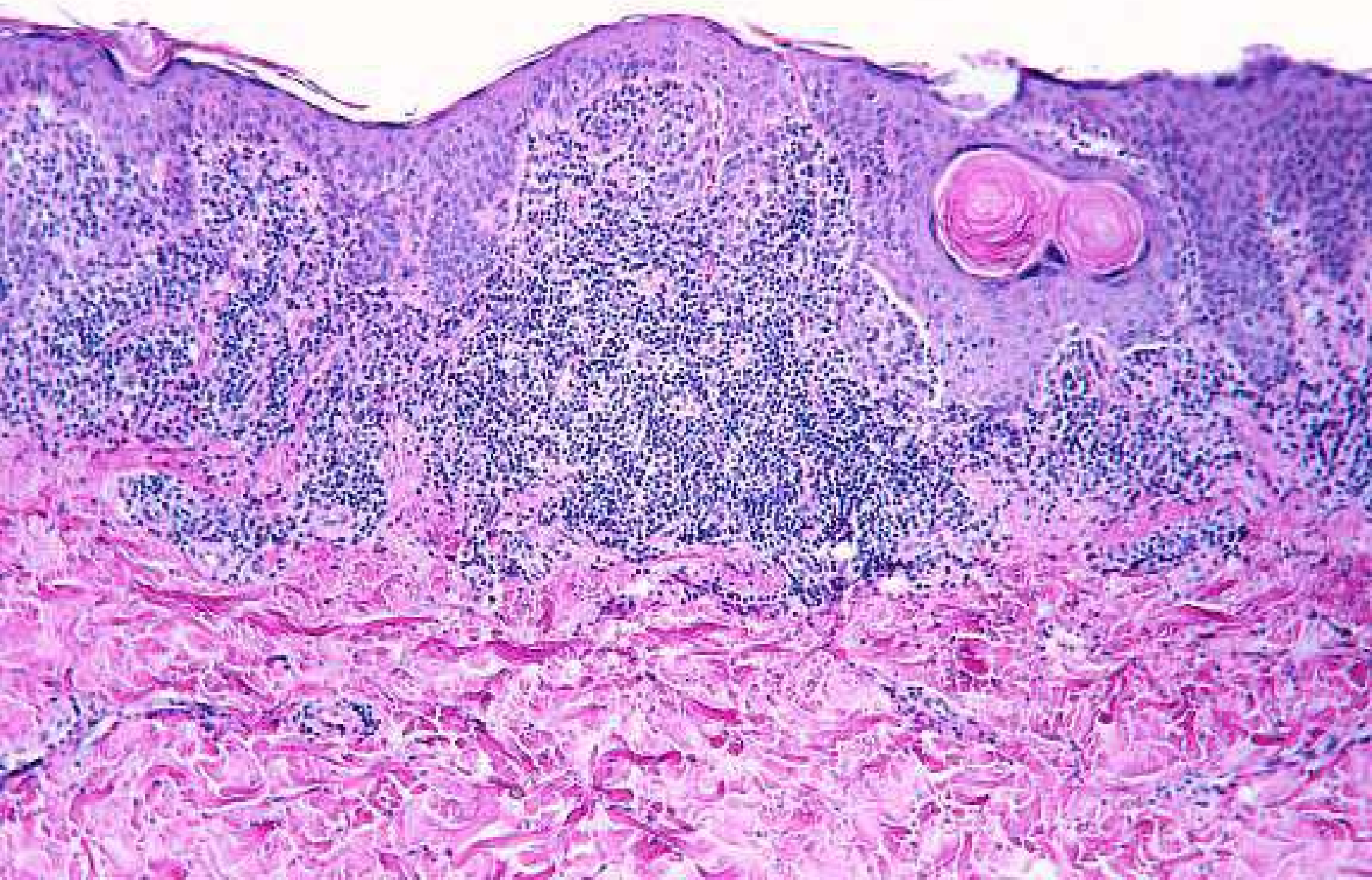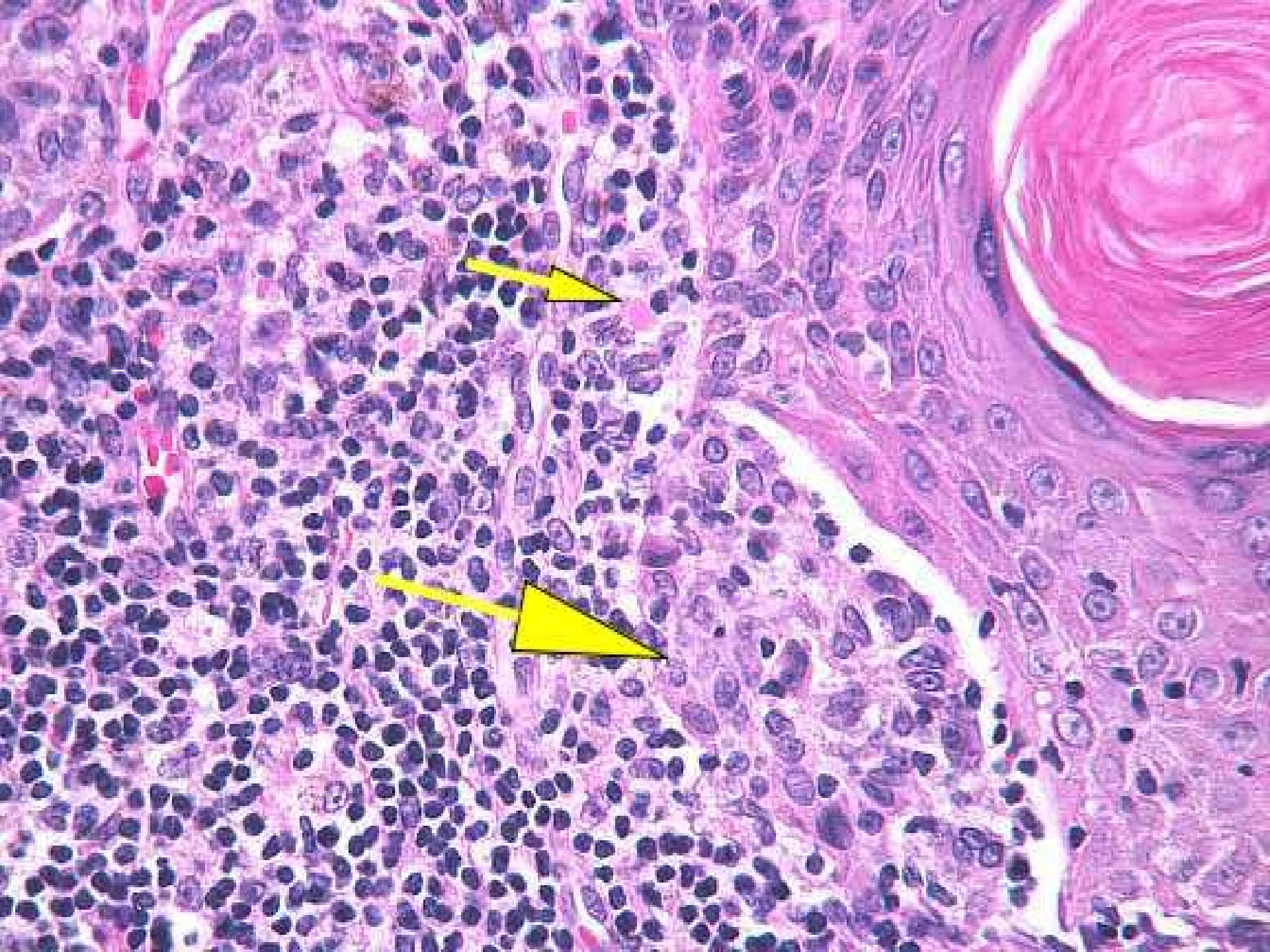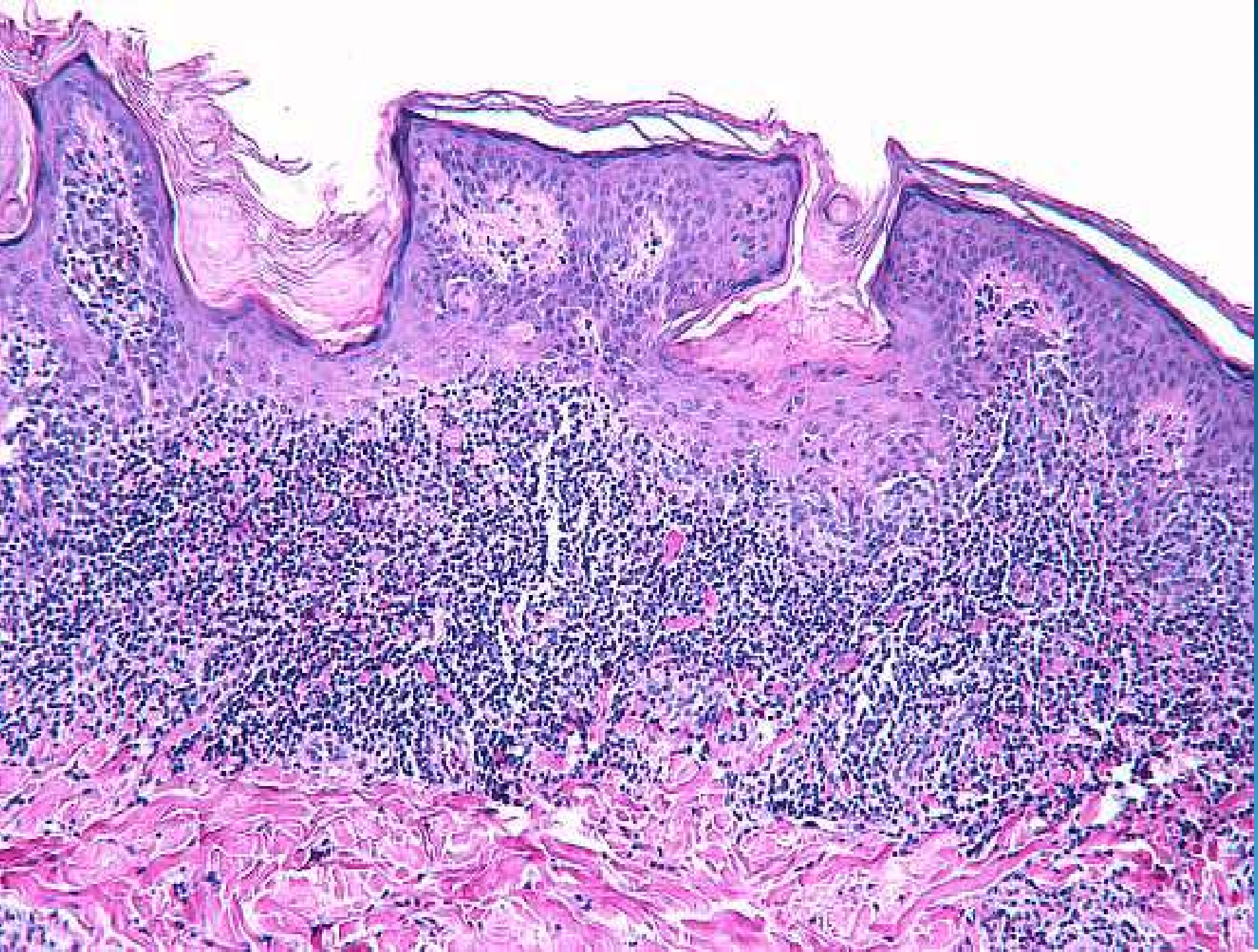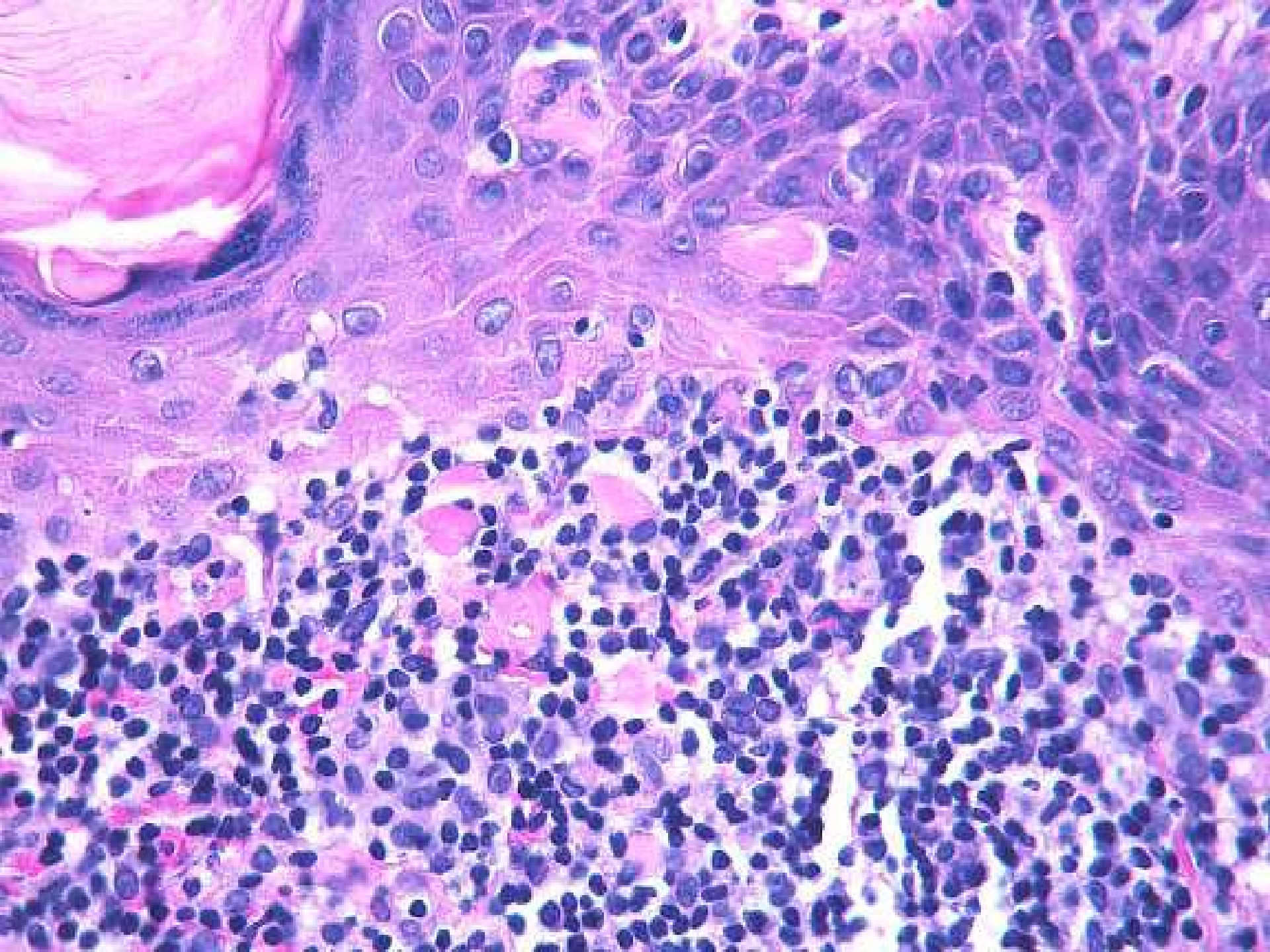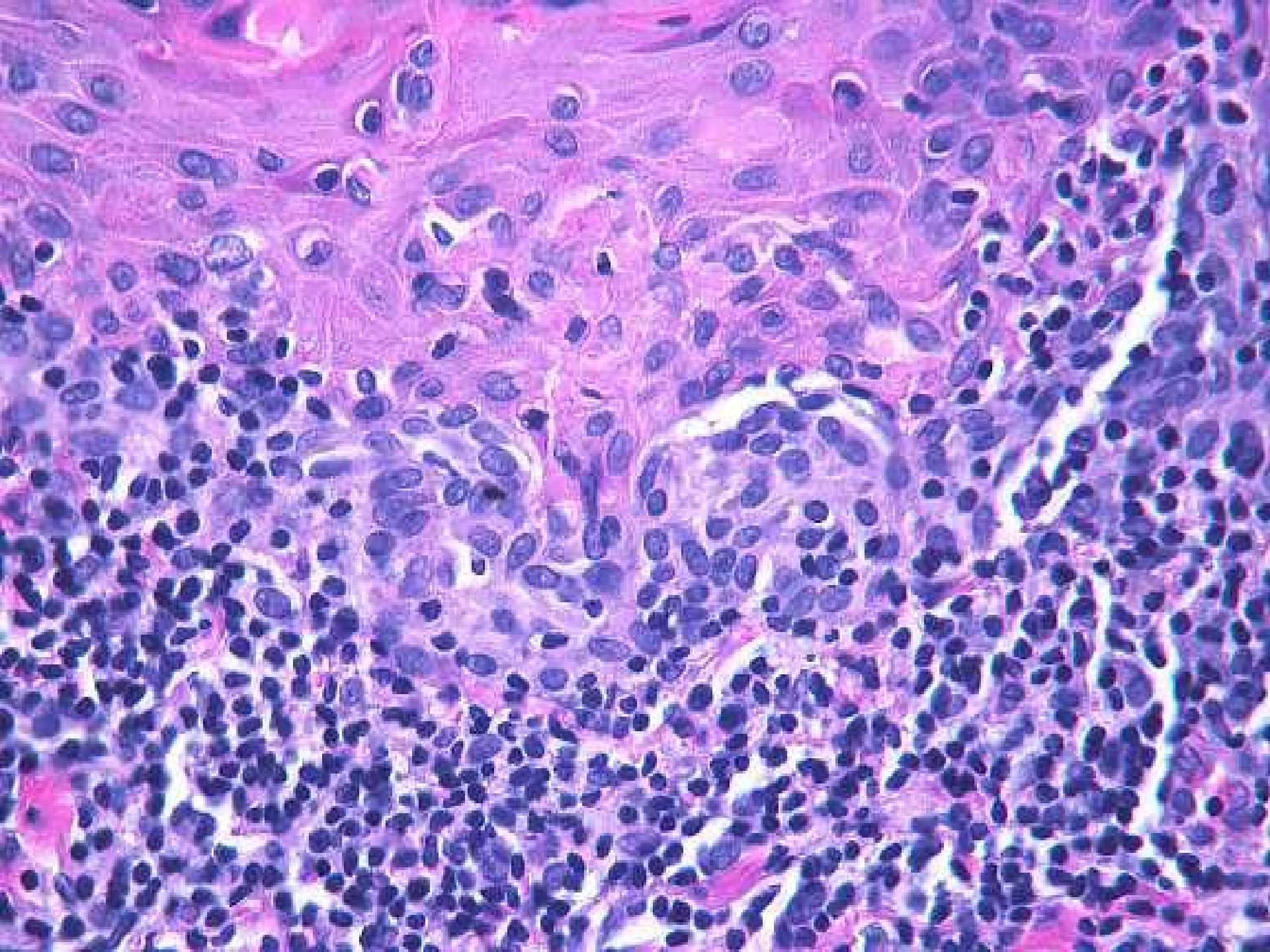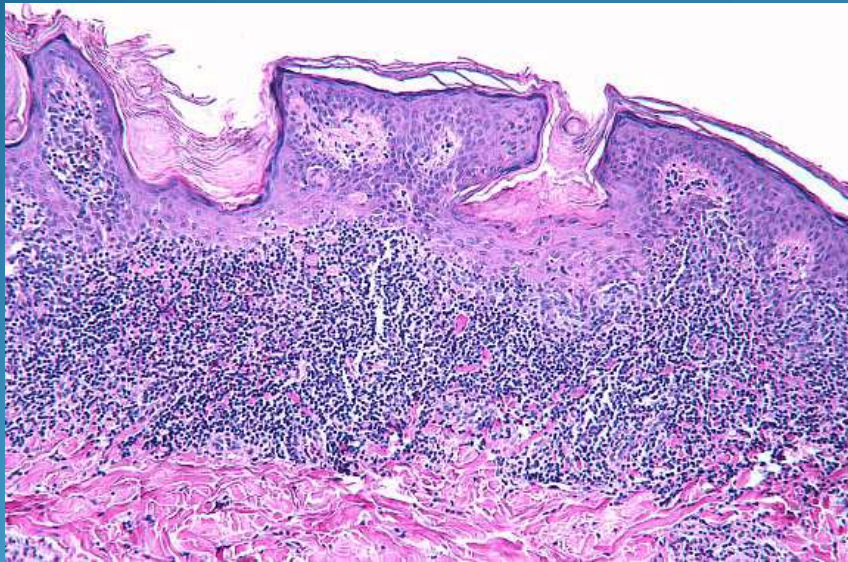


Halo Nevus

Pearls



- Dense lichenoid inflammatory infiltrate
- Look for nests of melanocytes at dermal-epidermal junction or dermis