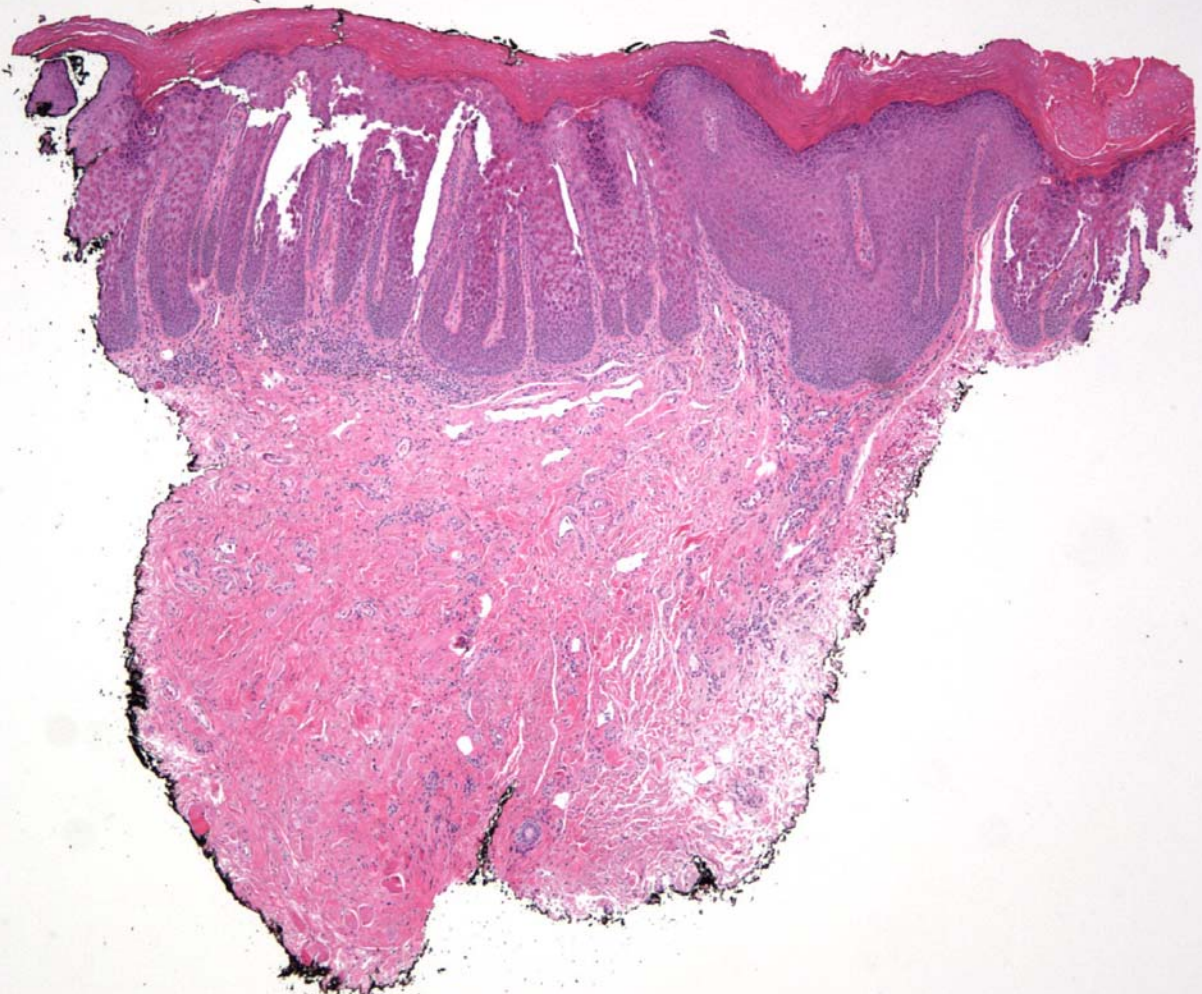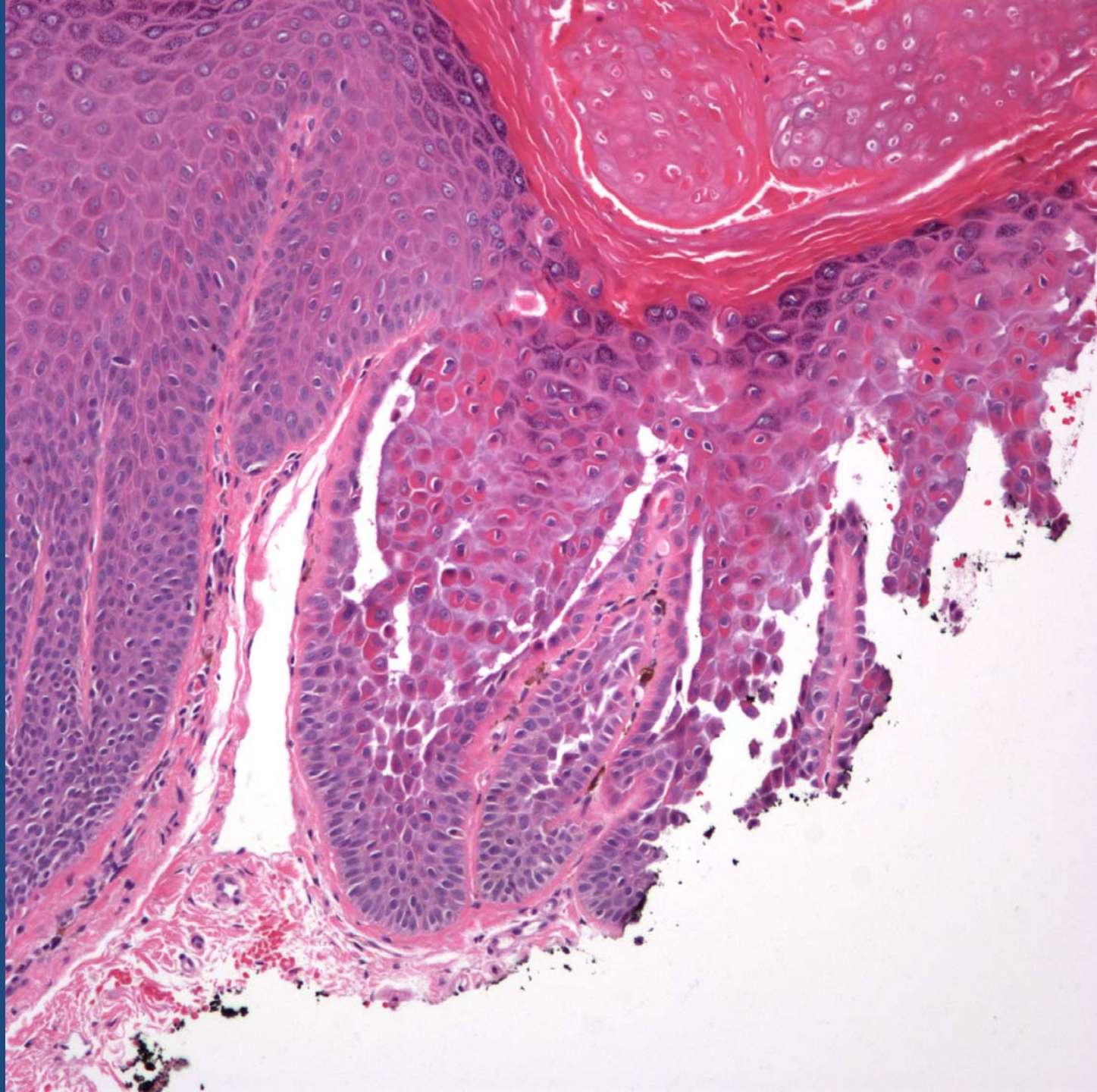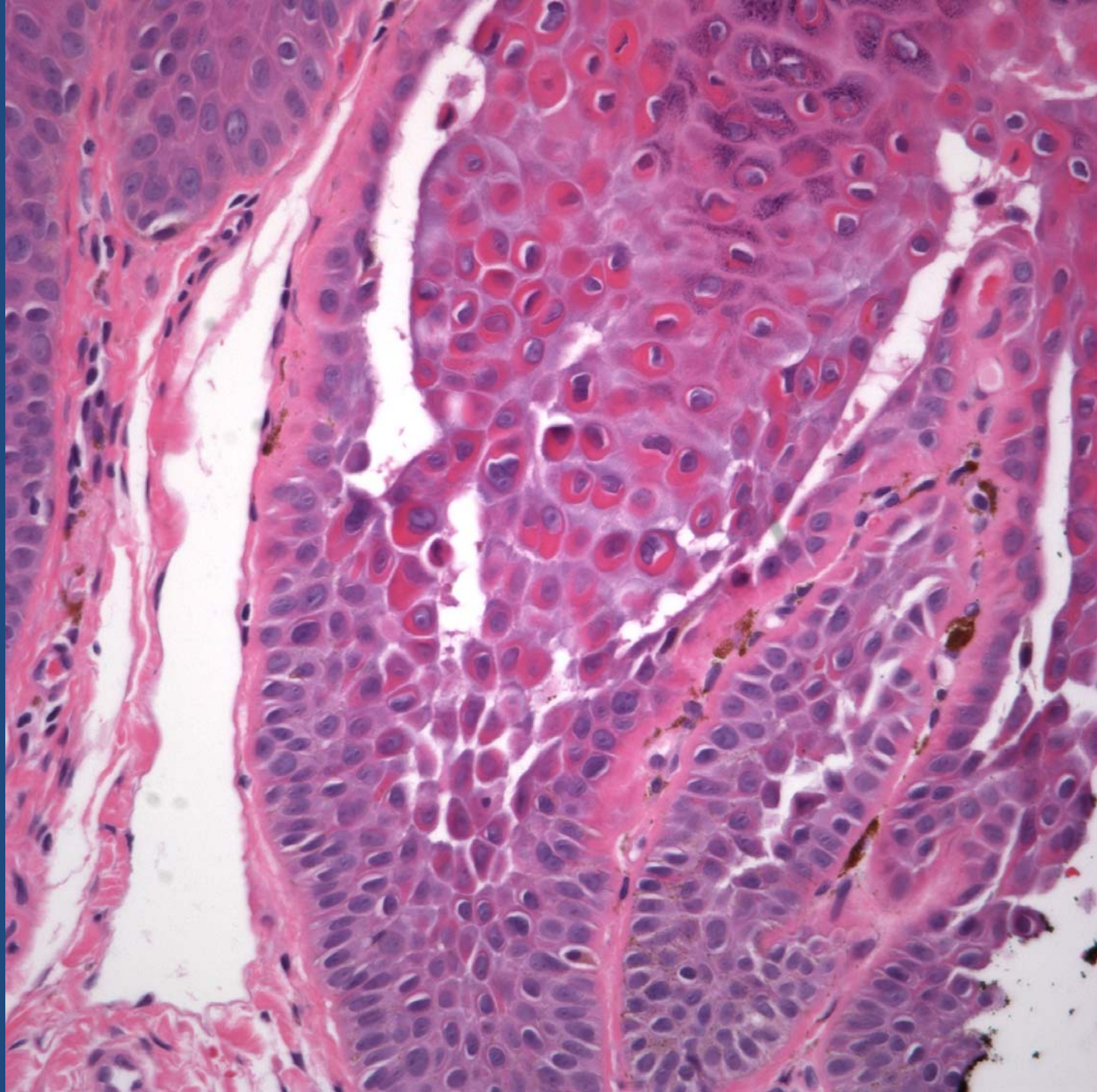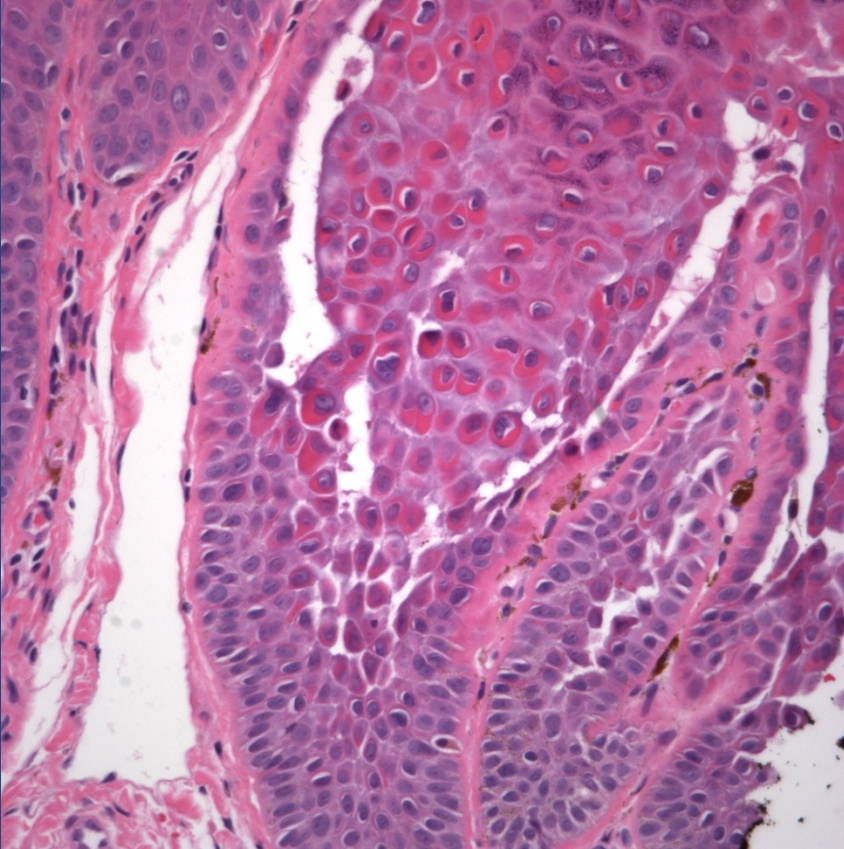


Hailey-Hailey Disease

Pearls



- Dilapidated, crumbling brick pattern
- Intraepidermal acantholysis
- No corp ronds or corp grains
- Minimal inflammation
- DIF negative