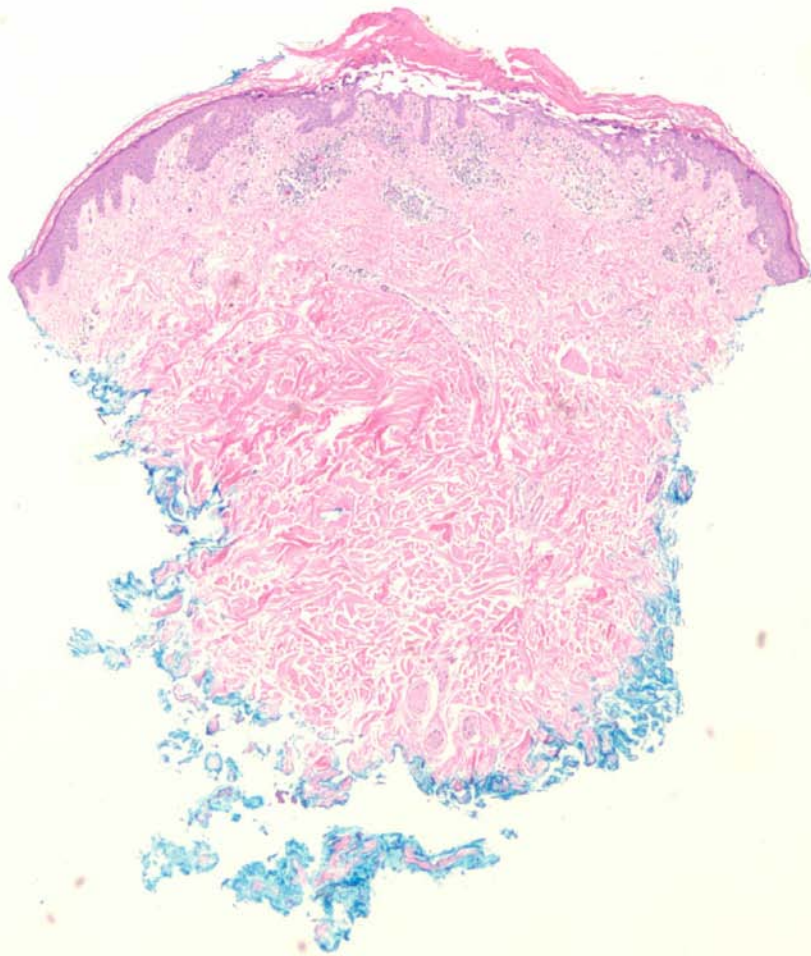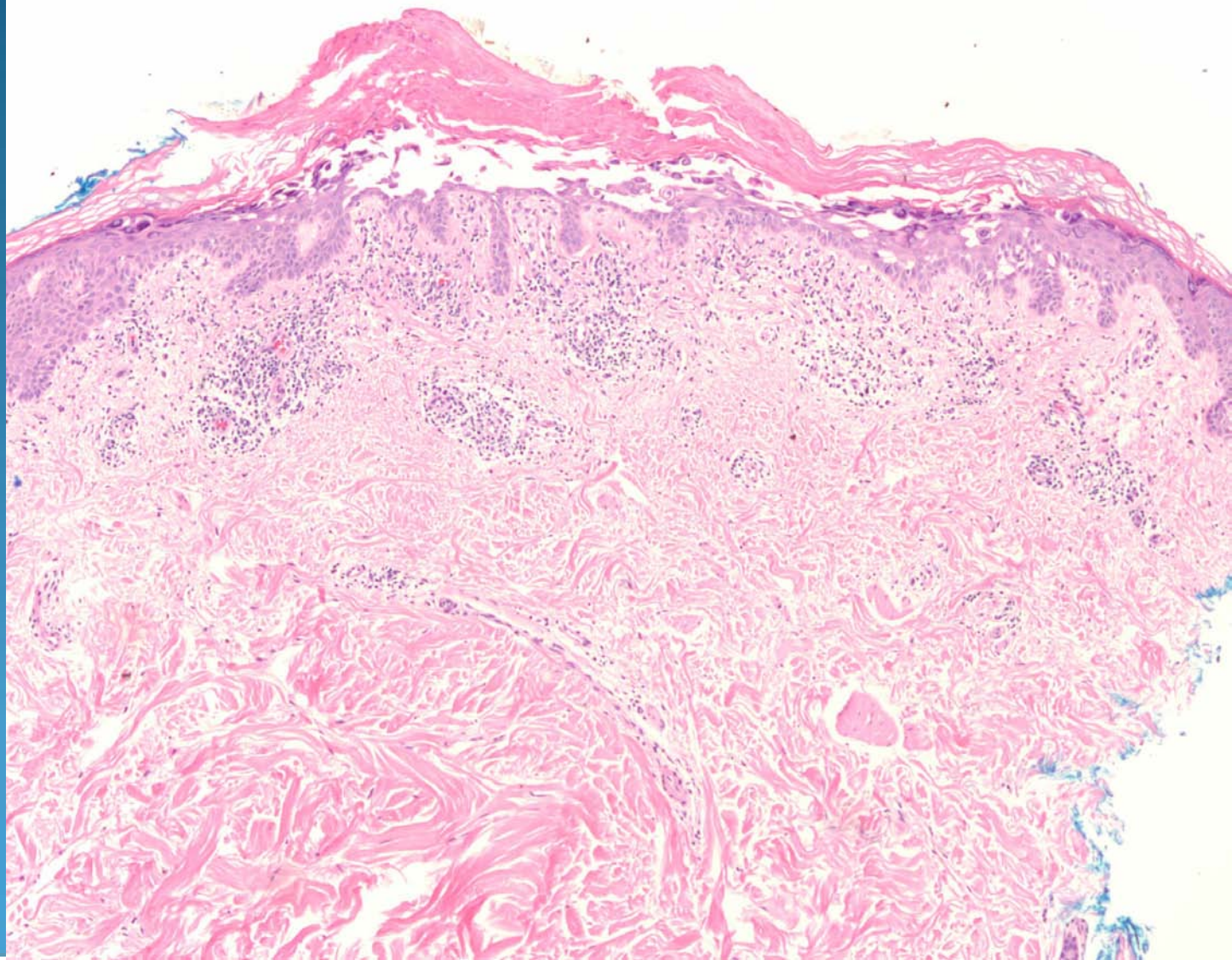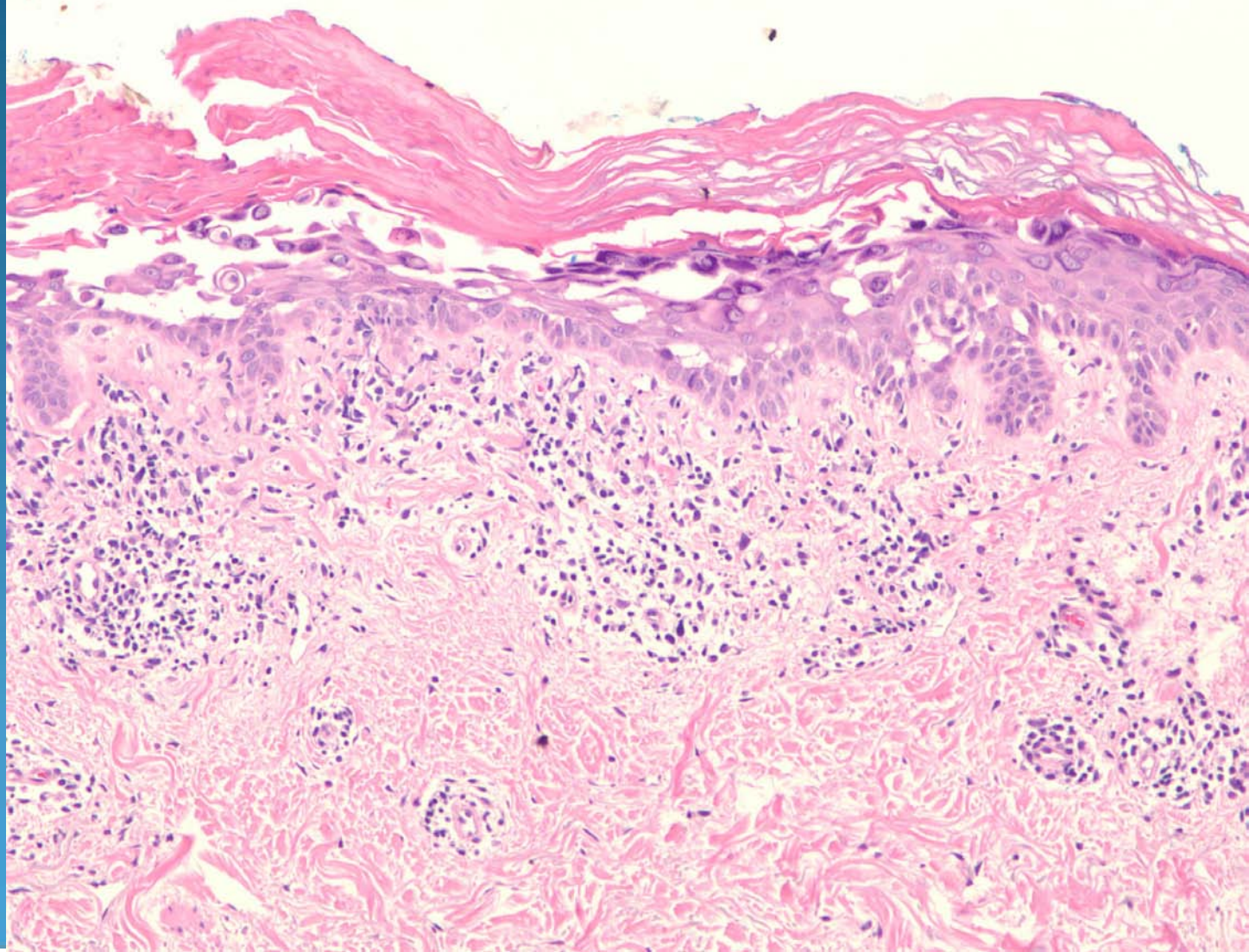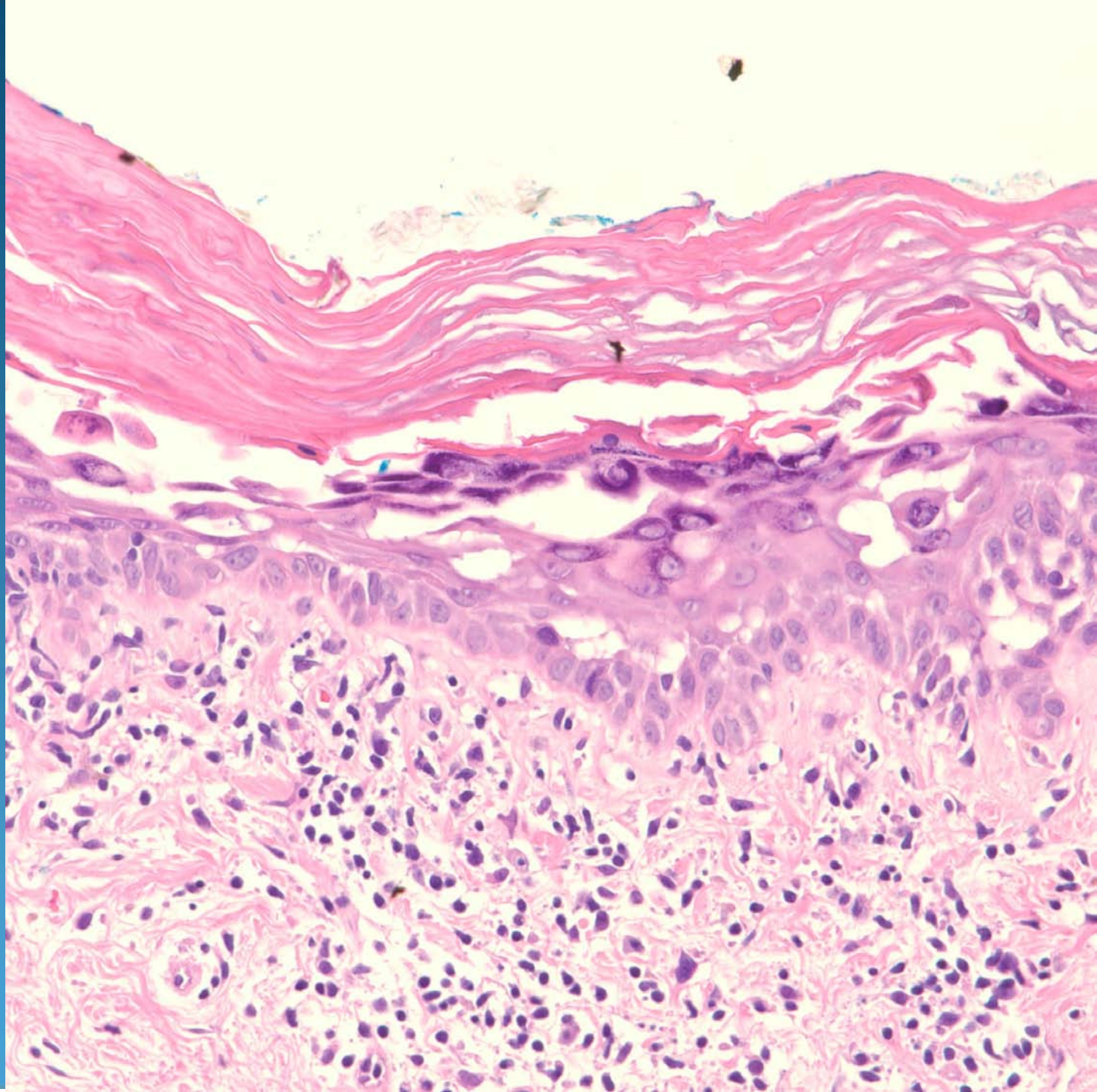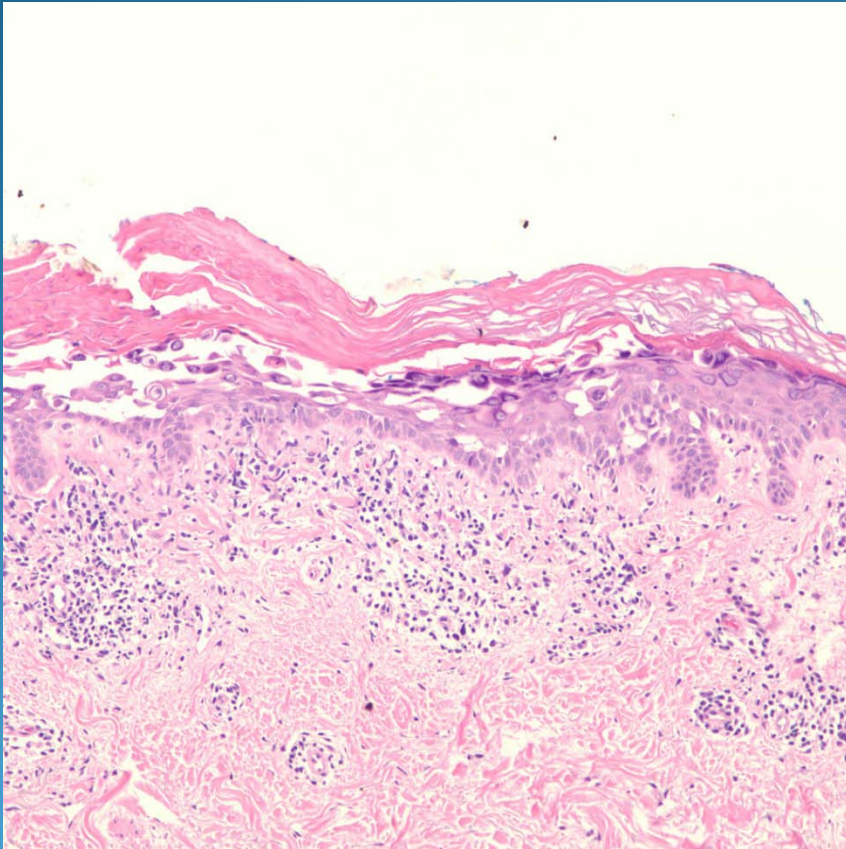


Grover's Disease

Pearls



- Acantholytic dyskeratosis with mixed pattern (in this case corns and corn grains with suprabasilar acantholysis)
- Frequent scale crust
- Usually minimal eosinophils