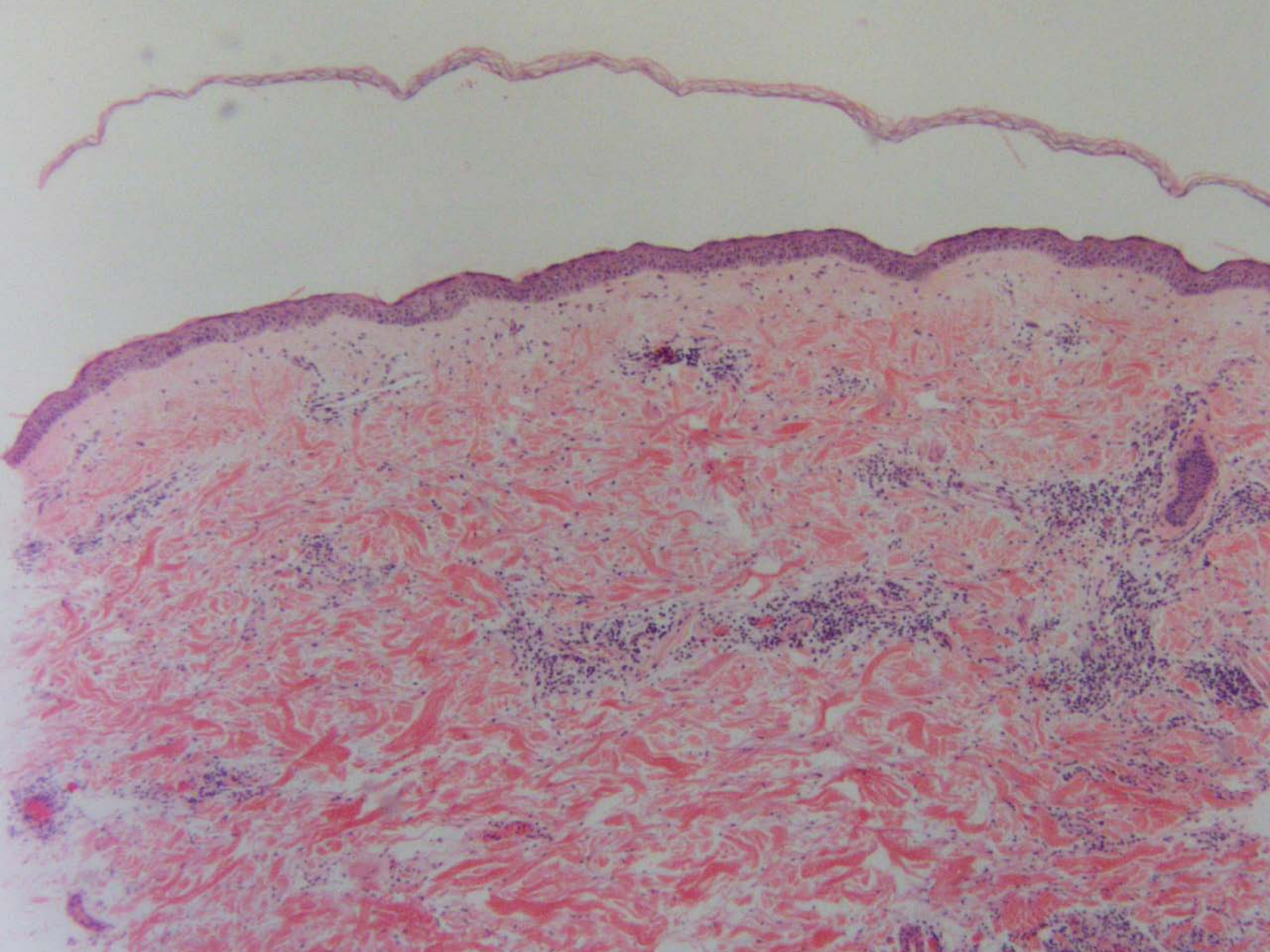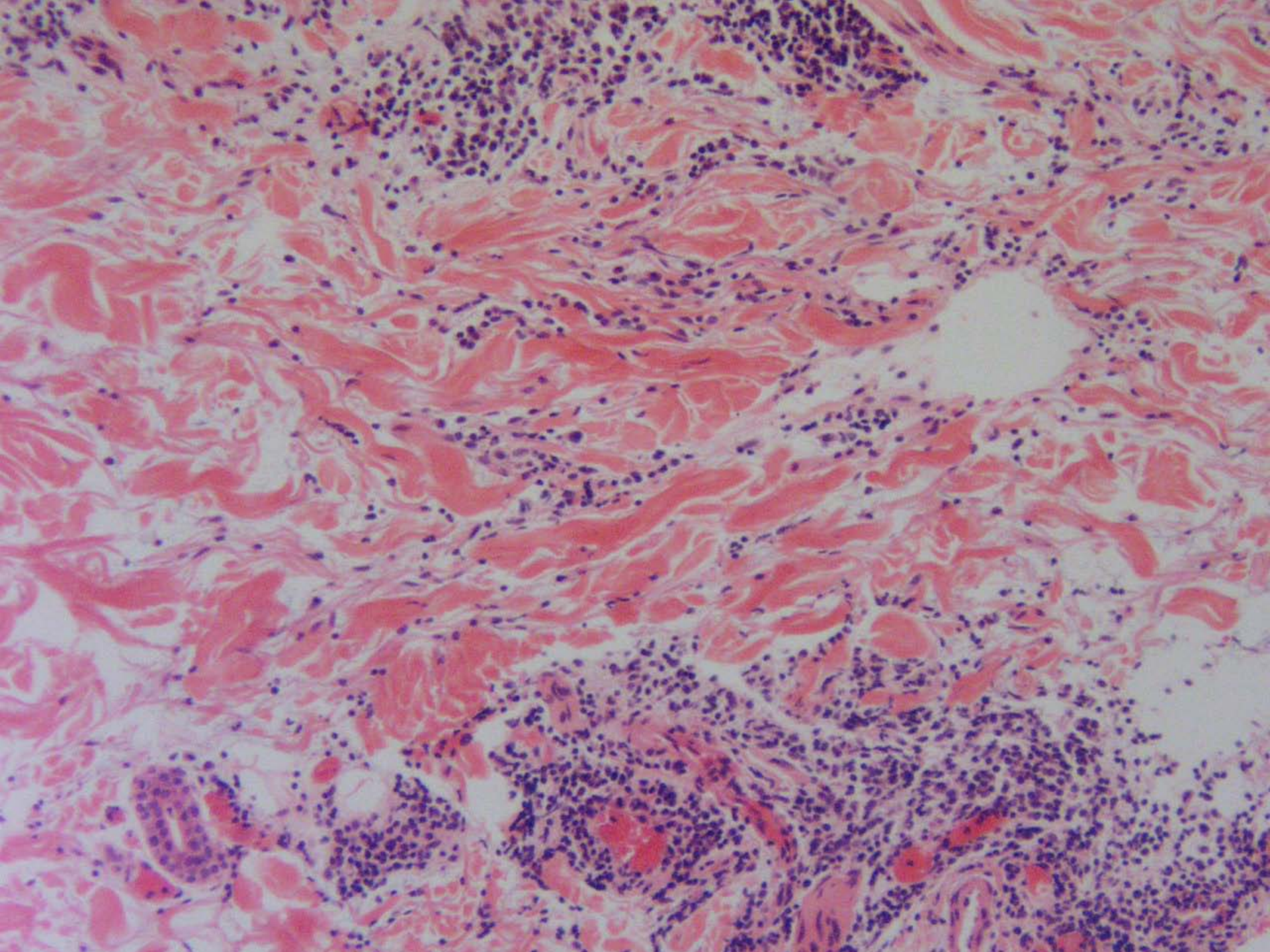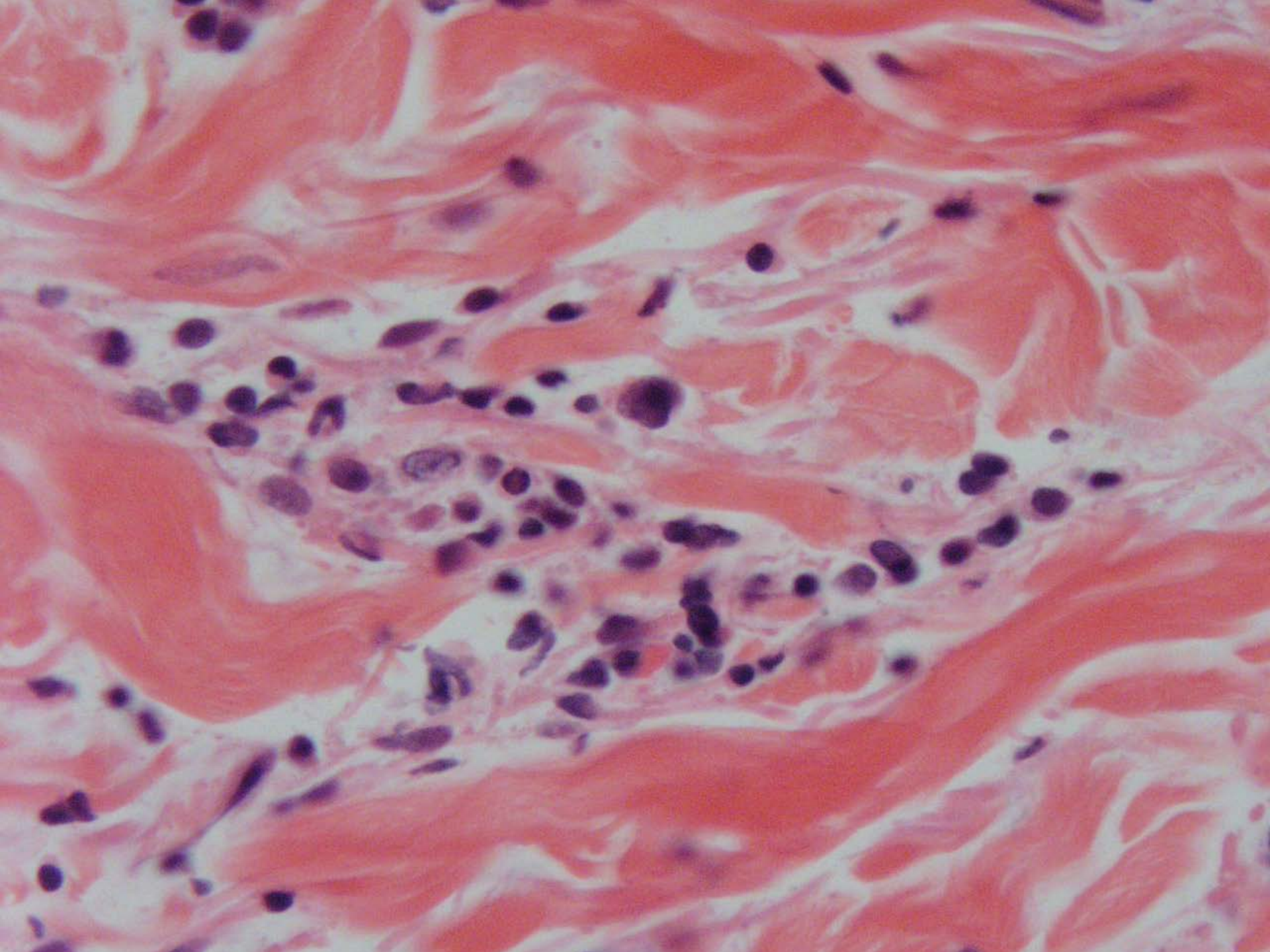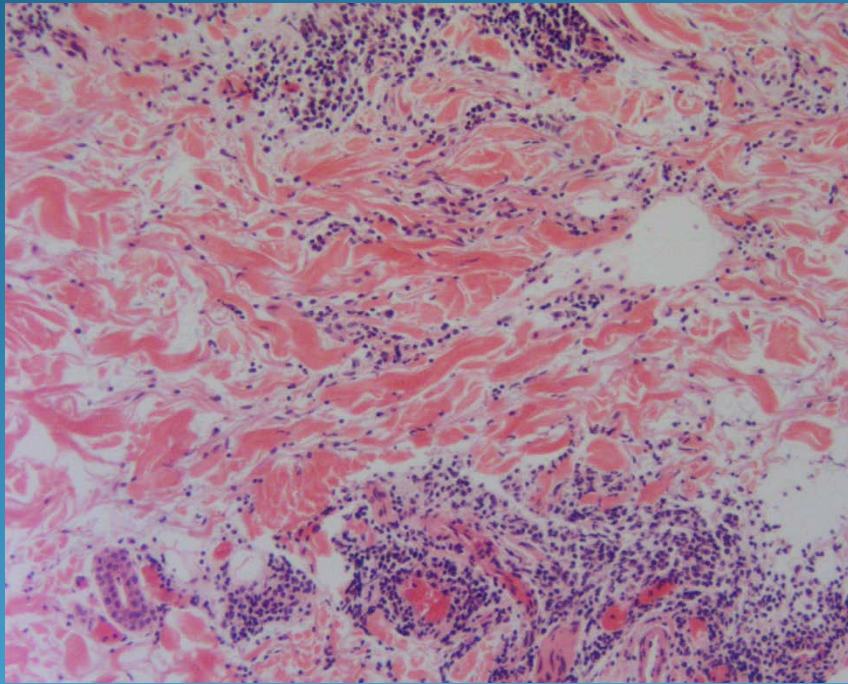


Granuloma Annulare- Interstitial type (Incomplete)

Pearls



- Busy dermis with histiocytes and lymphocytes dissecting collagen
- Reminiscent of “indian filing”