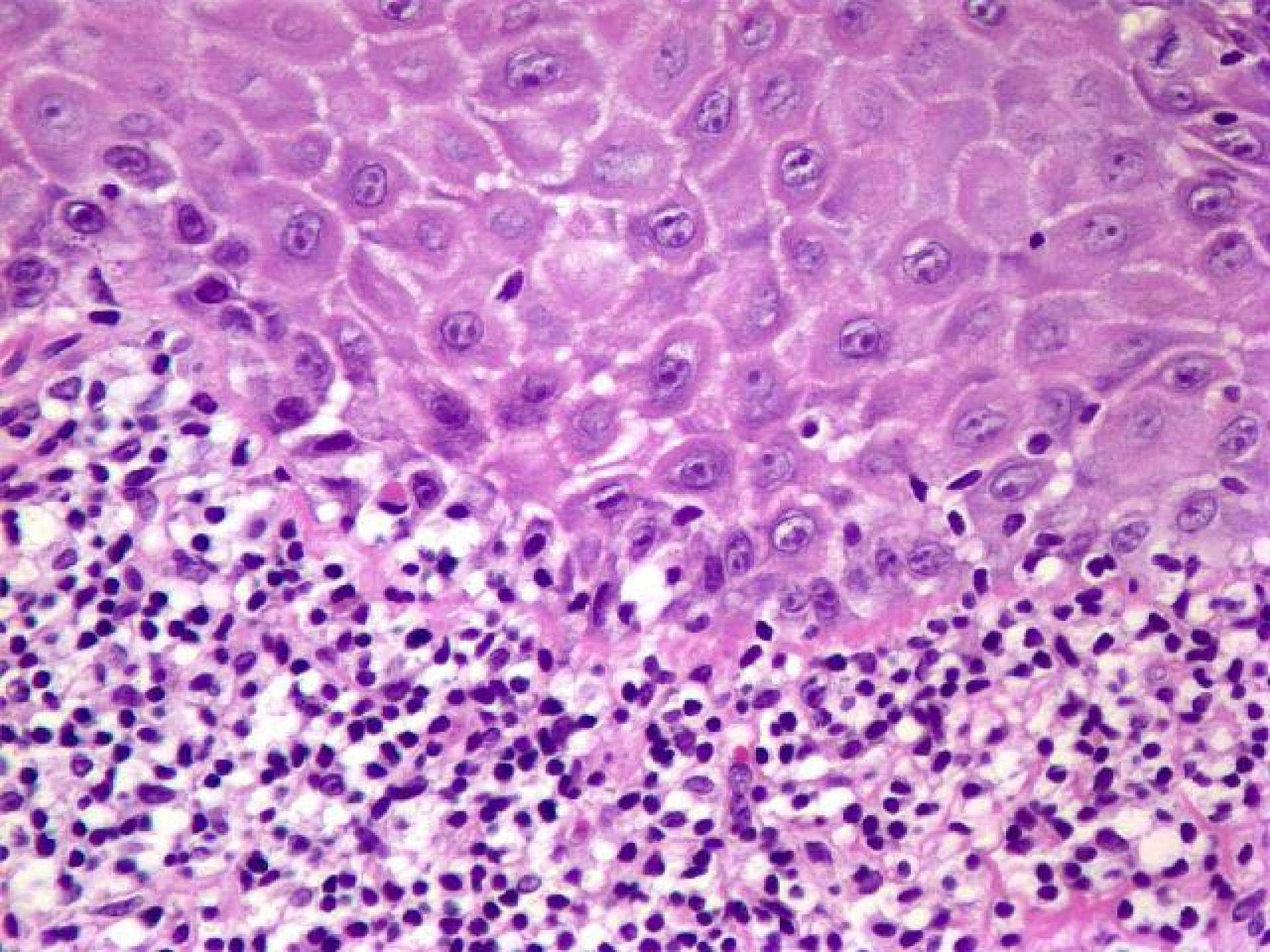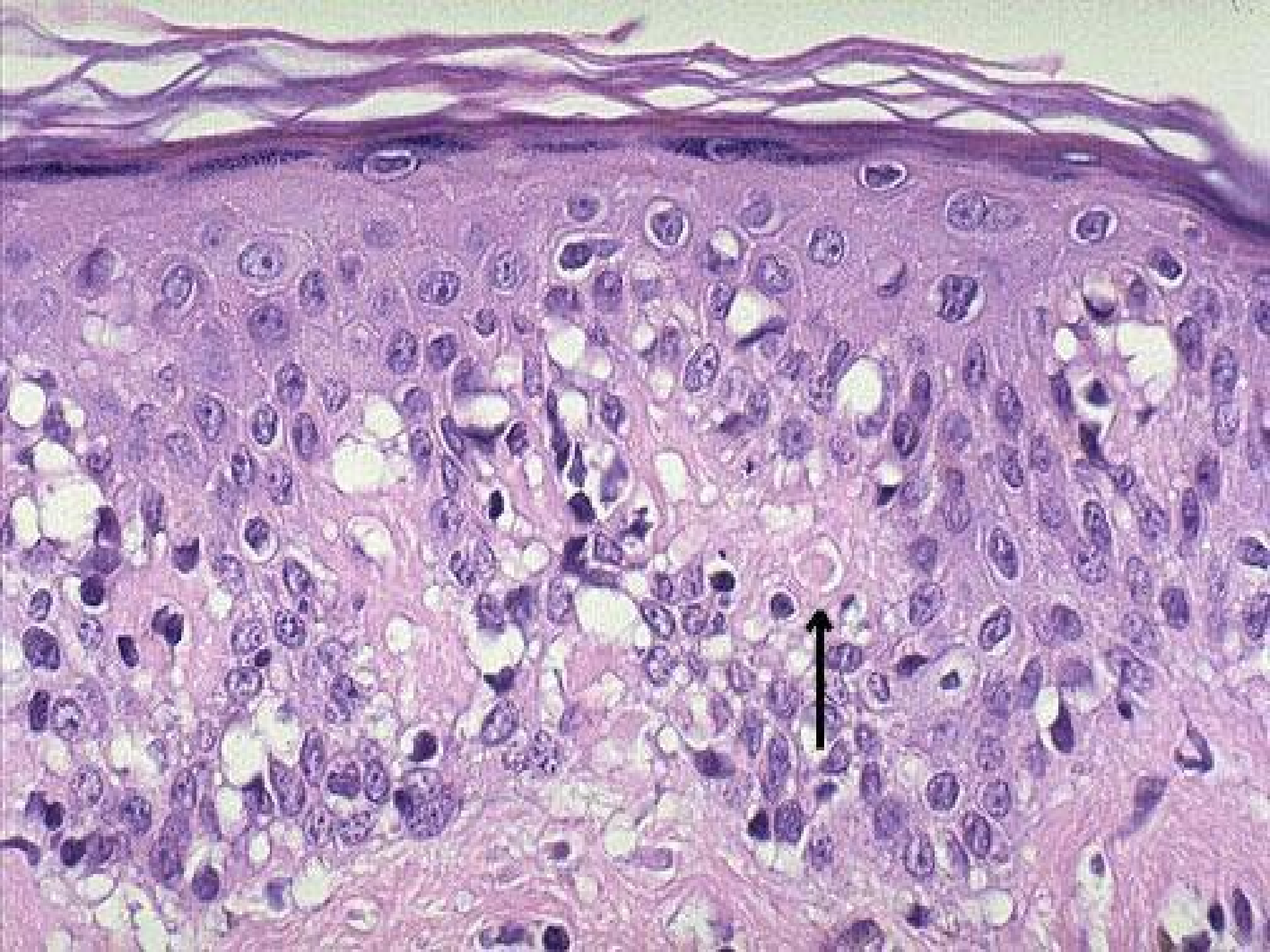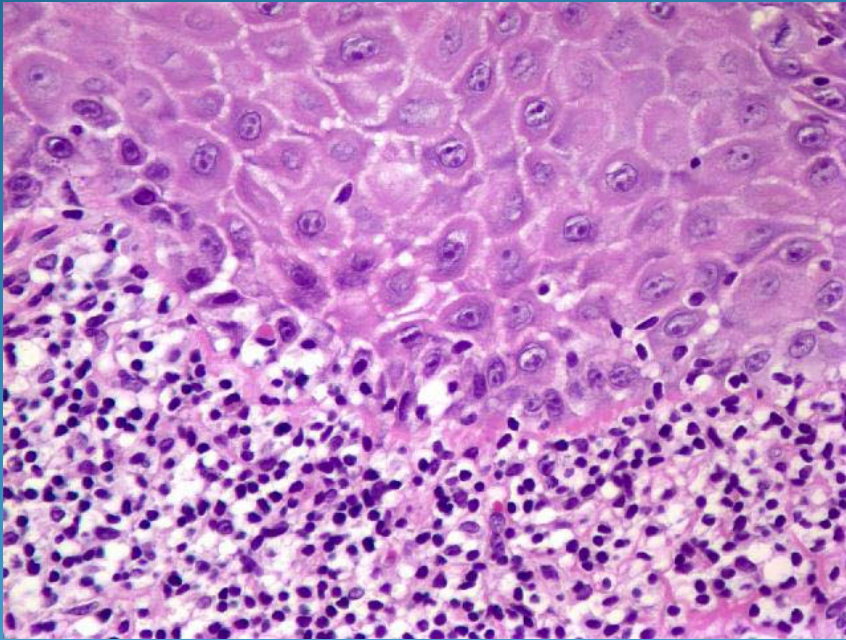


Graft versus Host Disease

Pearls



- Lichenoid interface dermatitis
- Look for dyskeratotic keratinocytes especially along adnexal epithelium