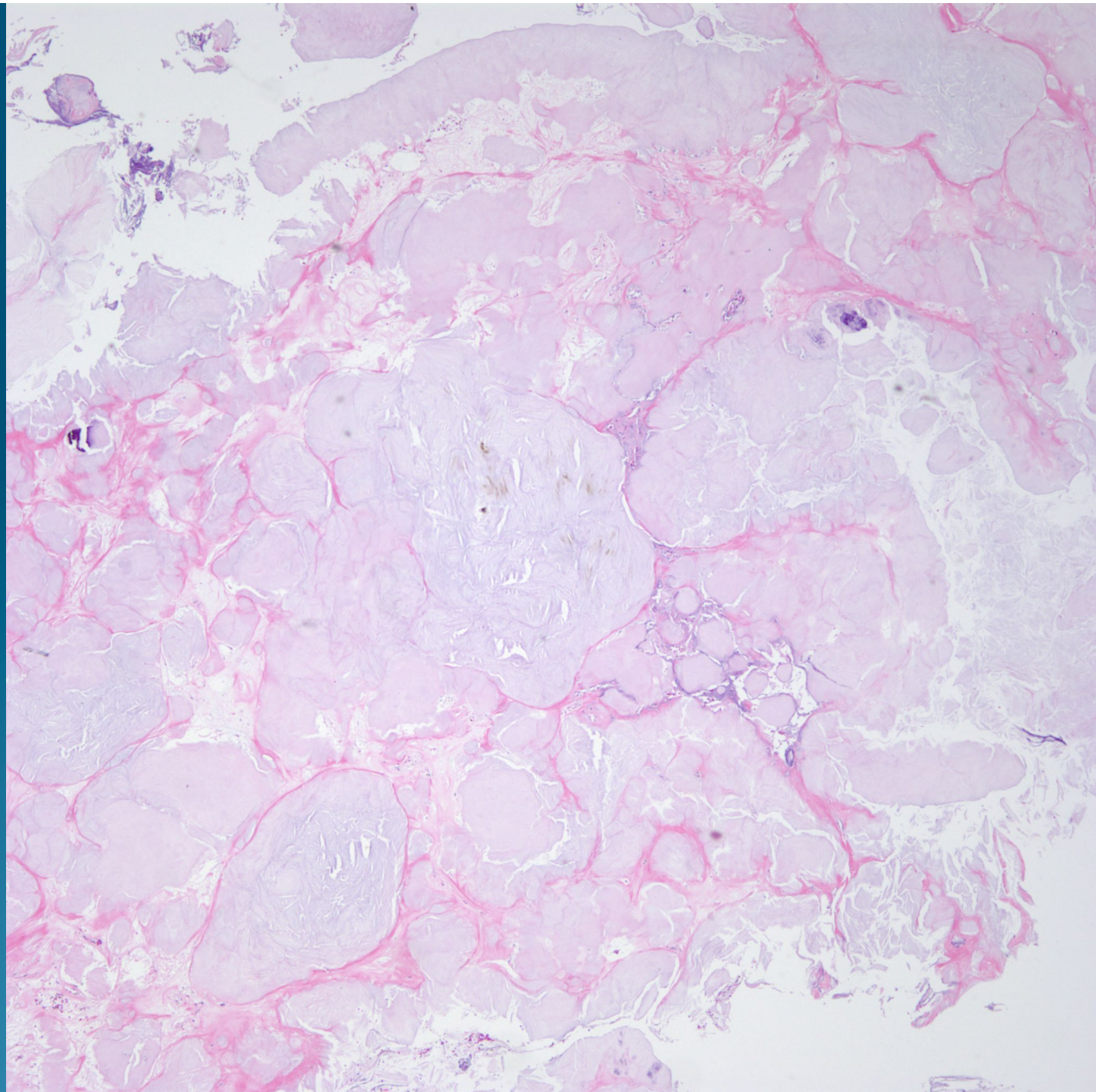
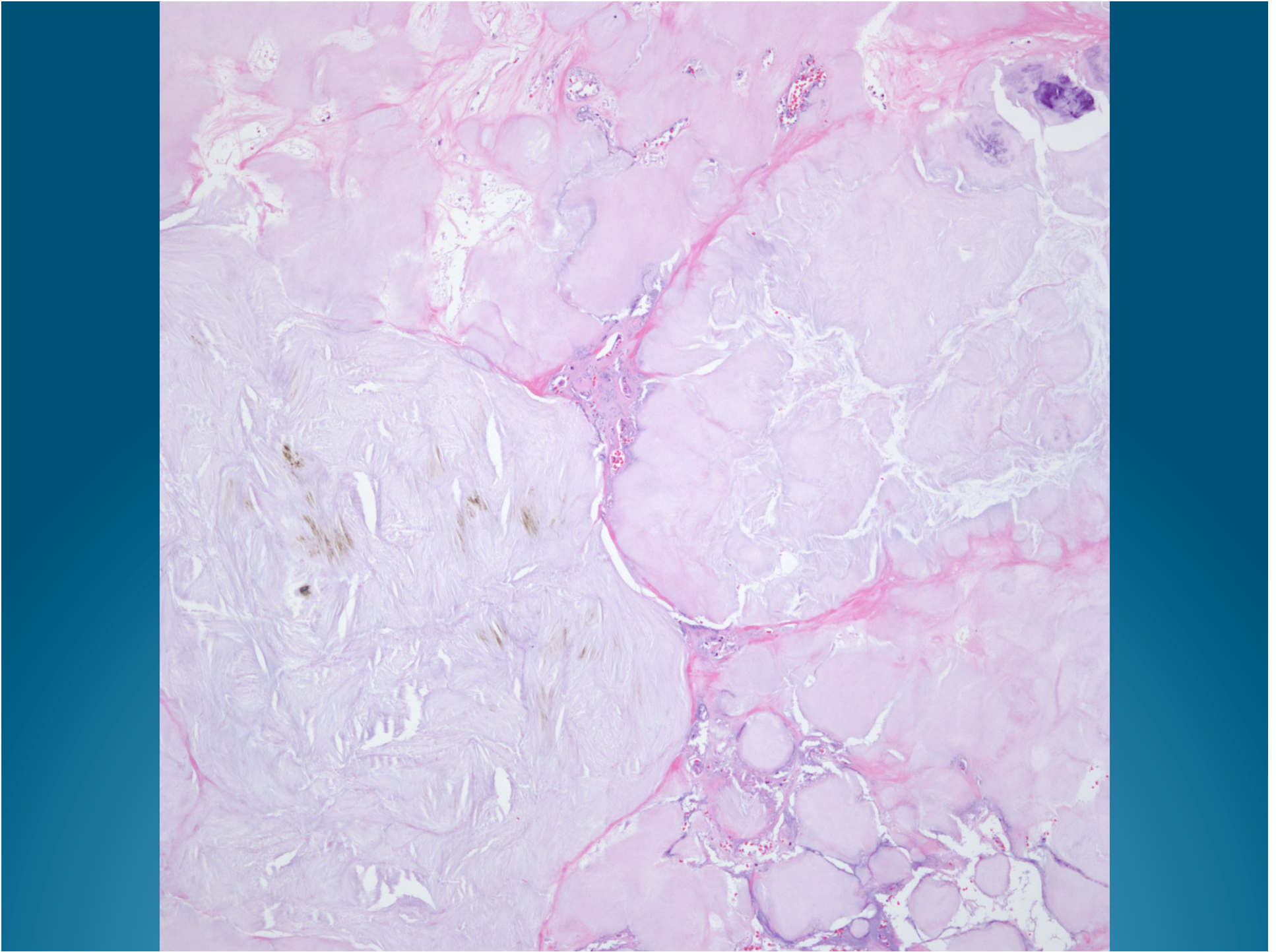
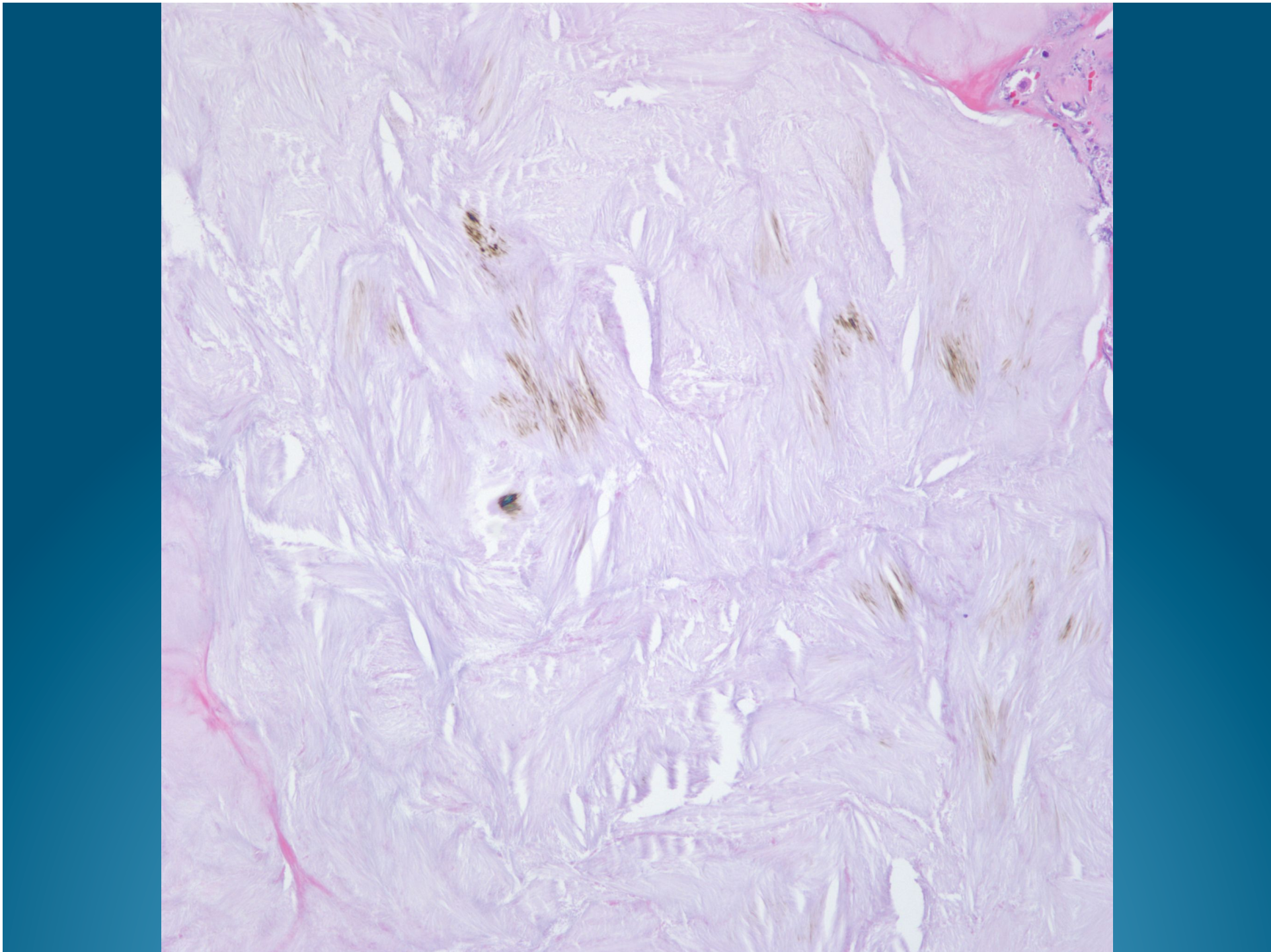
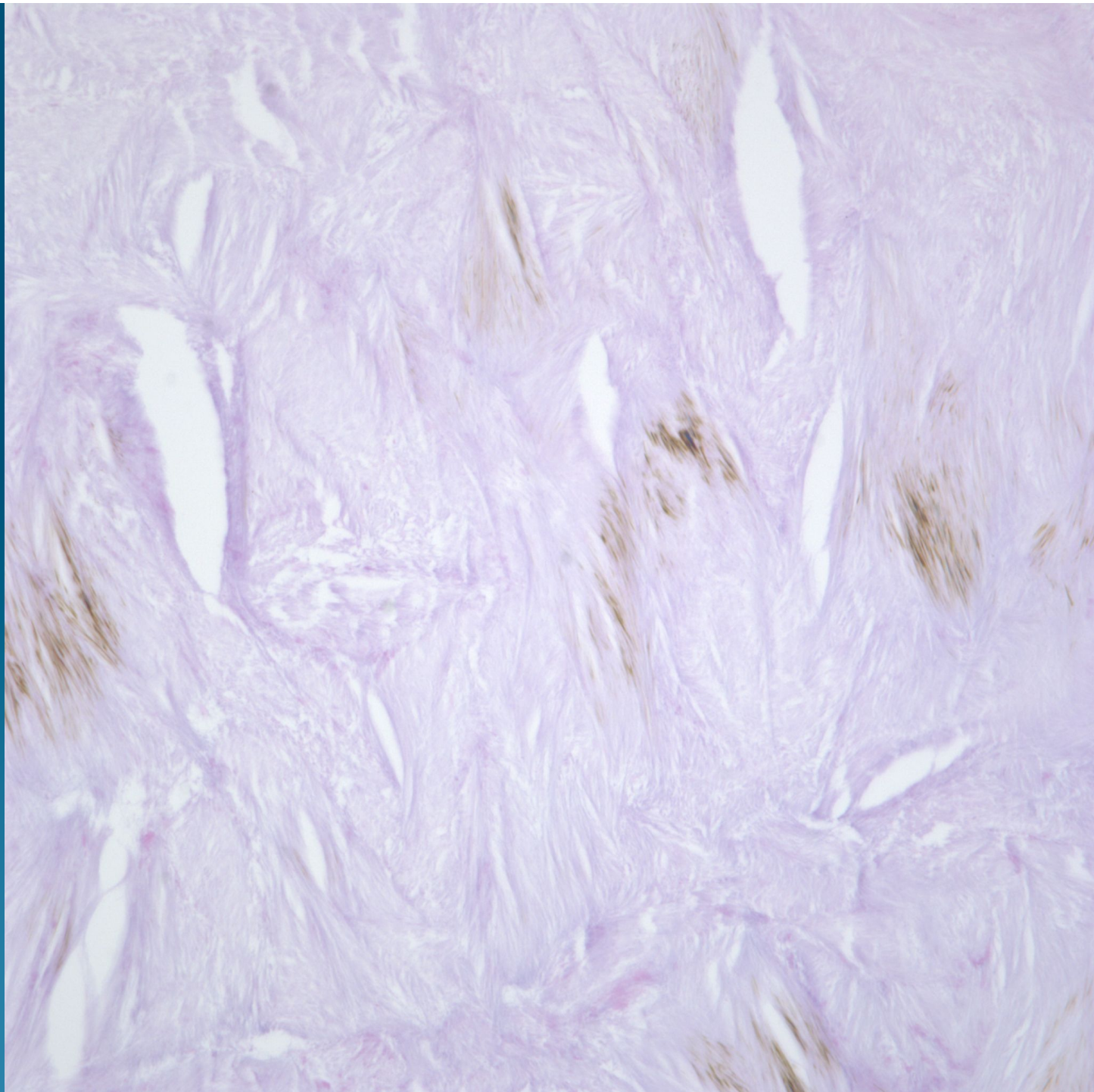What is the best diagnosis?

- A. Tophus
- B. Amyloidoma
- C. Necrobiotic granuloma
- D. Colloid Millium
- E. Paraffinoma

Gouty Tophus

Polarized Light Examination



Notes

- Although Uric acid crystals are water soluble and usually do not survive routine tissue processing, it is still possible to obtain H&E stained sections that preserve the histopathology of gout.
- Polarization is helpful to illustrate the needle-like crystals

Amorphous paucicellular collections of crystals

Foreign body
Type giant cells

Variable calcifications

