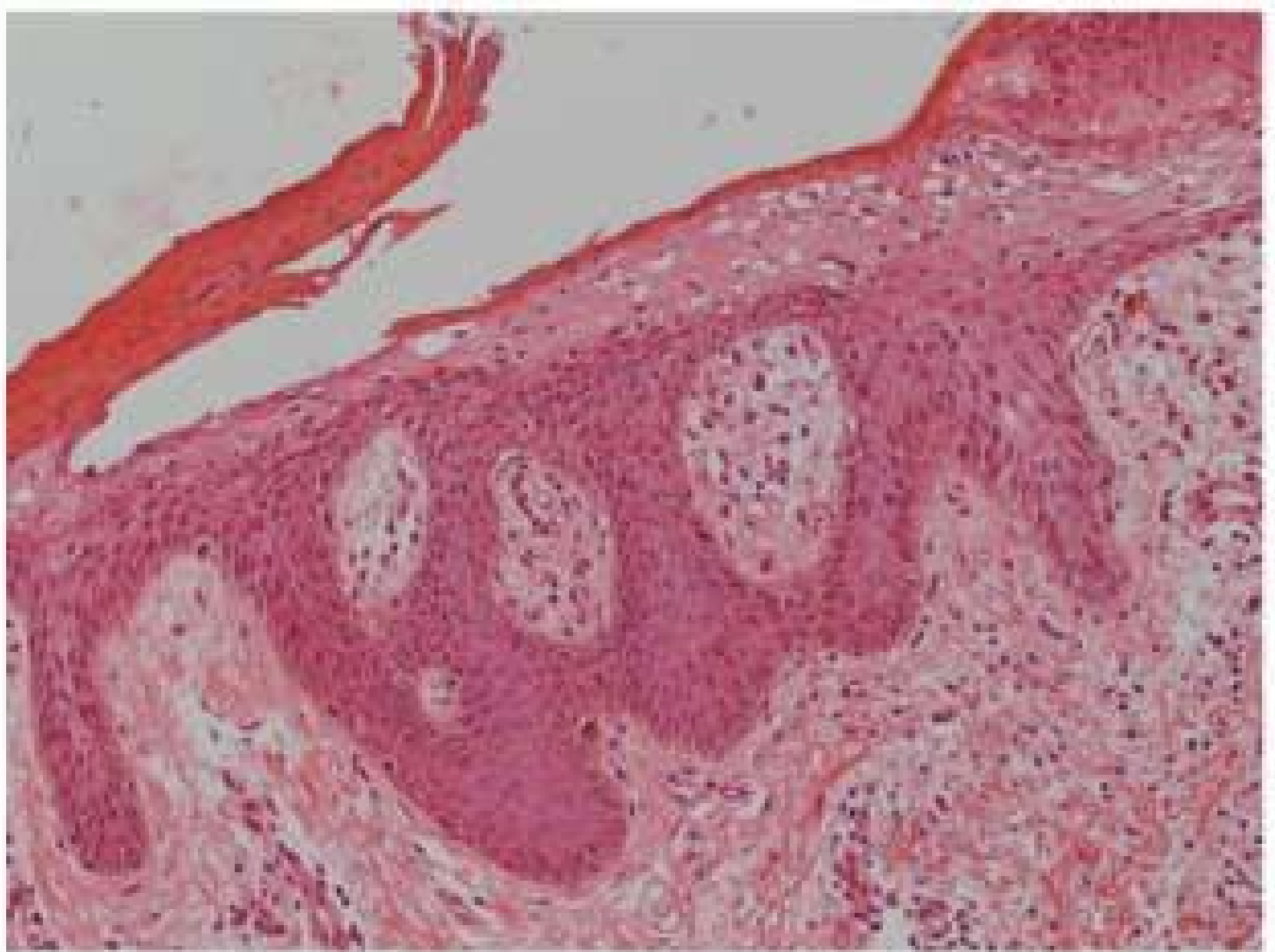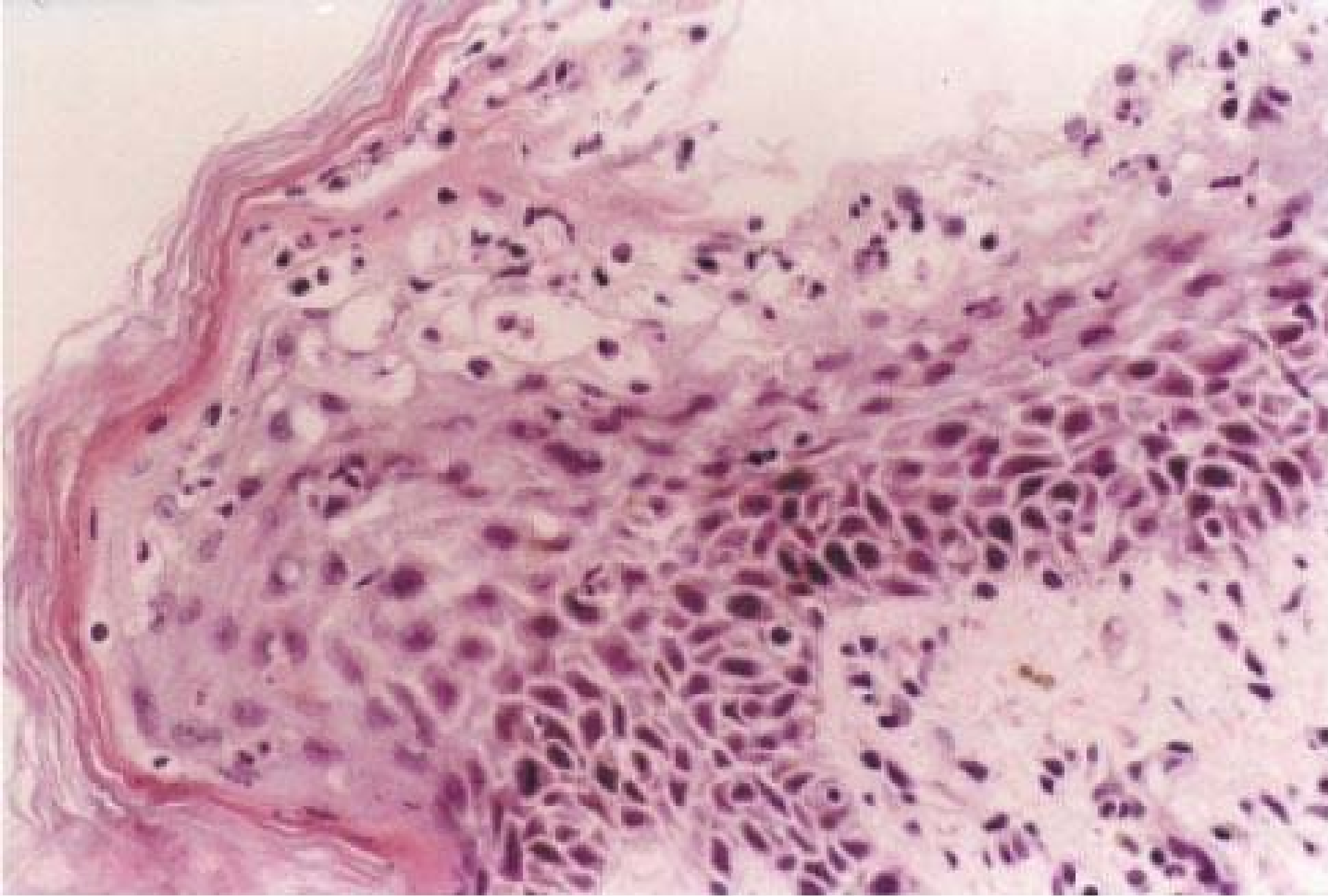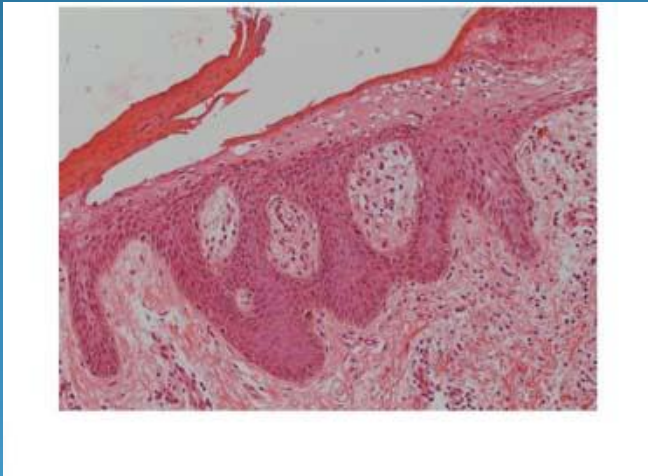


# Glucagonoma Syndrome (Necrolytic Migratory Erythema)

# Pearls



- Epidermal pallor with sharp demarcation with viable keratinocytes
- Scattered acute inflammatory cells and scale crust