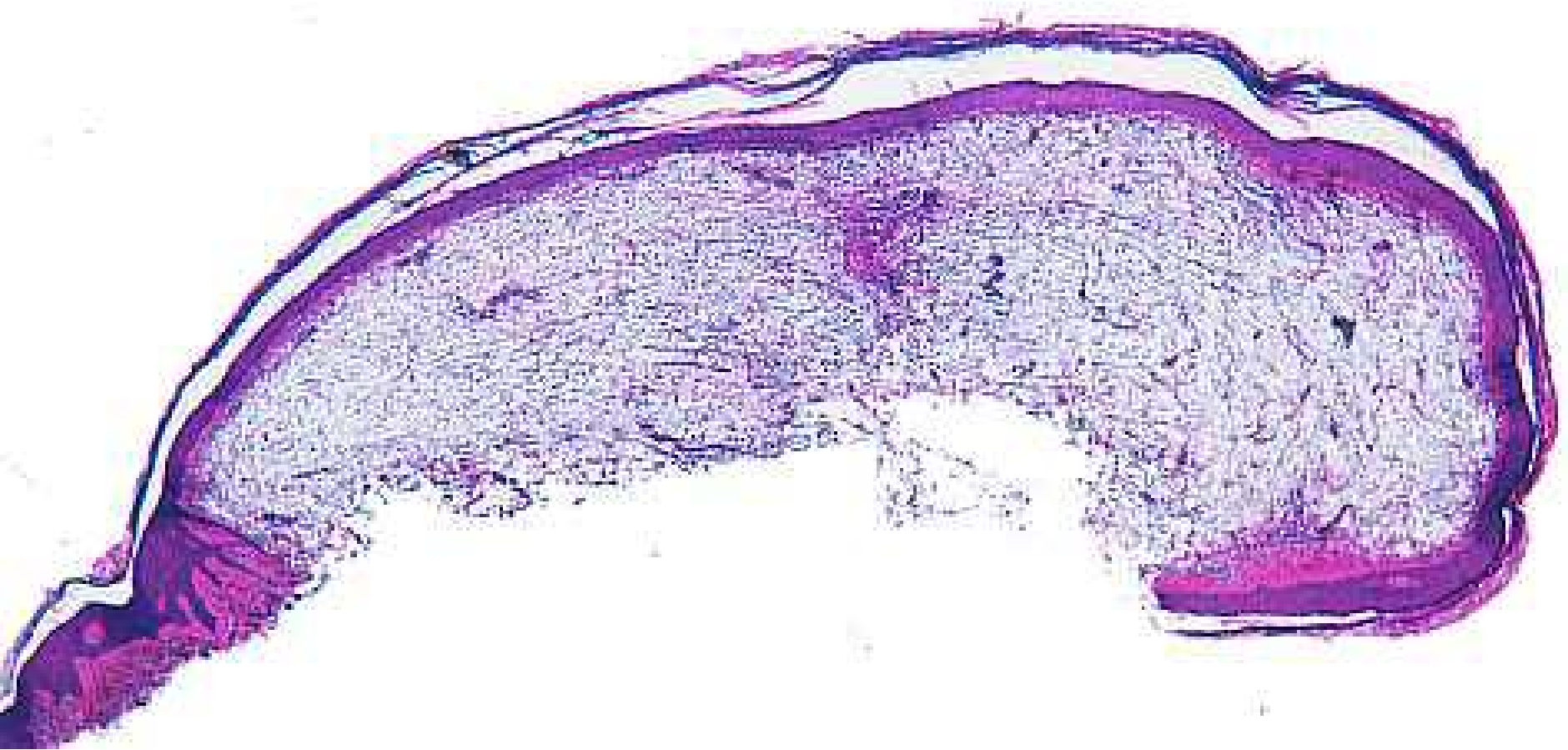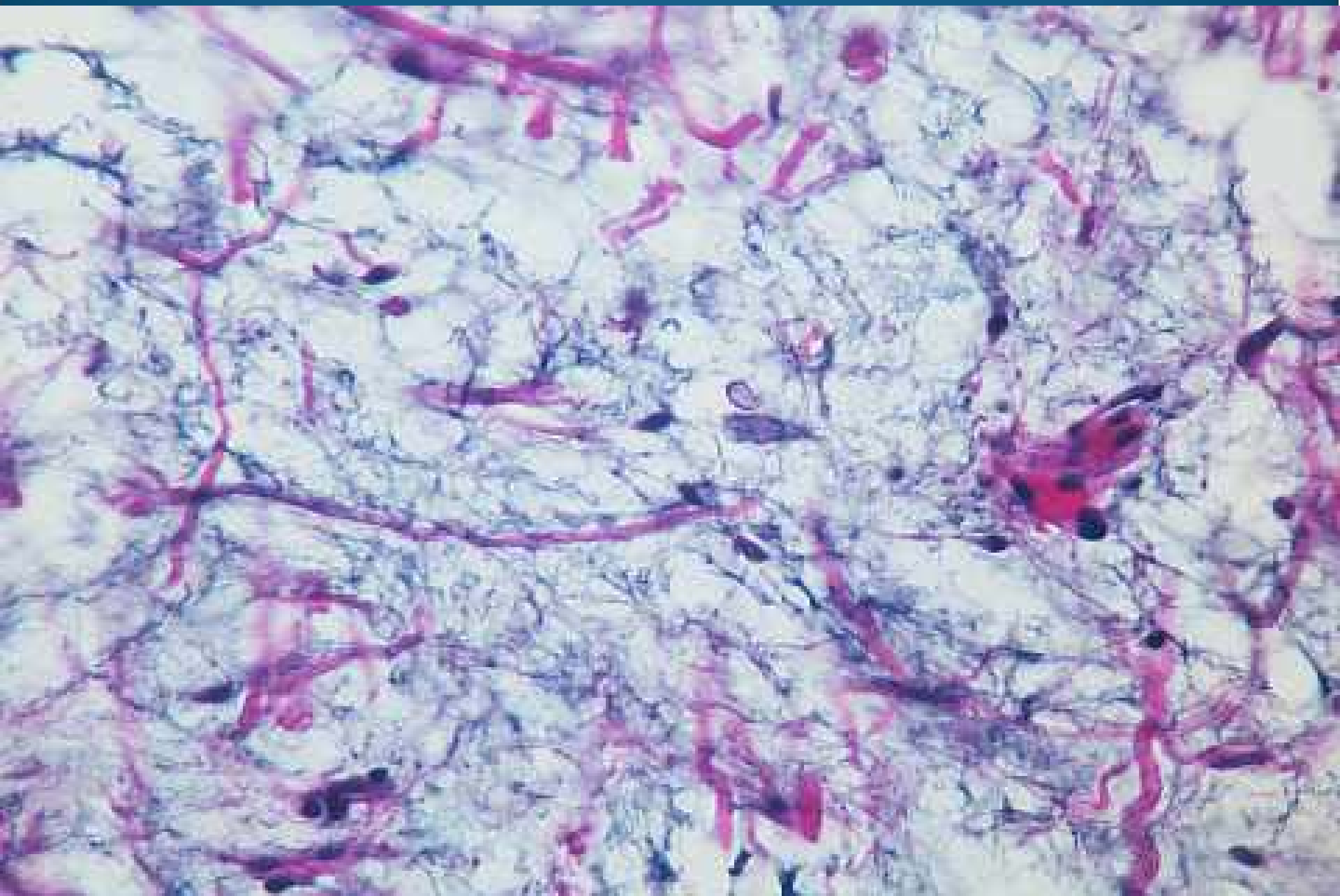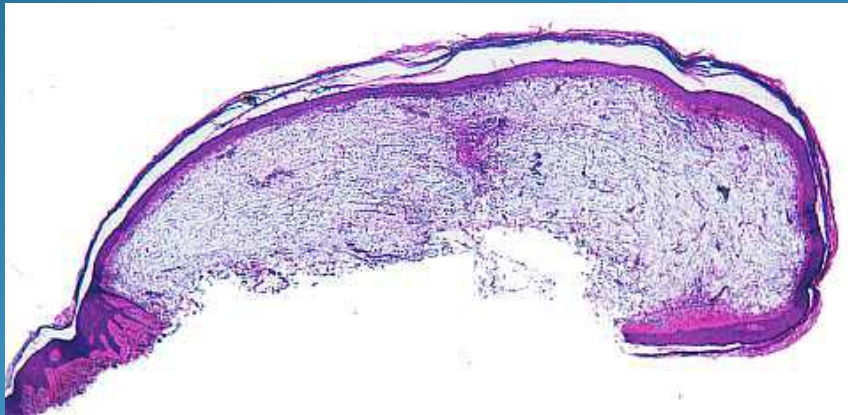


Focal Cutaneous Mucinosis

Pearls



- Paucicellular collection of mucin
- Minimal inflammatory cells or vascularity
- NO atypia of fibroblasts