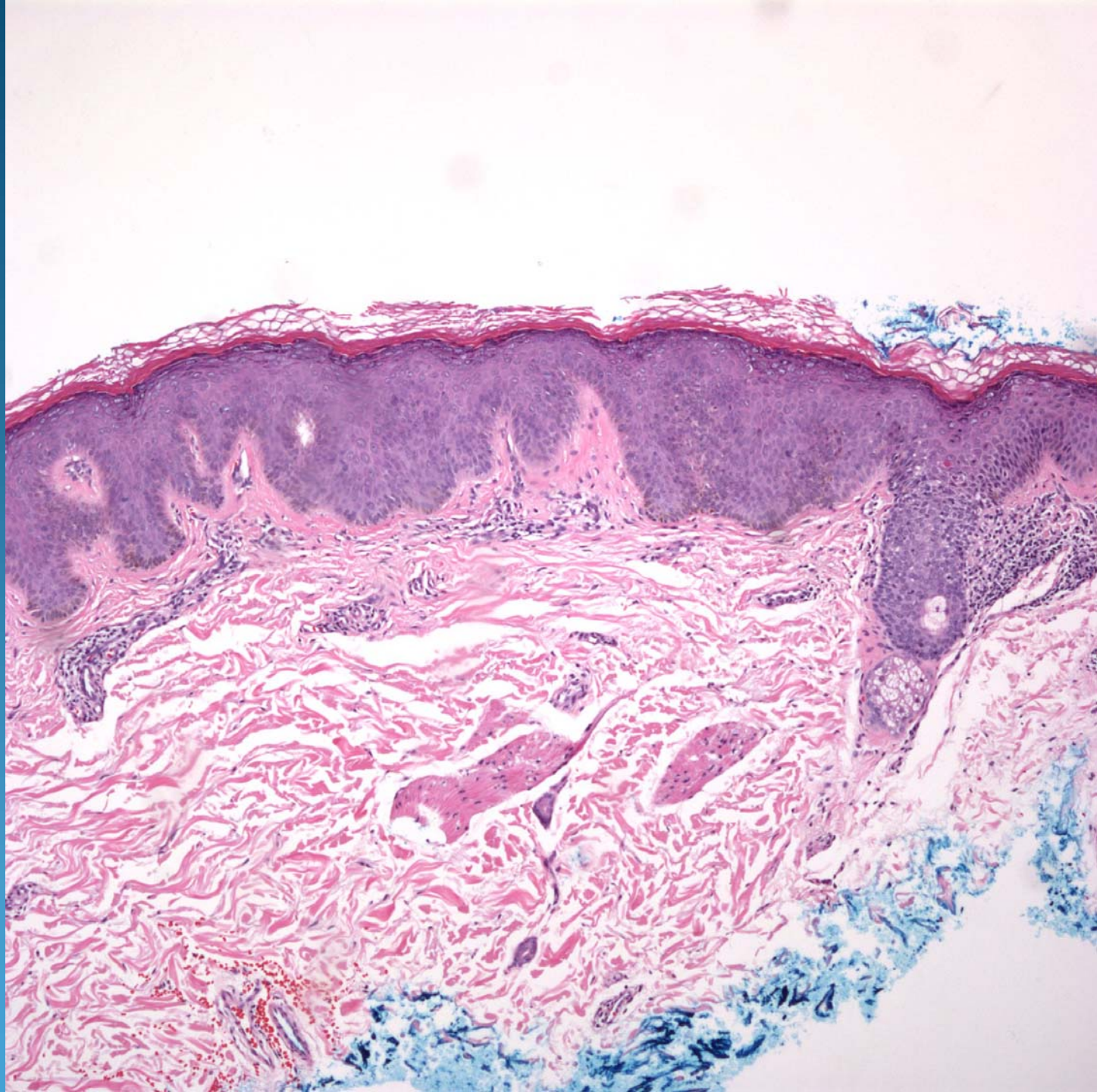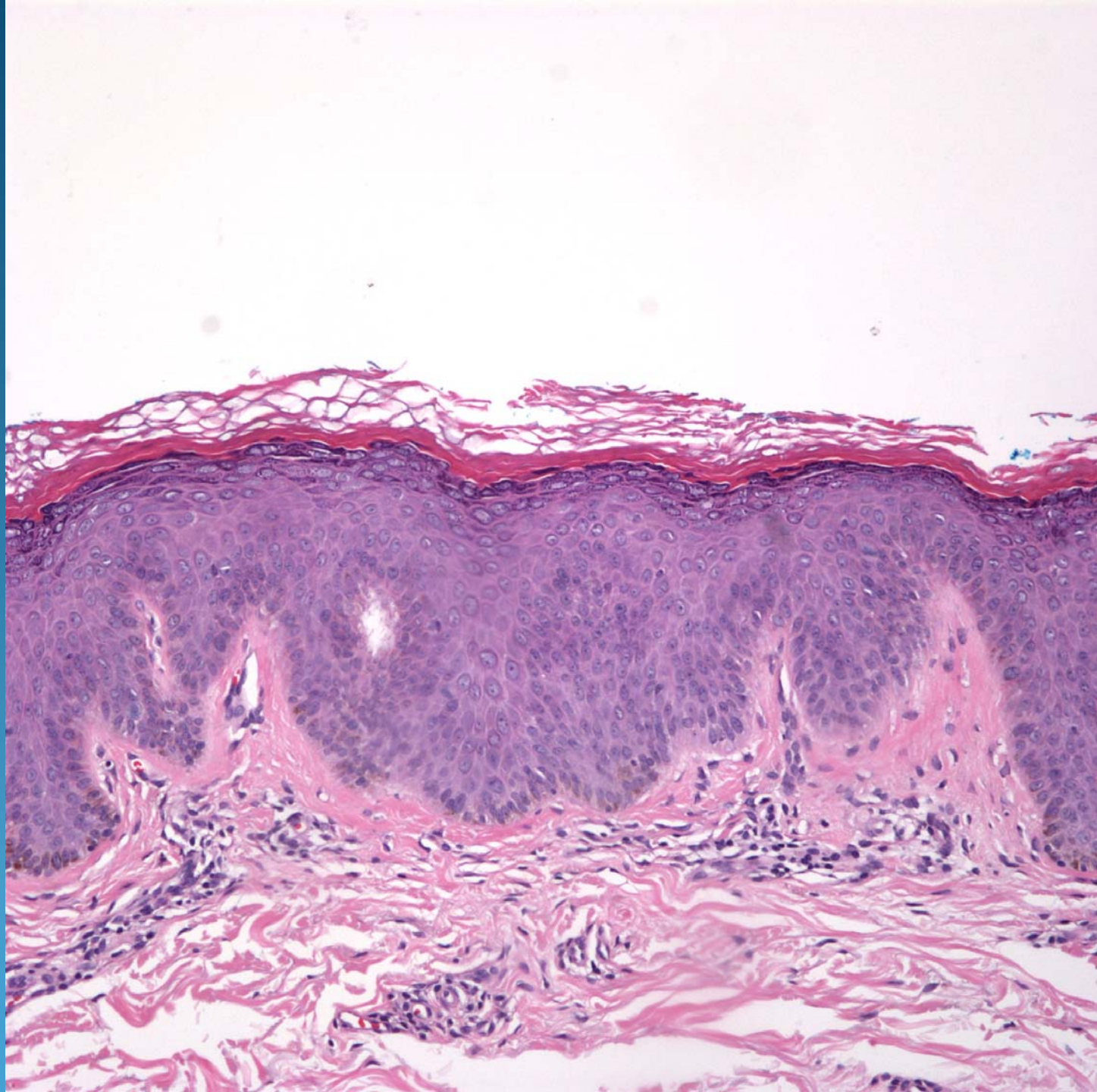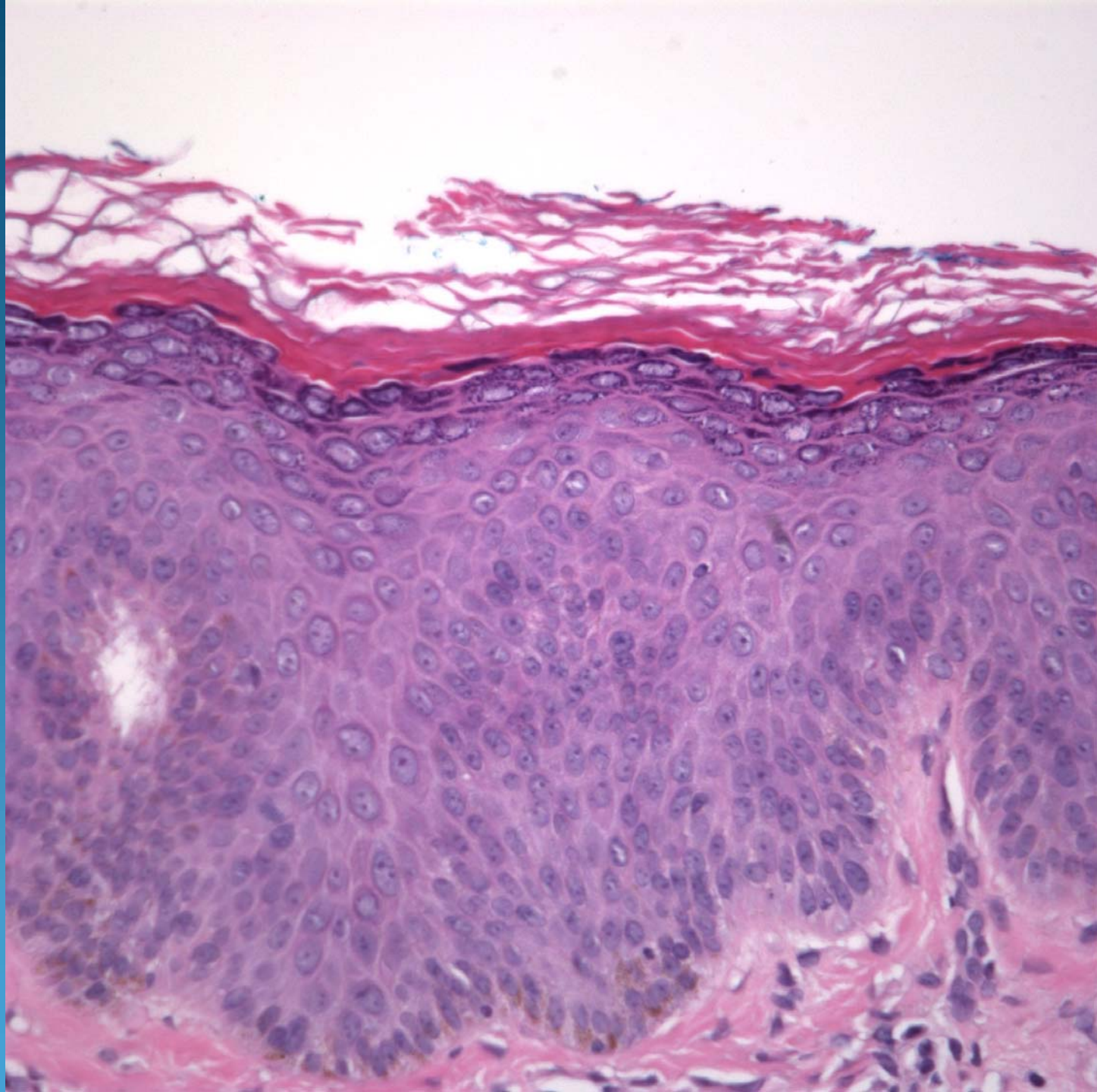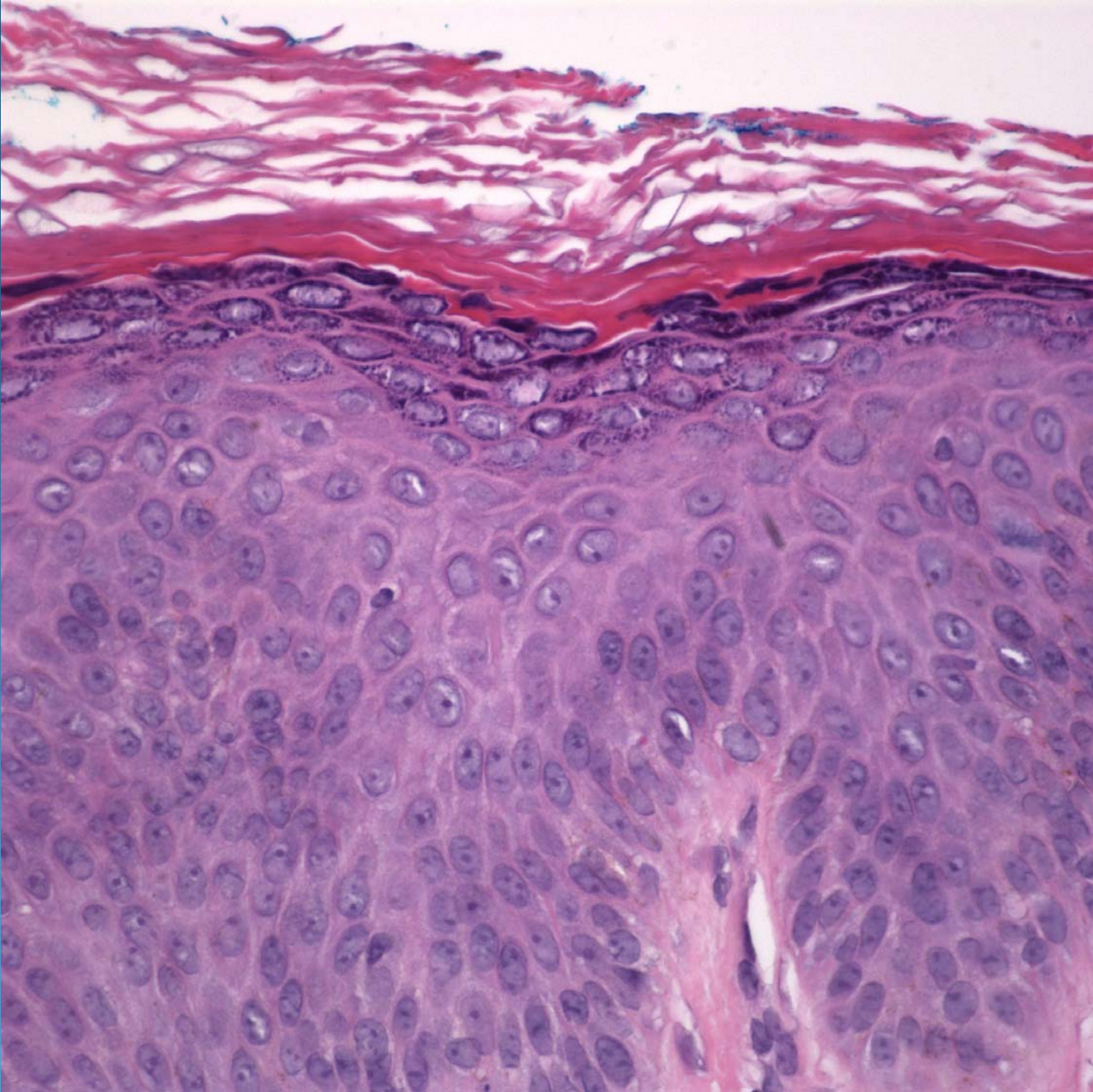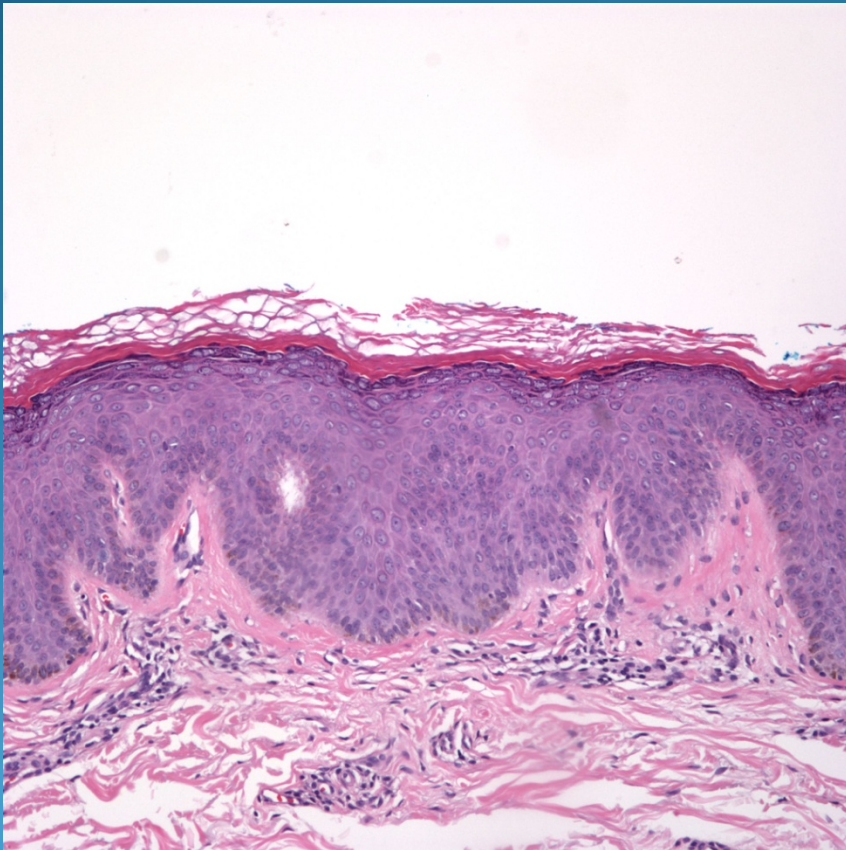


# Flat Wart (Verruca Plana)

# Pearls



- Gently mamillated silhouette with epidermal hyperplasia
- Hypergranular layer
- Koilocytosis