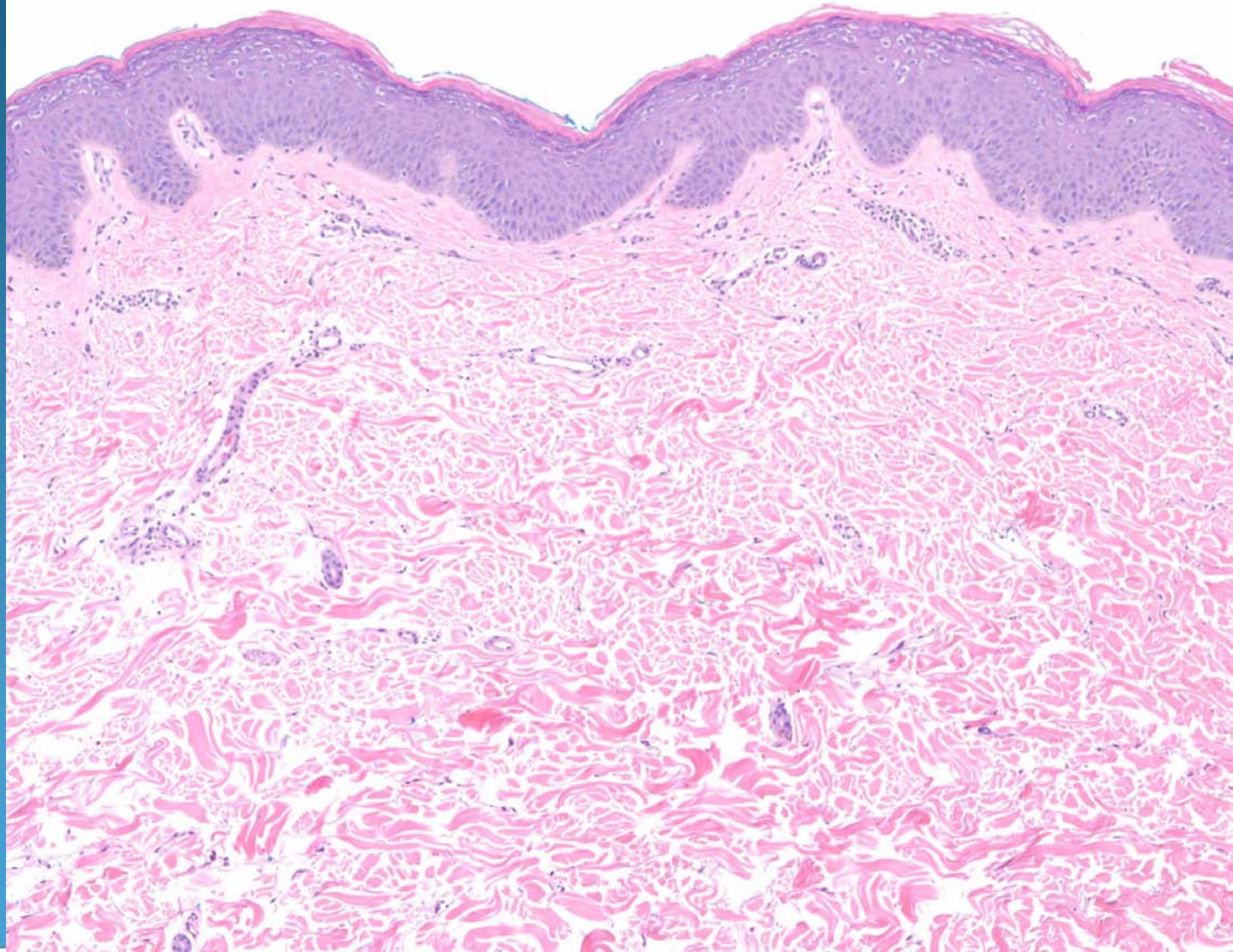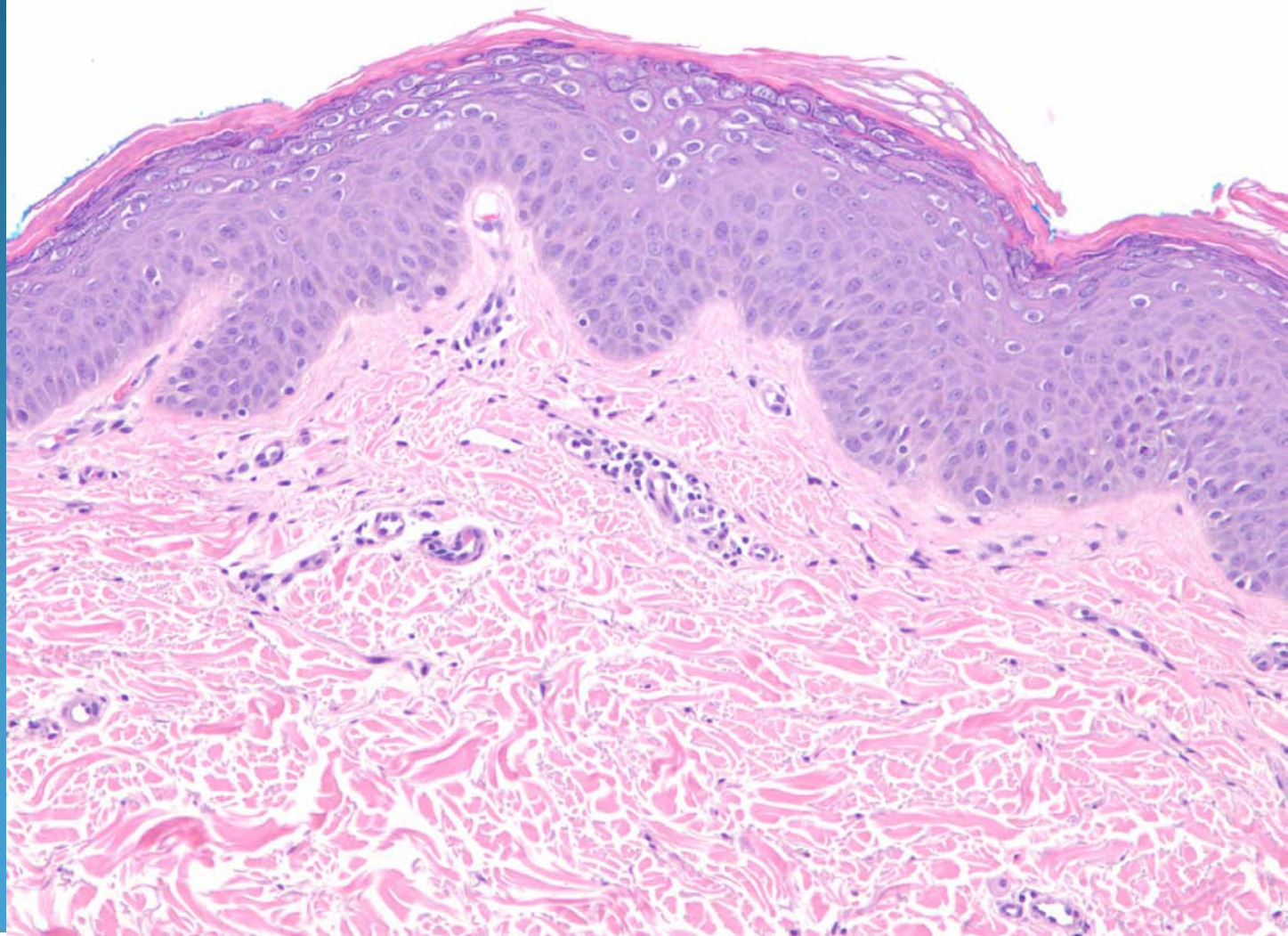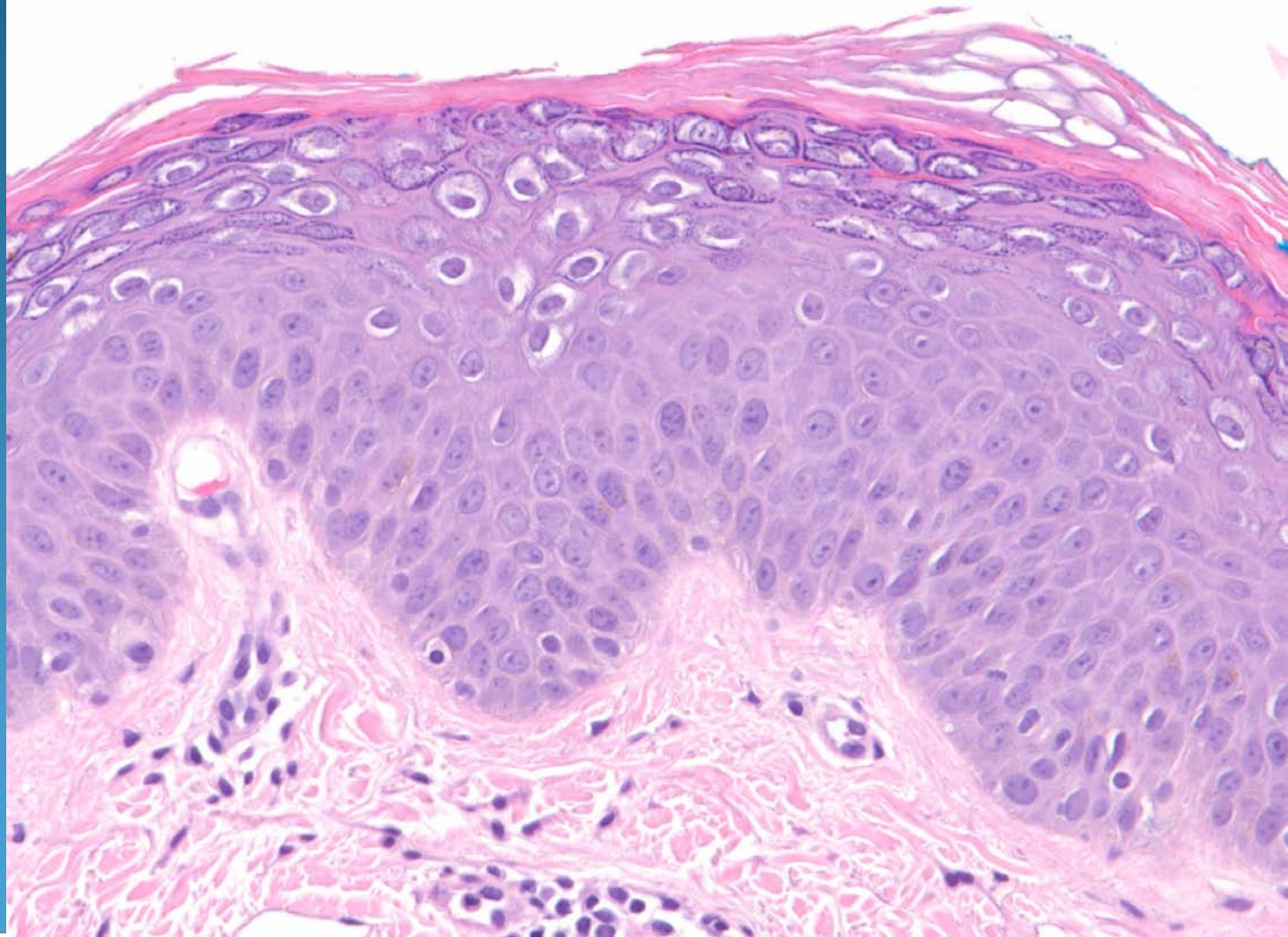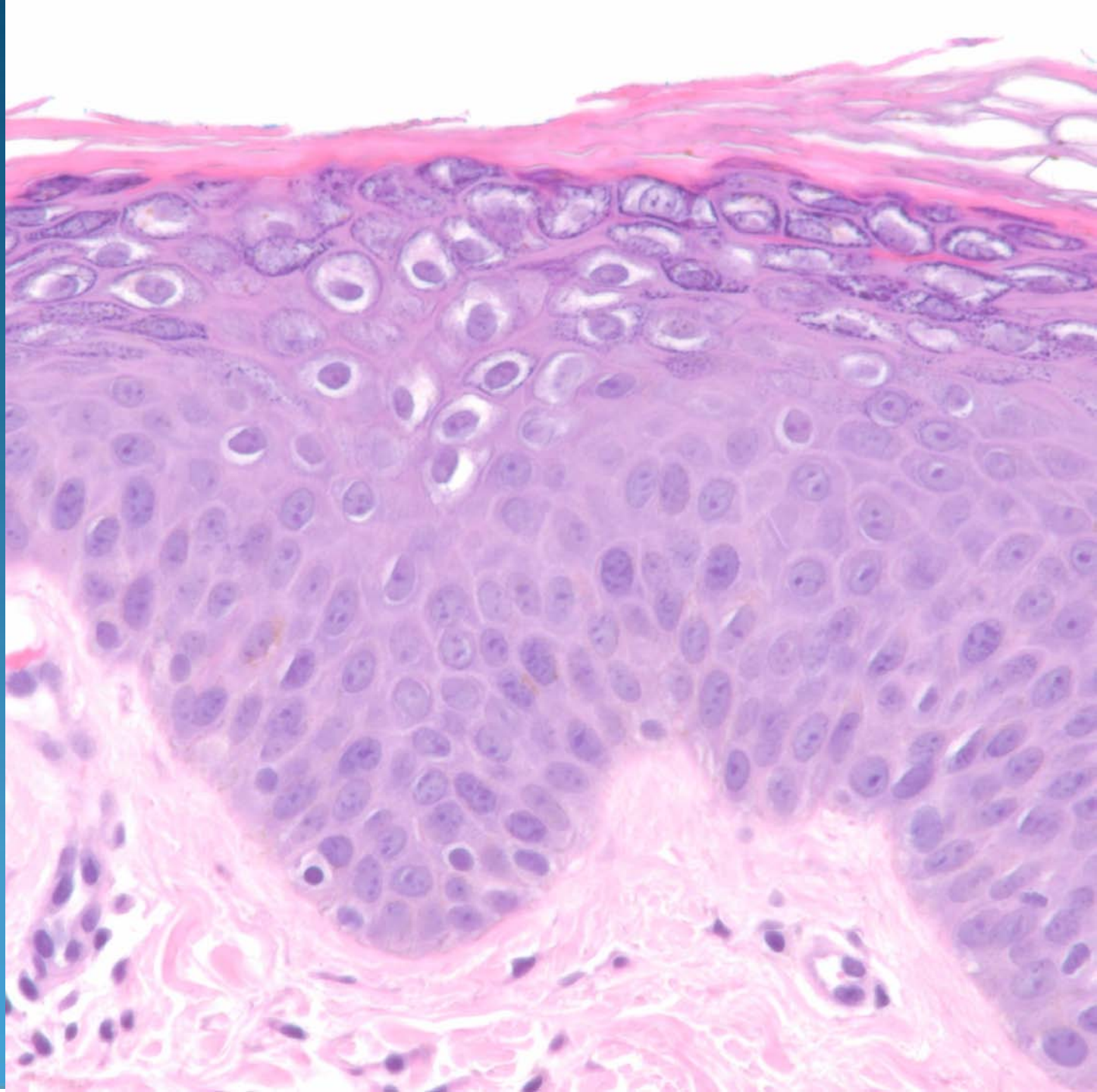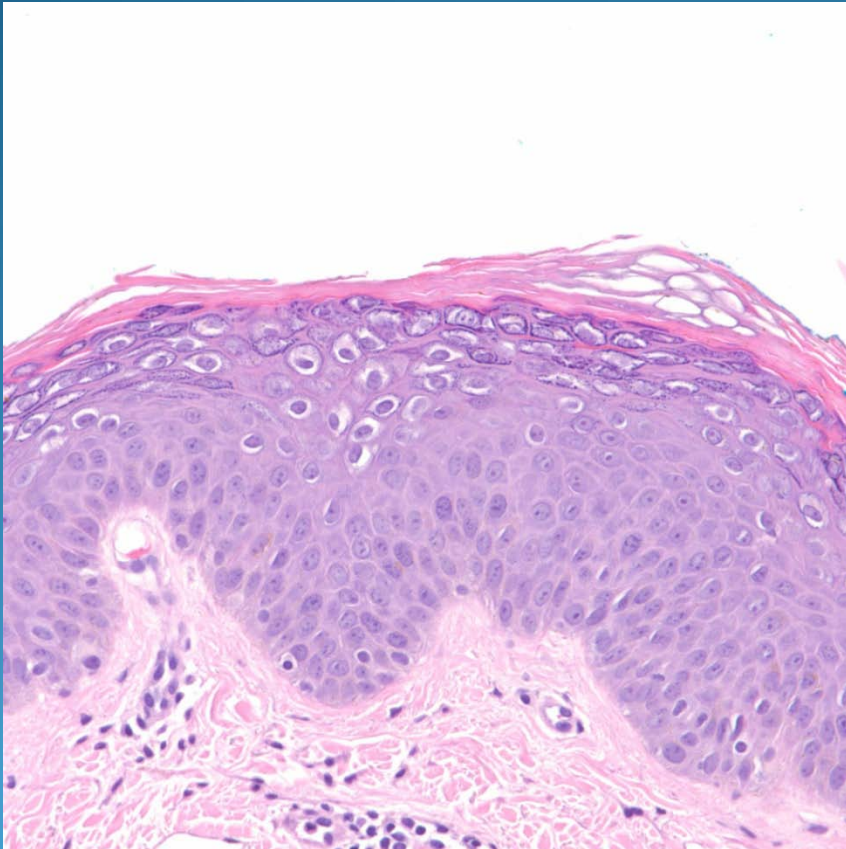


Verruca plana (Flat wart)

Pearls



- Slightly papillomatosis epidermal outline
- Superficial koilocytes
- Minimal parakeratosis
- Lacks inward bending of rete ridges of classic verruca vulgaris