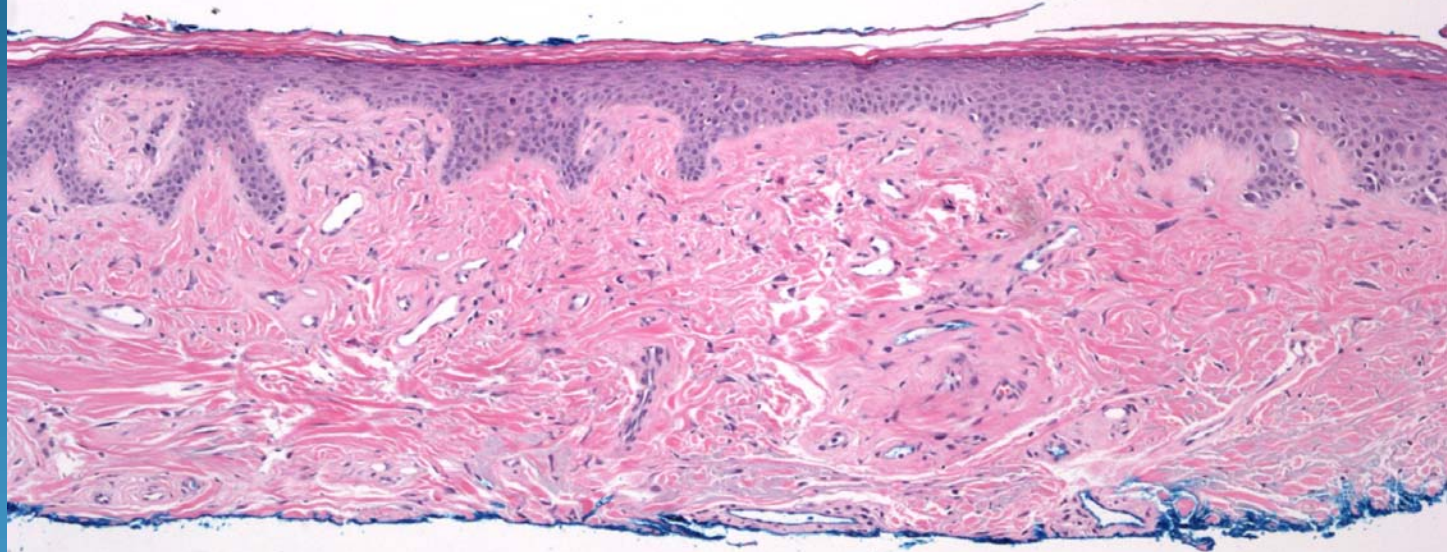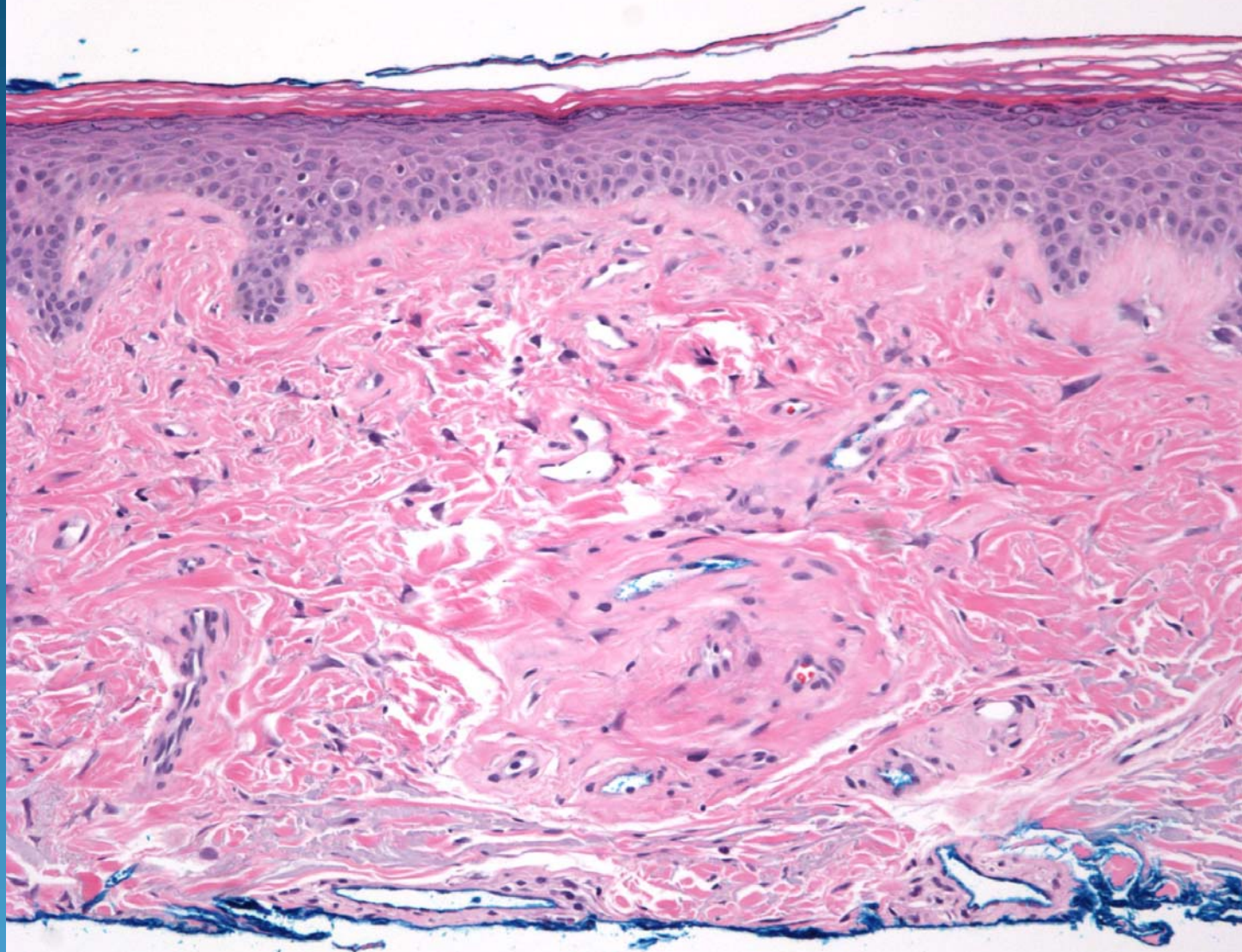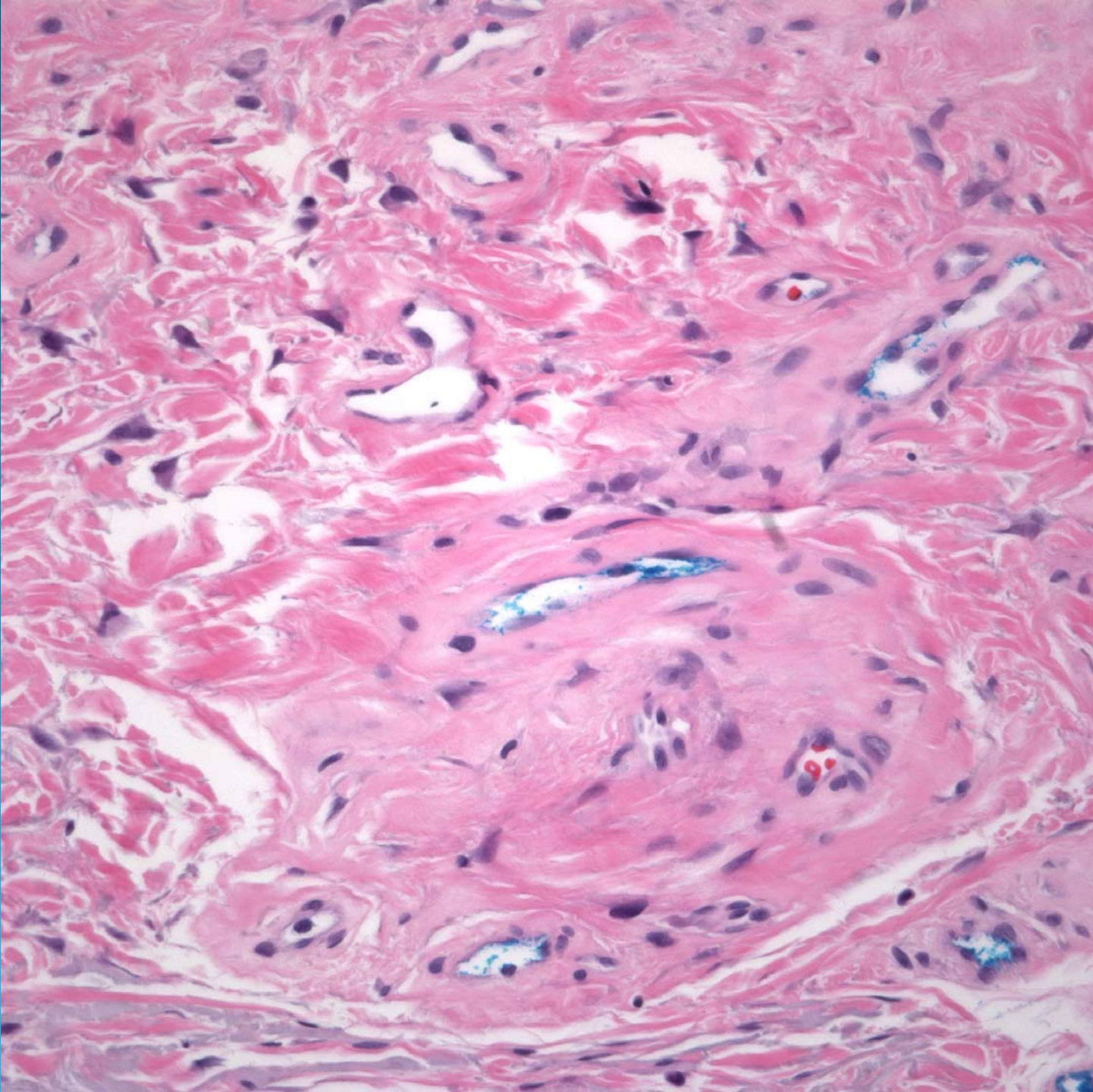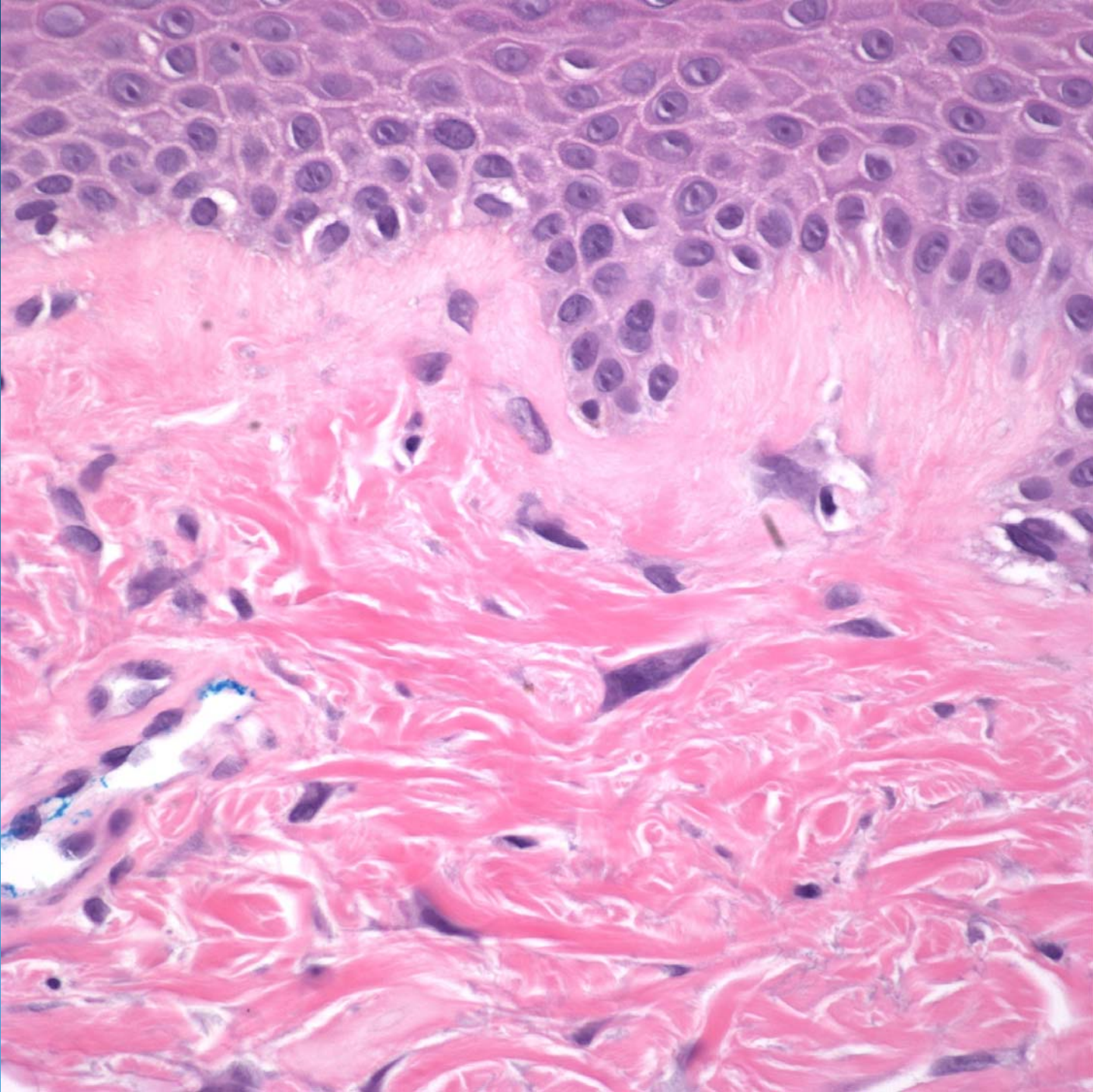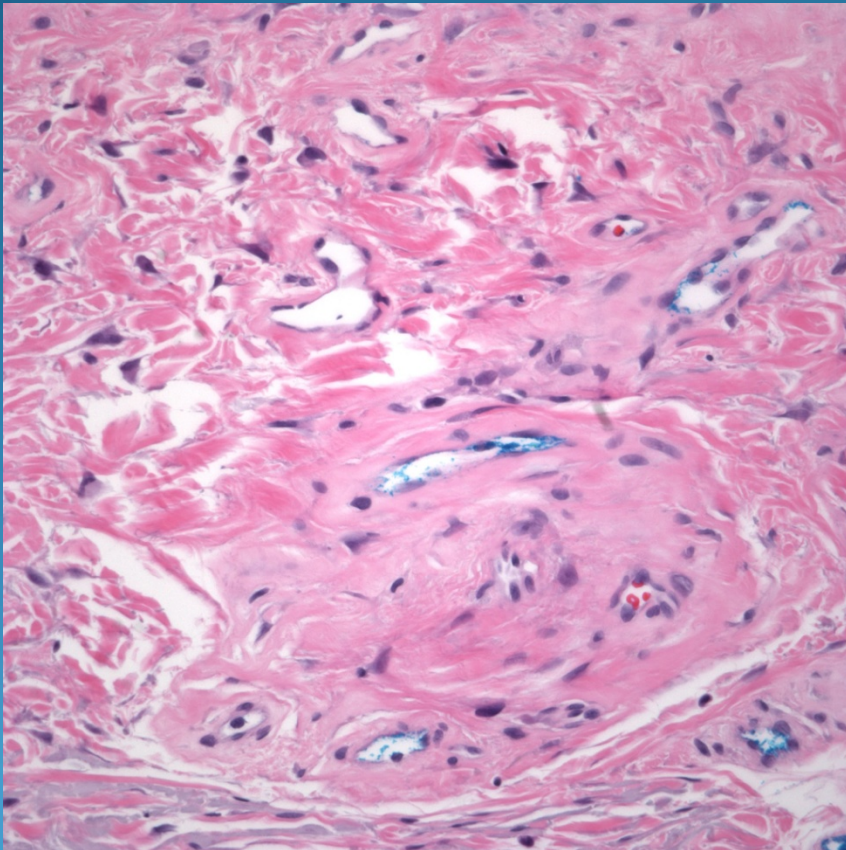


# Fibrous Papule (Angiofibroma)

# Pearls



- Bland stellate fibroblasts in a fibrotic stroma
- Variable mixture of thin walled capillary sized vessels
- FXIIIa positive for dermal dendrocytes
- Beware of atypical junctional melanocytes