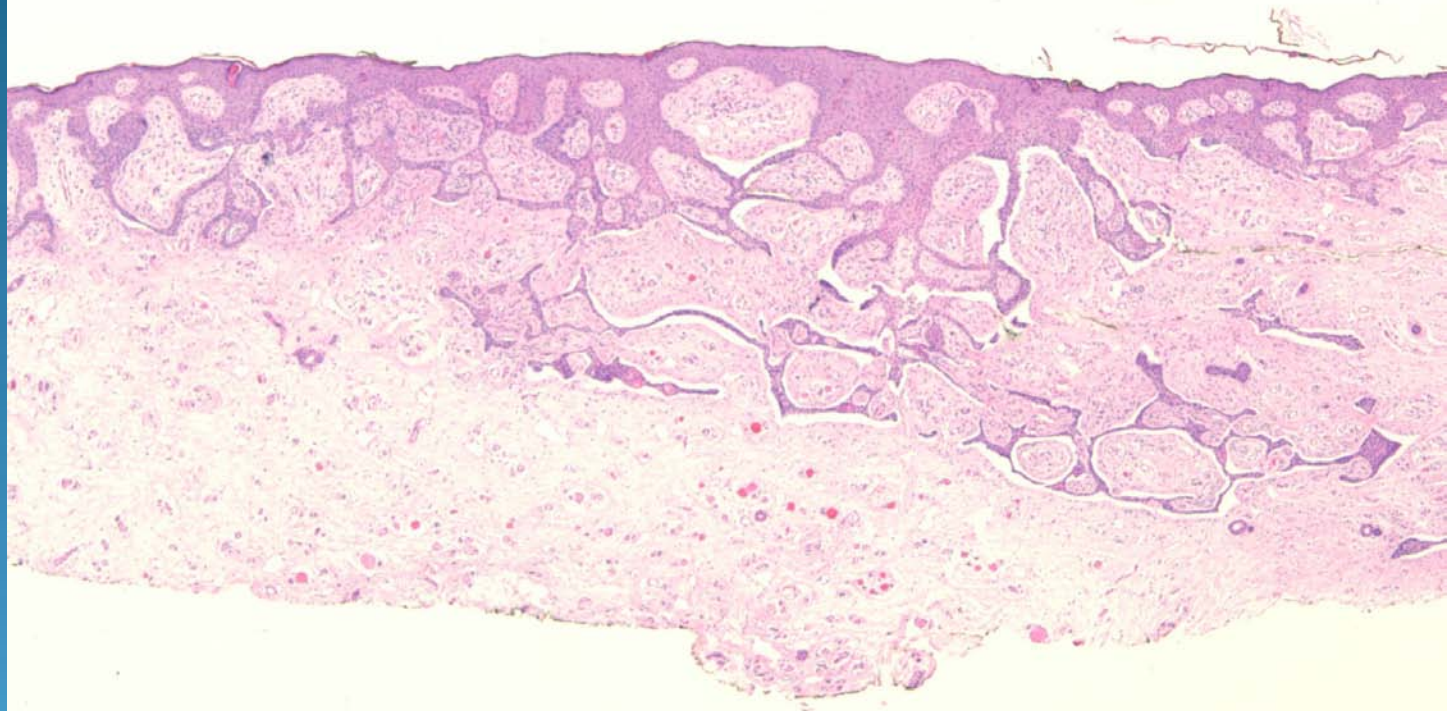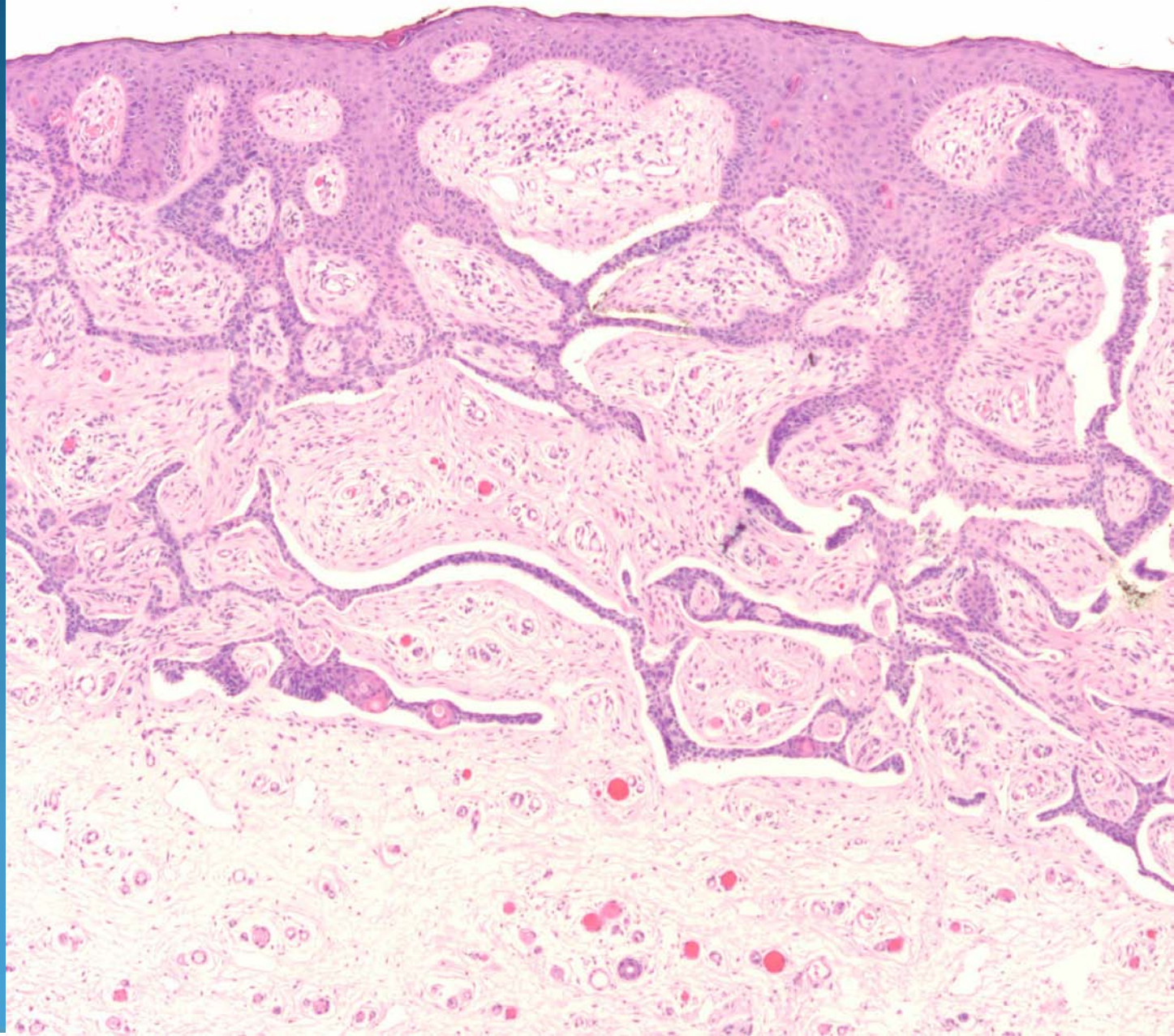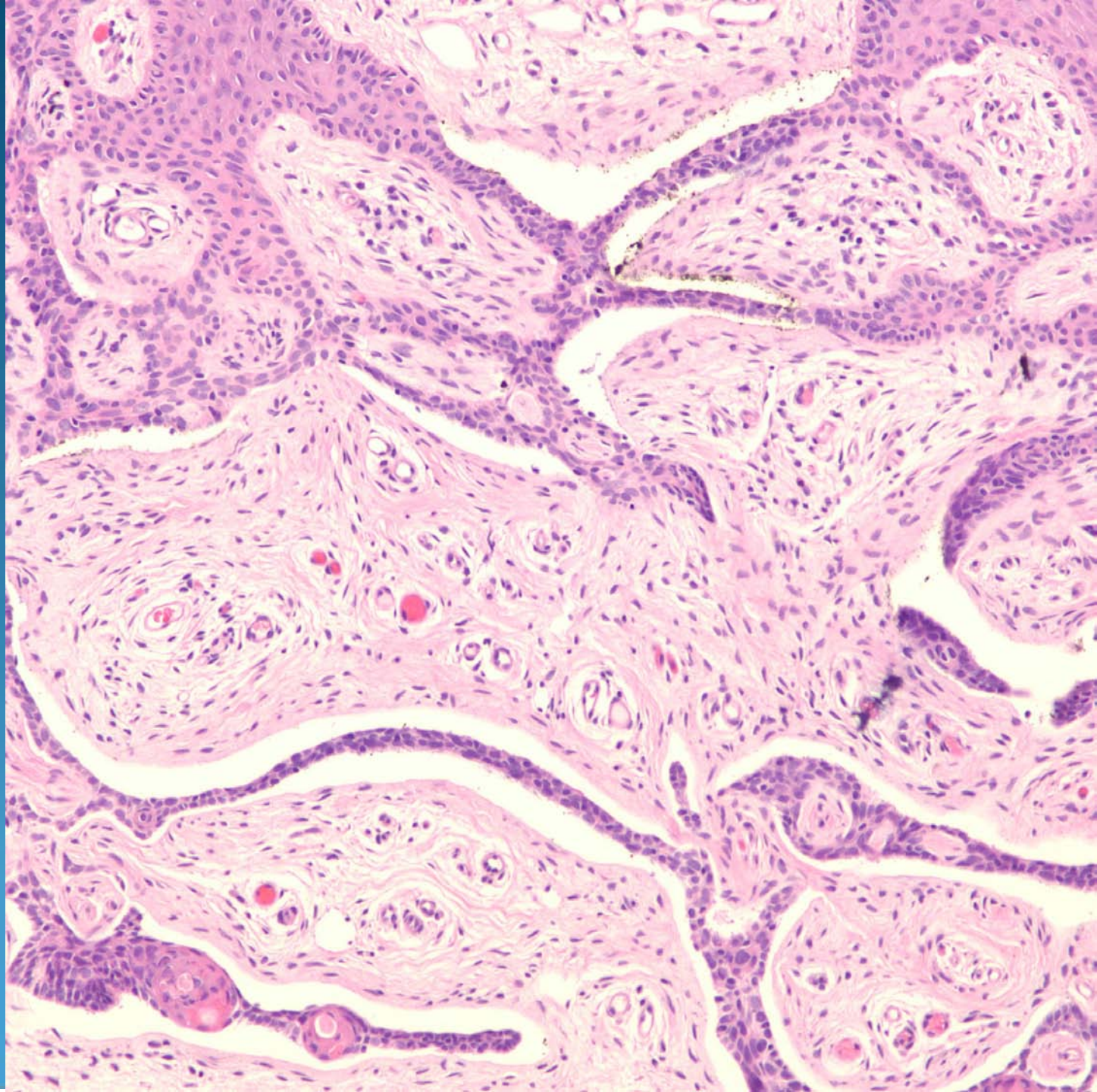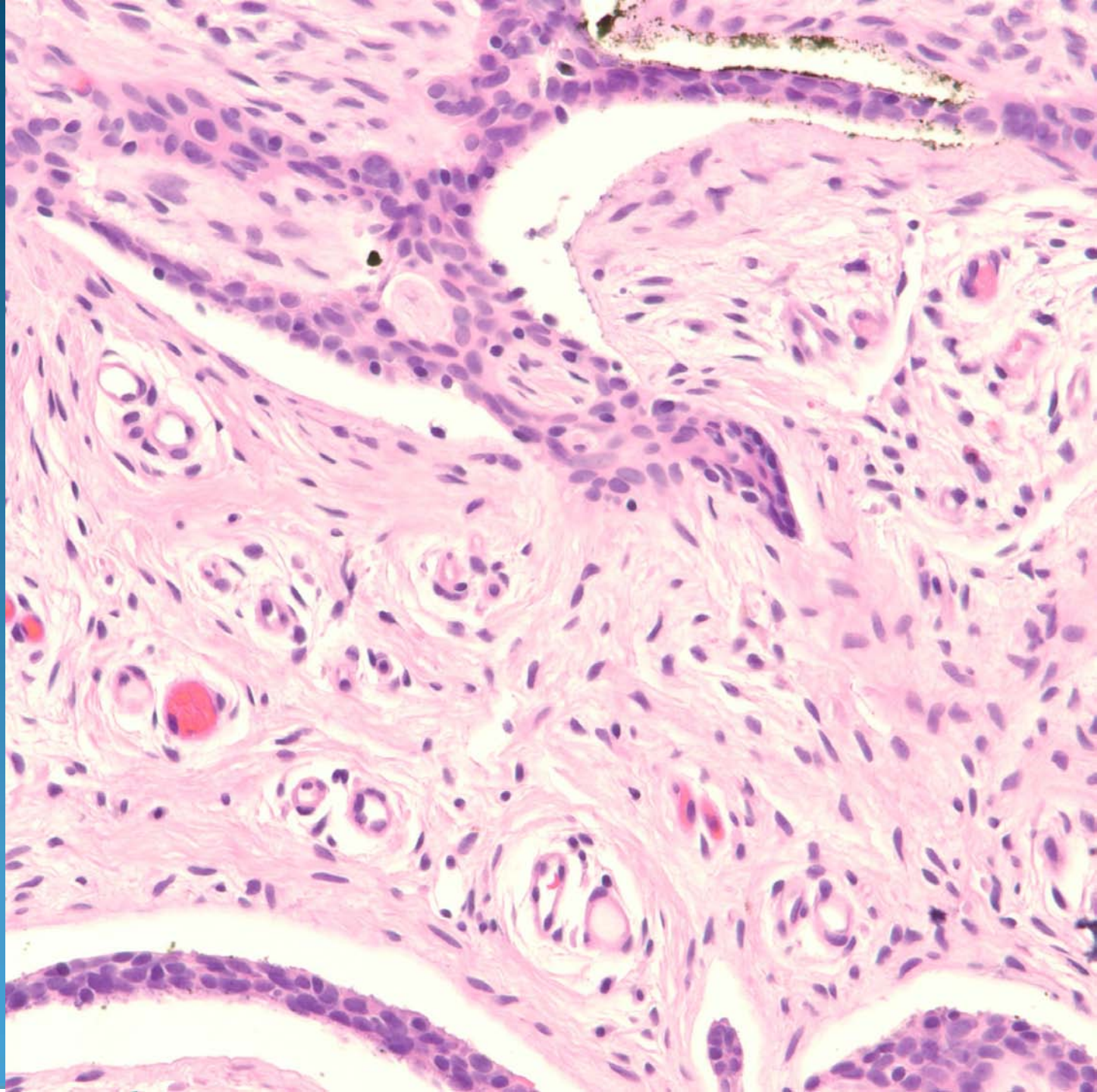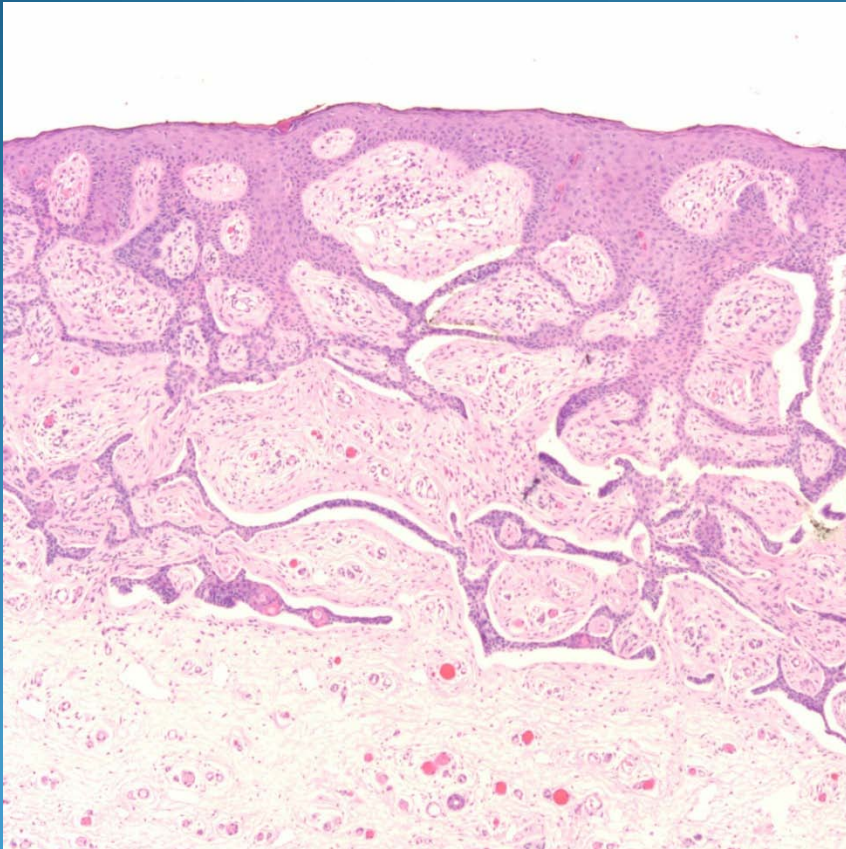


Fibroepithelioma of Pinkus

Pearls



- Thin anastomosing strands of basaloid cells creating a fenestrated appearance
- Look for stromal-tumor clefting and myxoid stroma