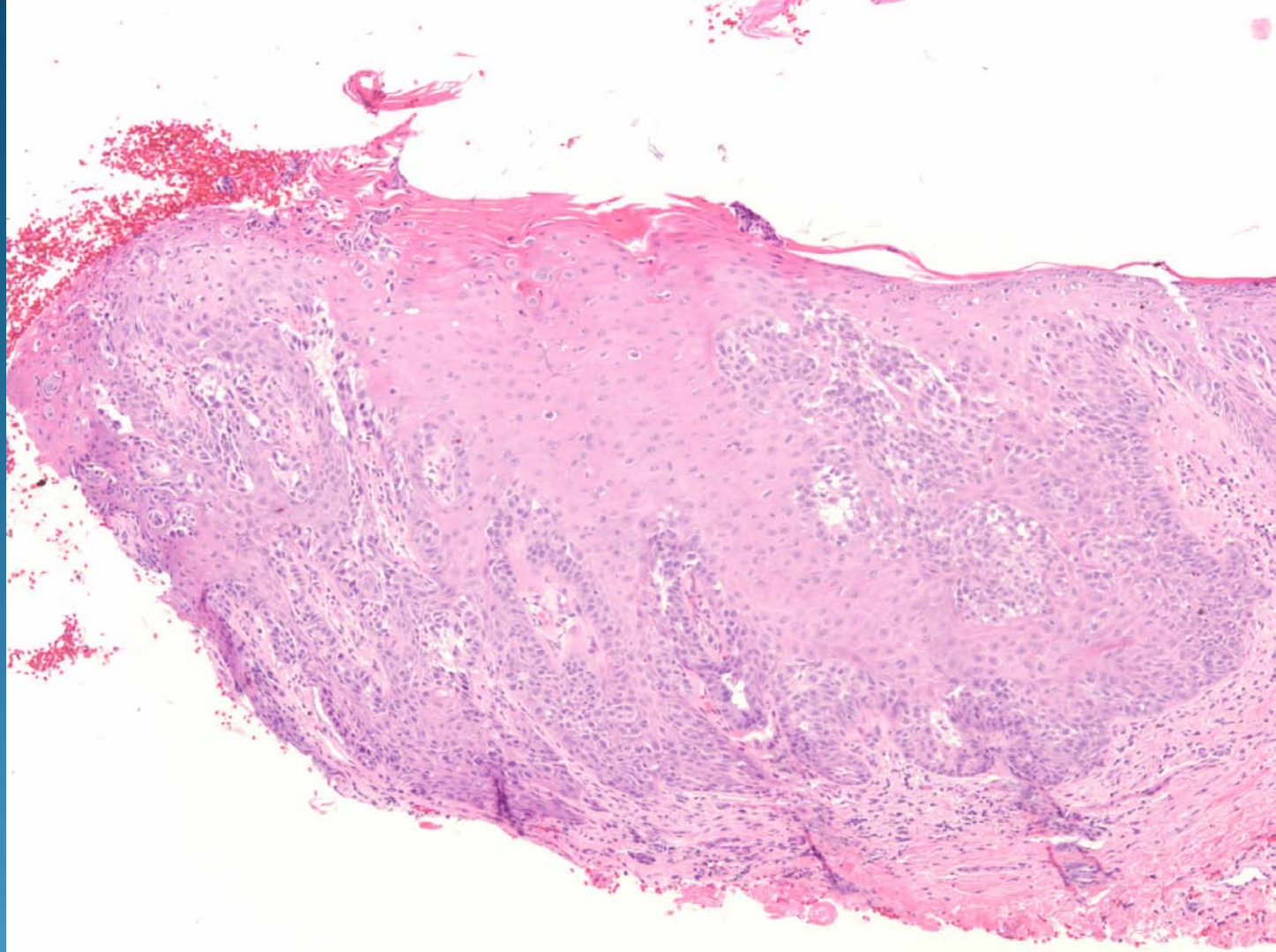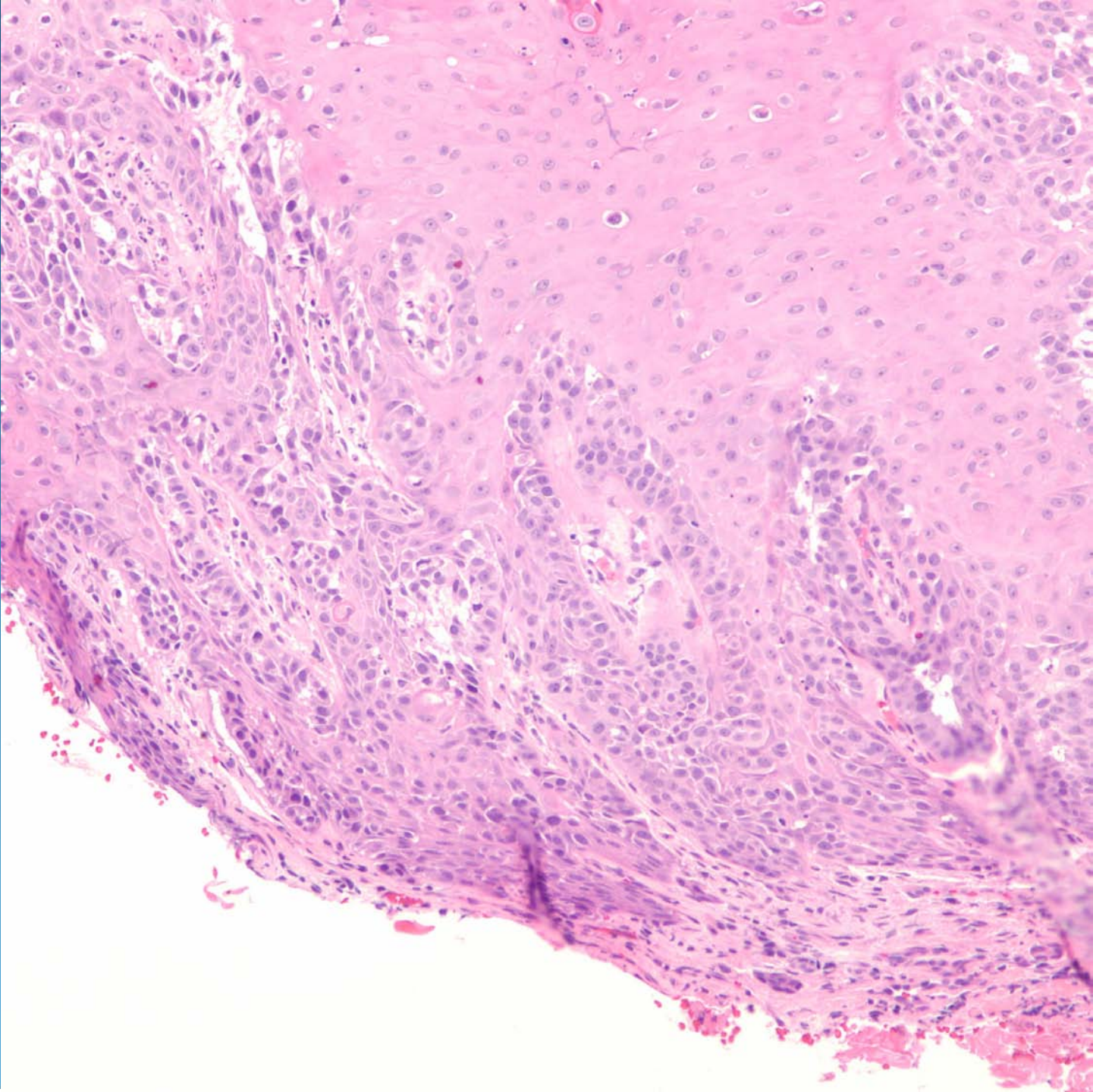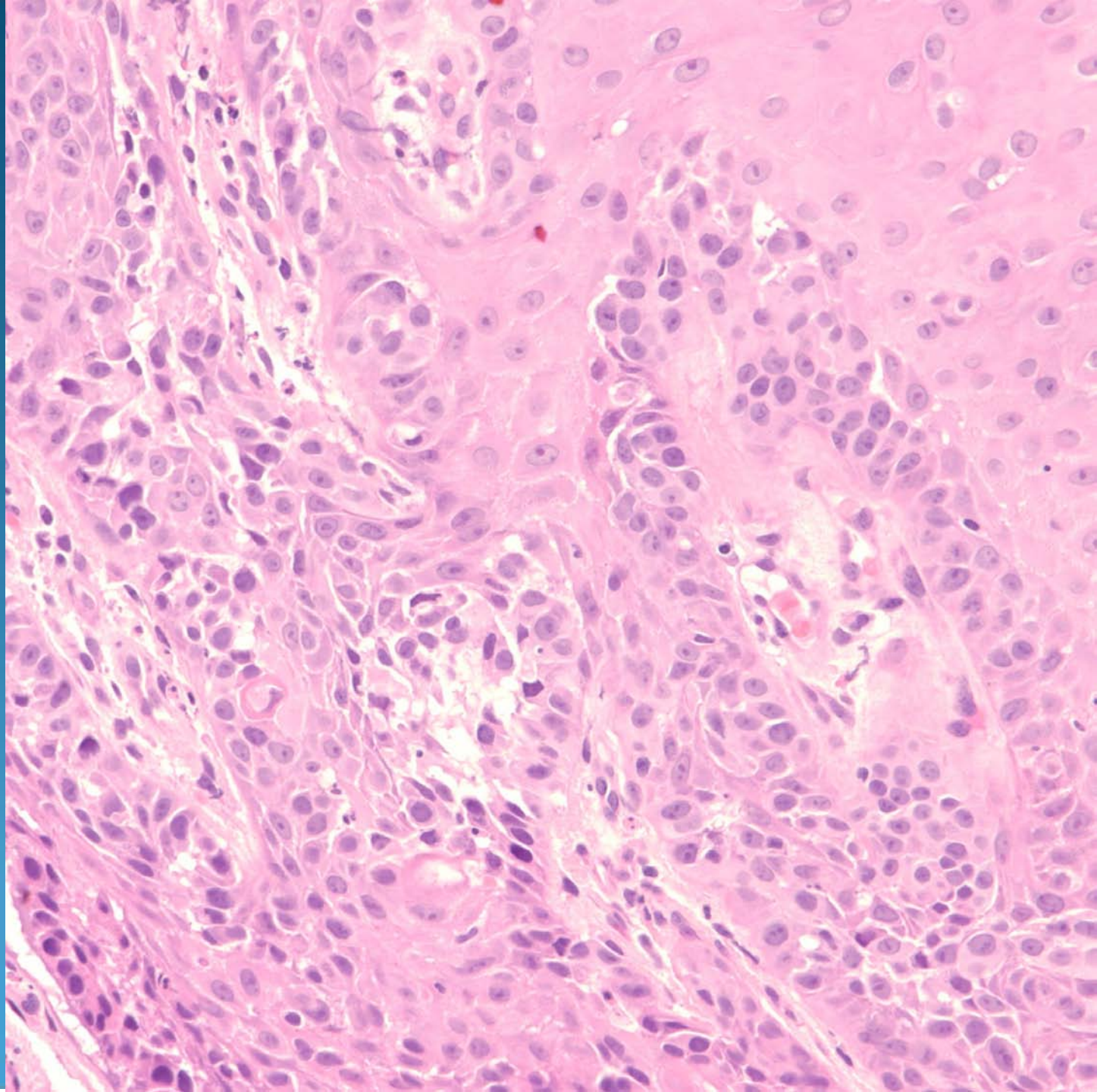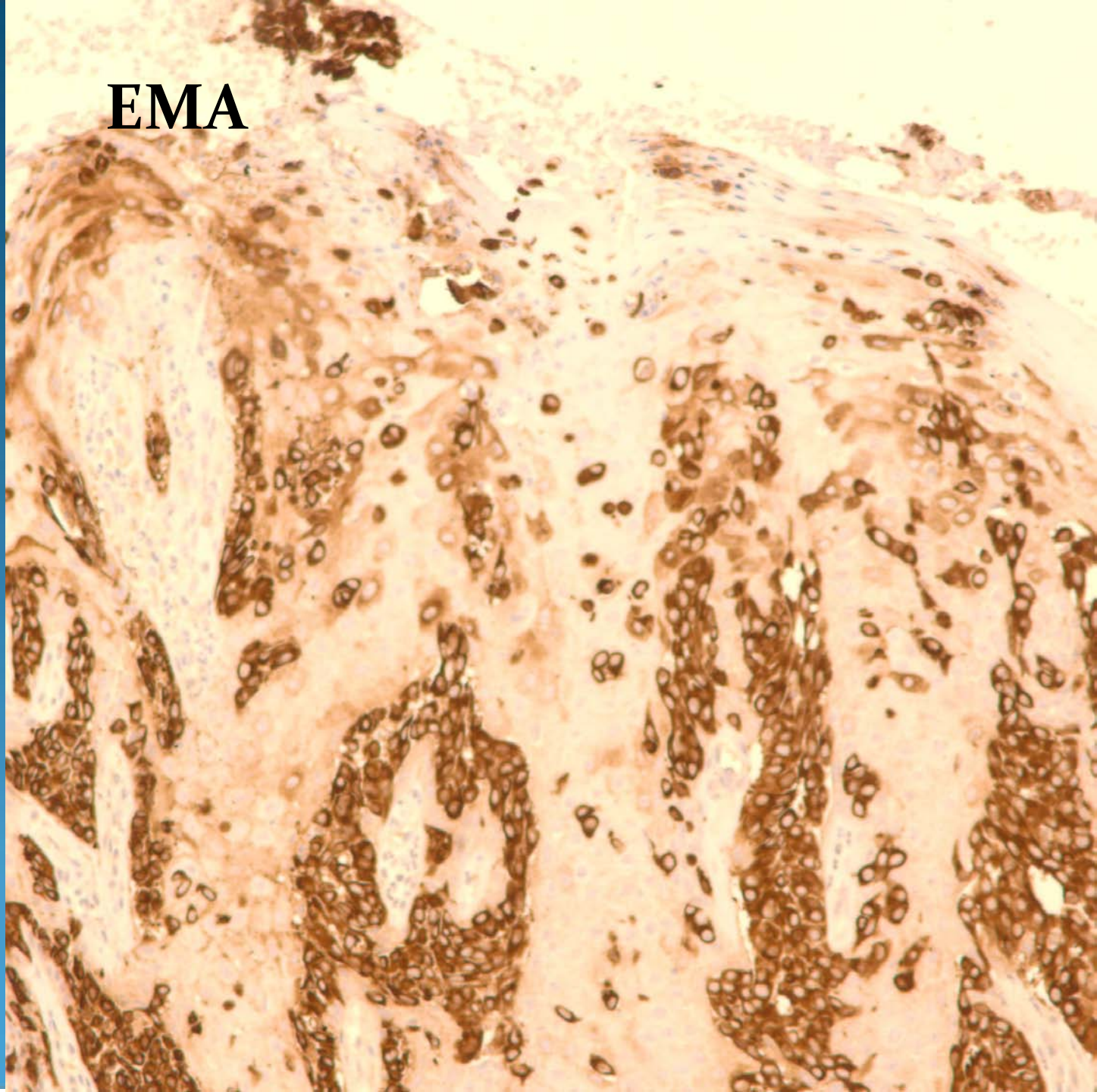
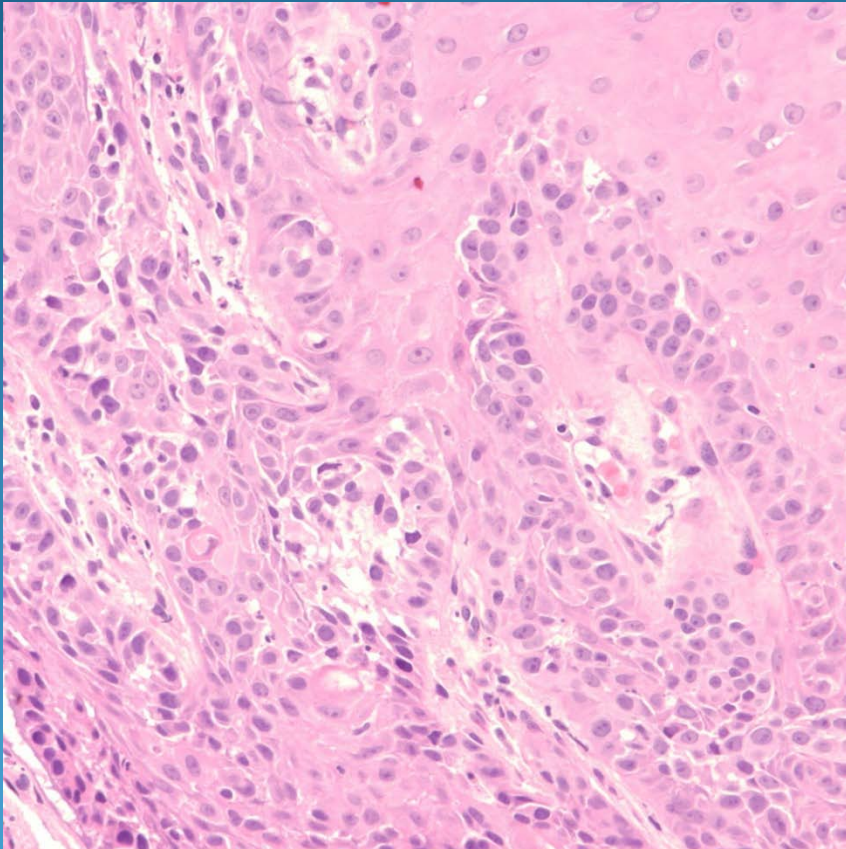


EMA



Extra-mammary Paget's Disease

Pearls



- Low power appearance of “buck-shot” pattern of large atypical epithelial cells
- Rarely glandular lumina
- Must exclude metastatic adenocarcinoma, melanoma, and Bowen’s disease
- Classic IHC positive for: CK7 and EMA