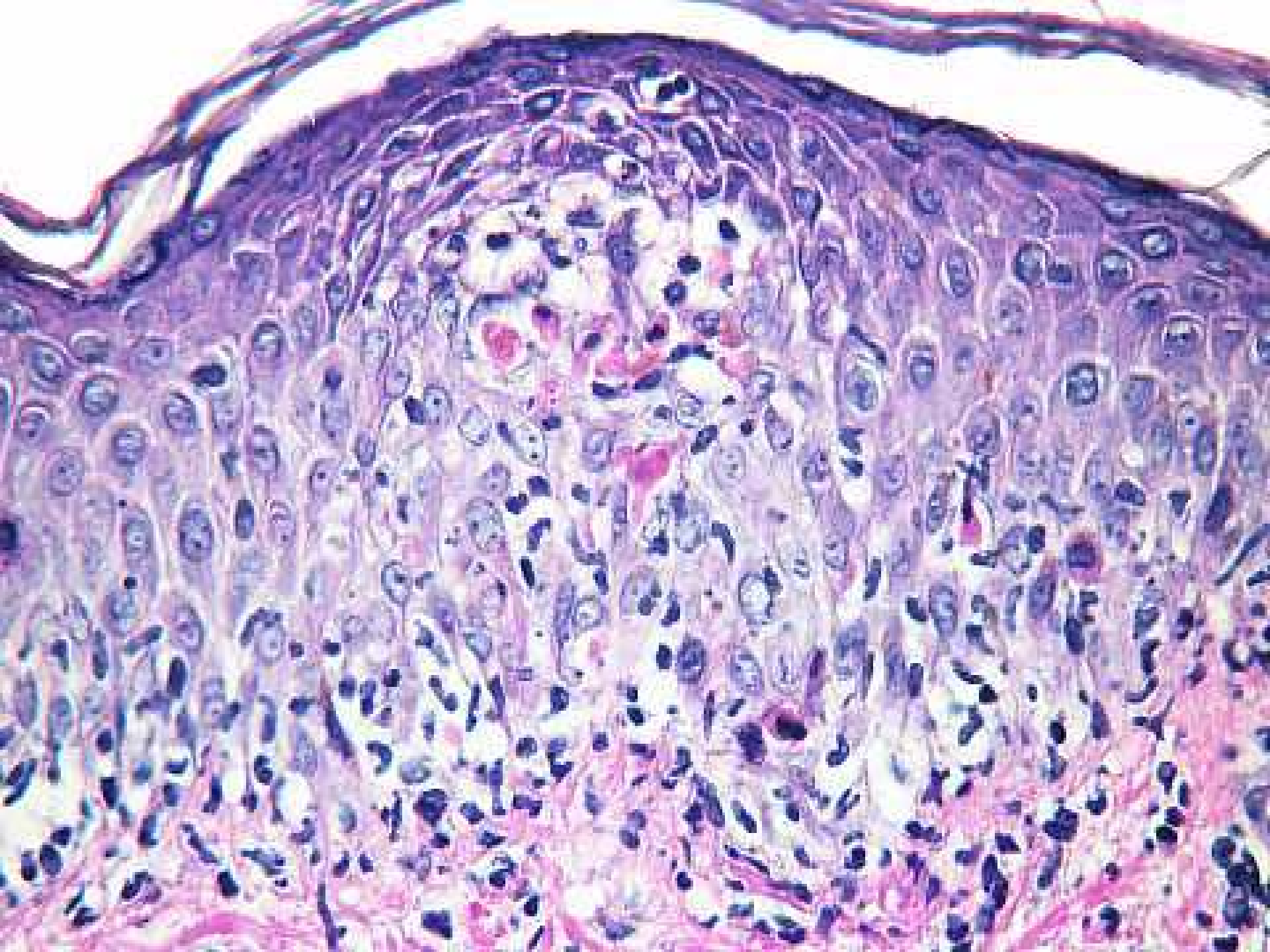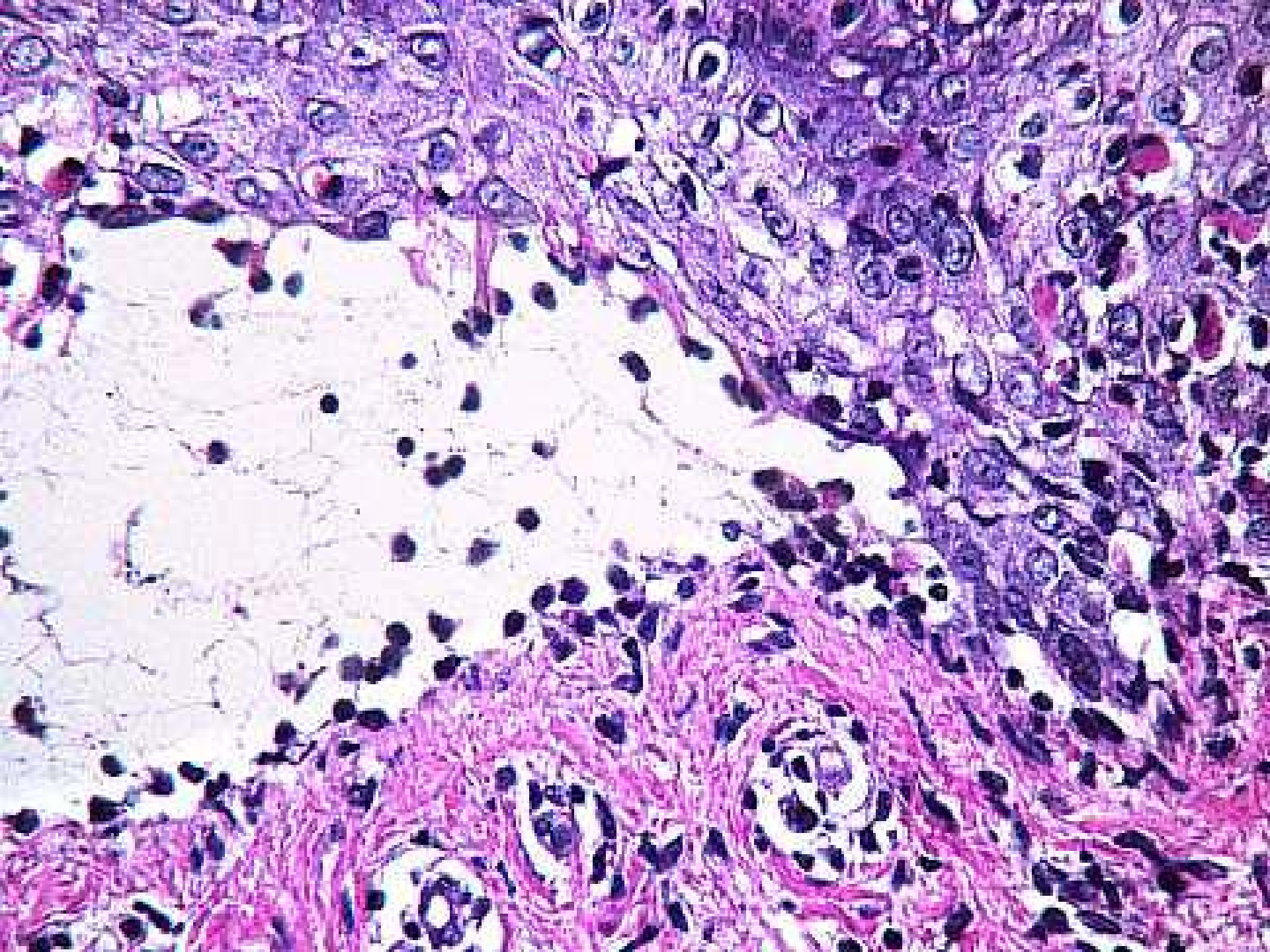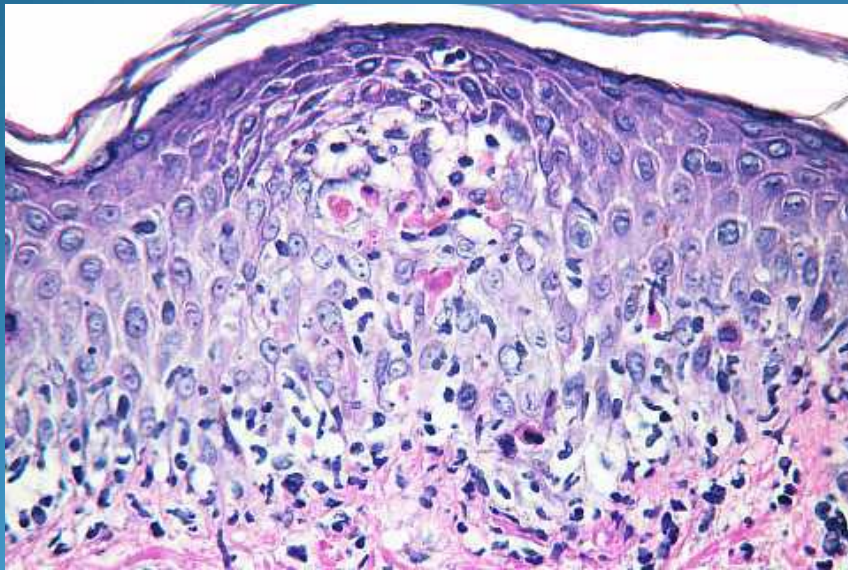


Erythema Multiforme

Pearls



- Cell poor lichenoid interface dermatitis
- Dyskeratotic keratinocytes at the dermal-epidermal junction
- May have intra- or subepidermal bullae