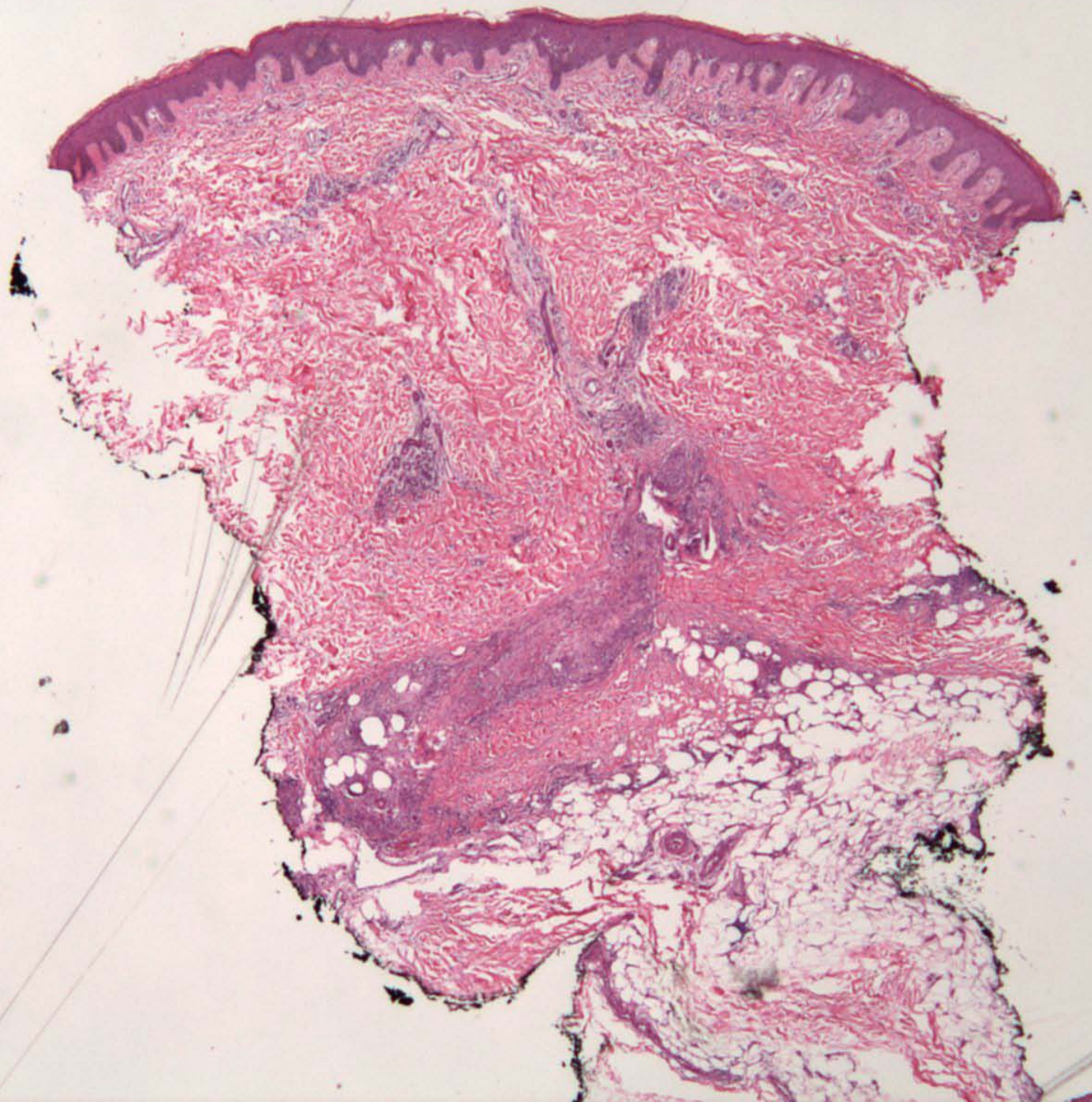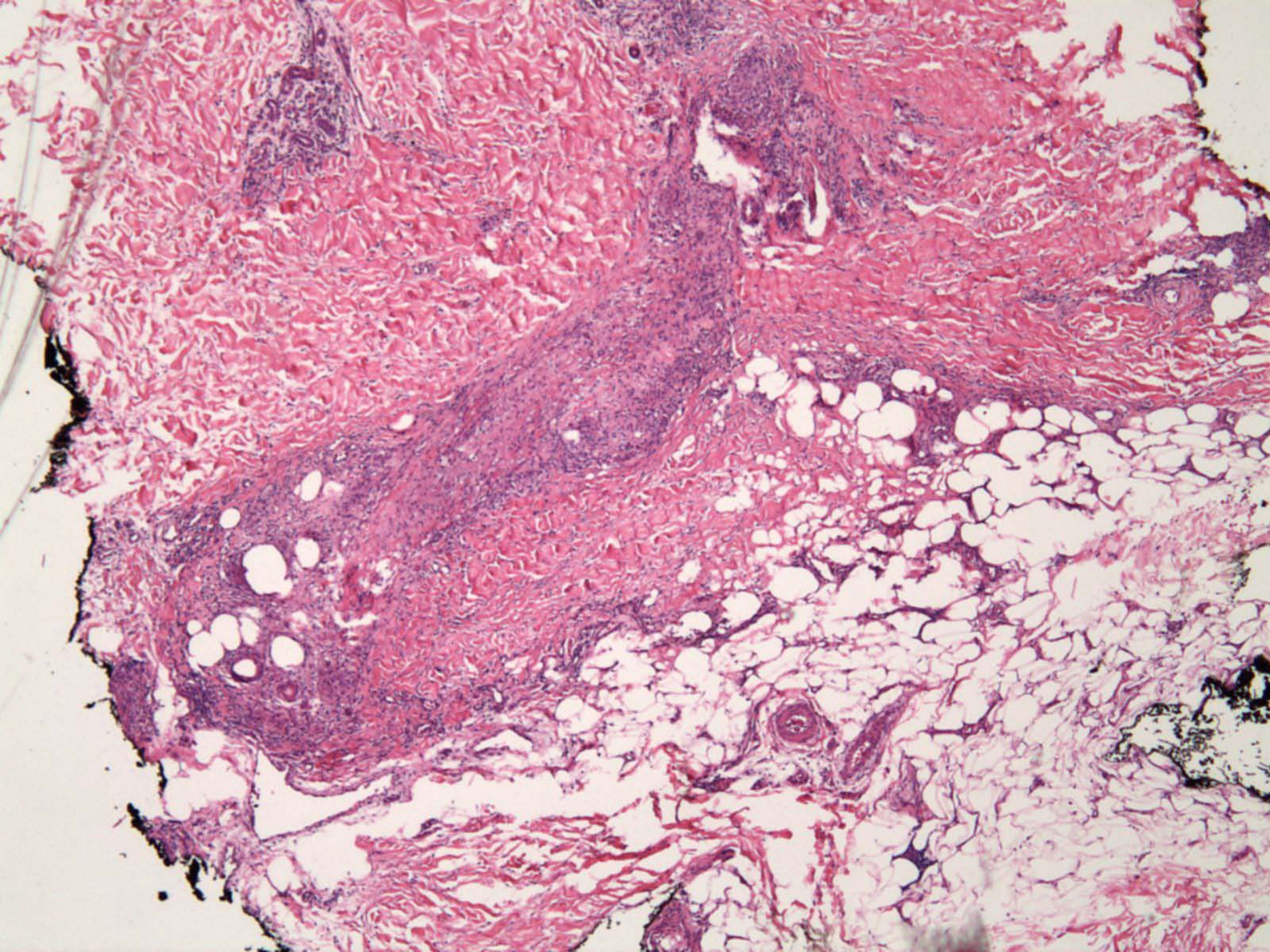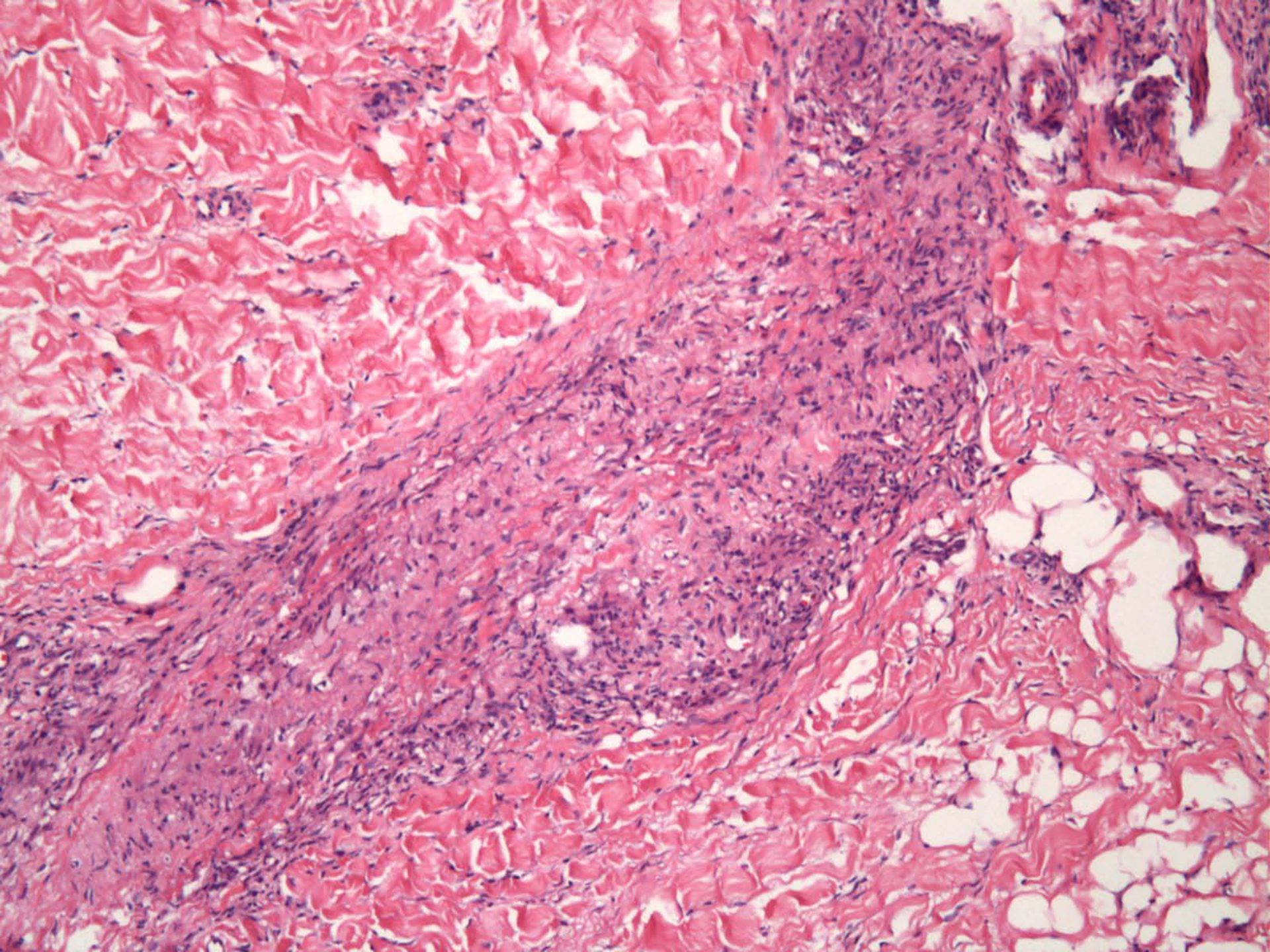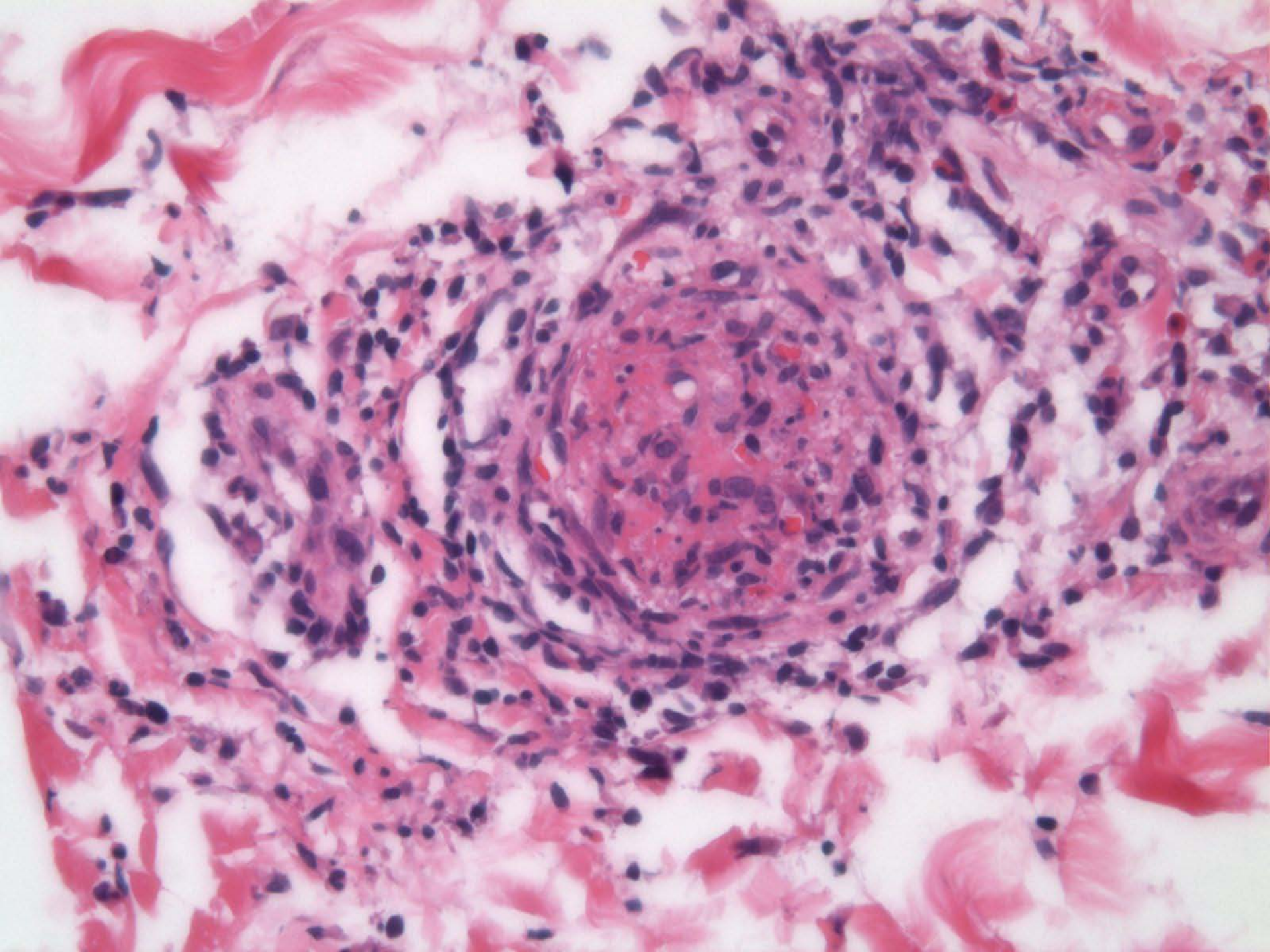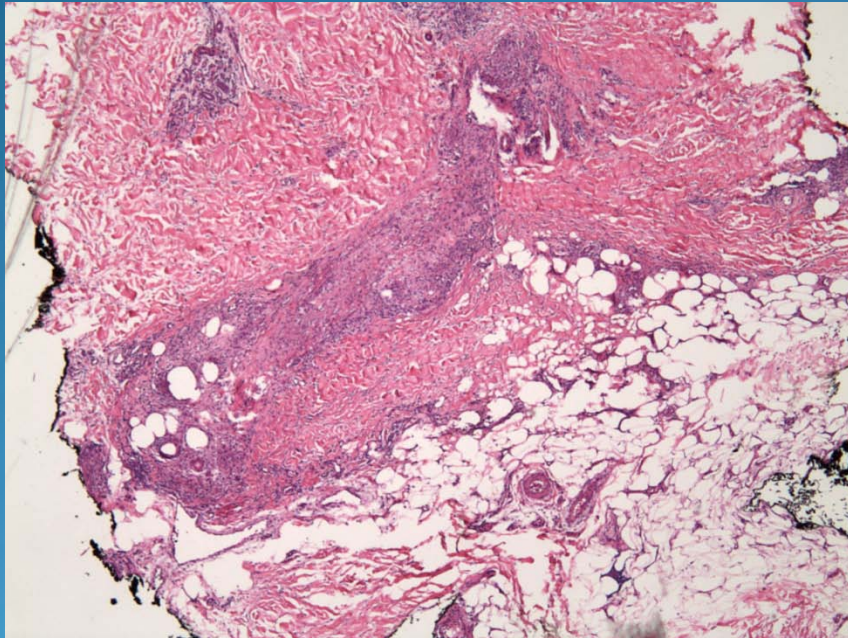


# Erythema Induratum (Nodular Vasculitis)

# Pearls



- Predominately septal panniculitis
- Look for vasculitis of vessels in septa- especially fibrinoid necrosis