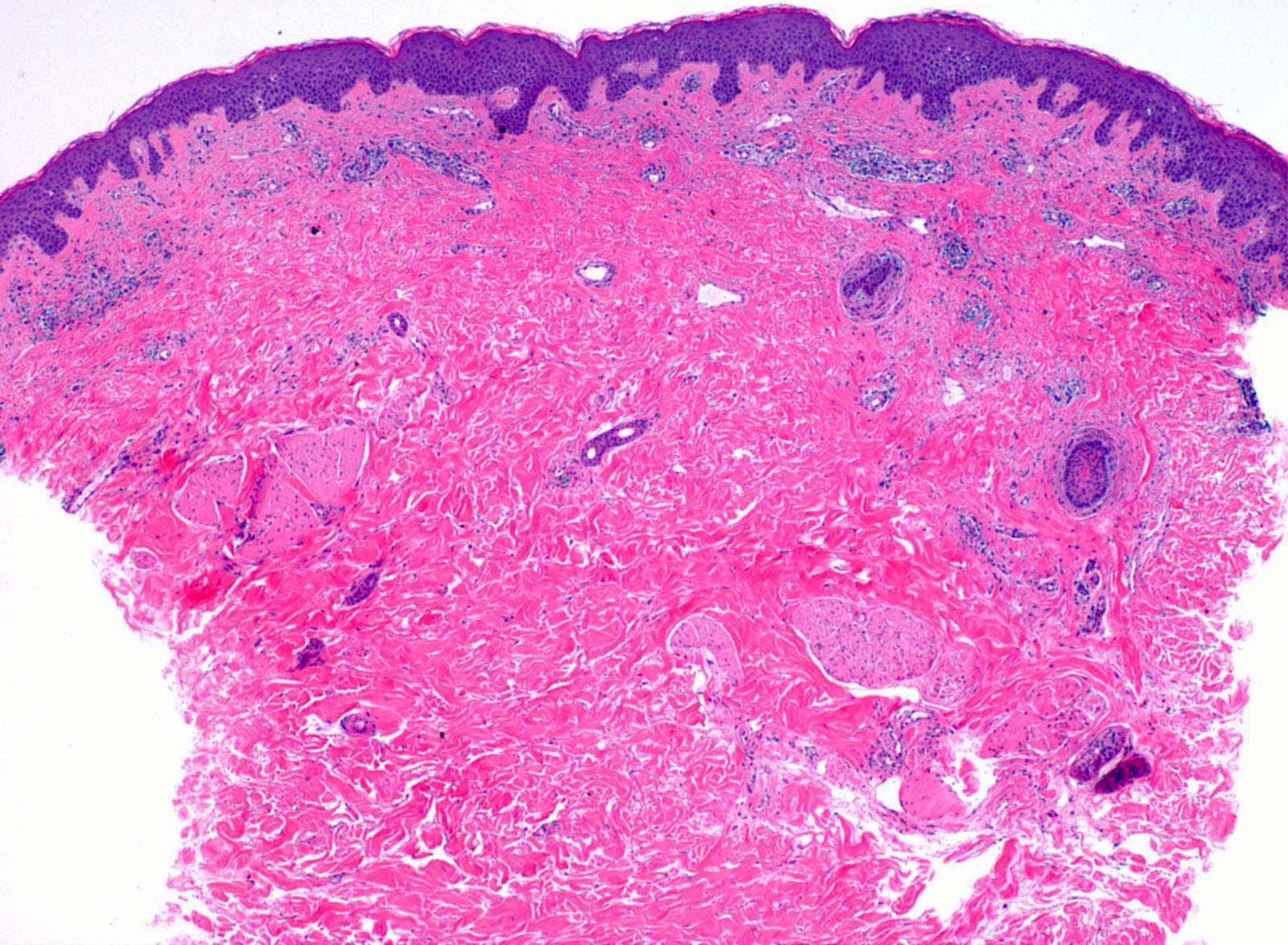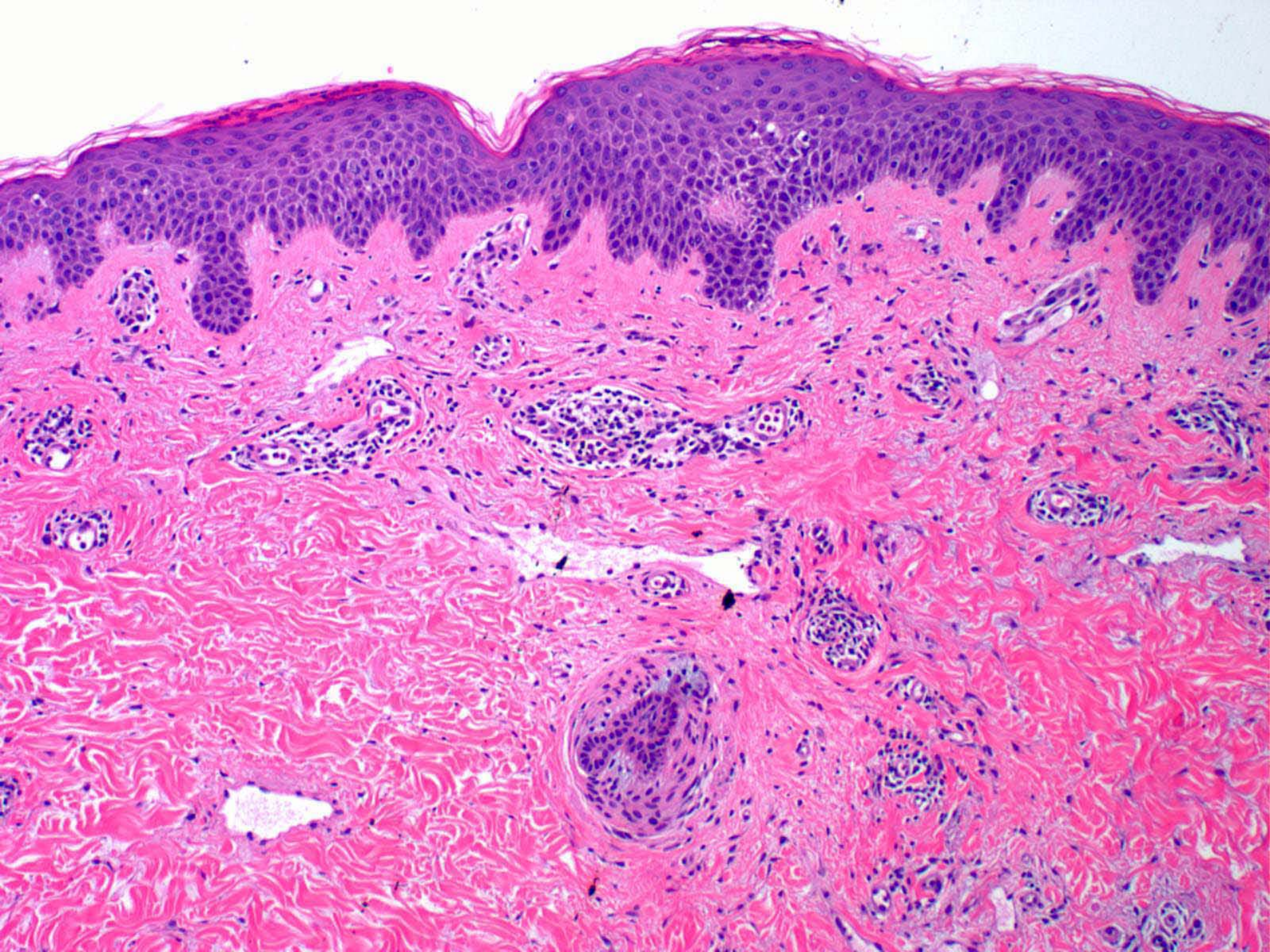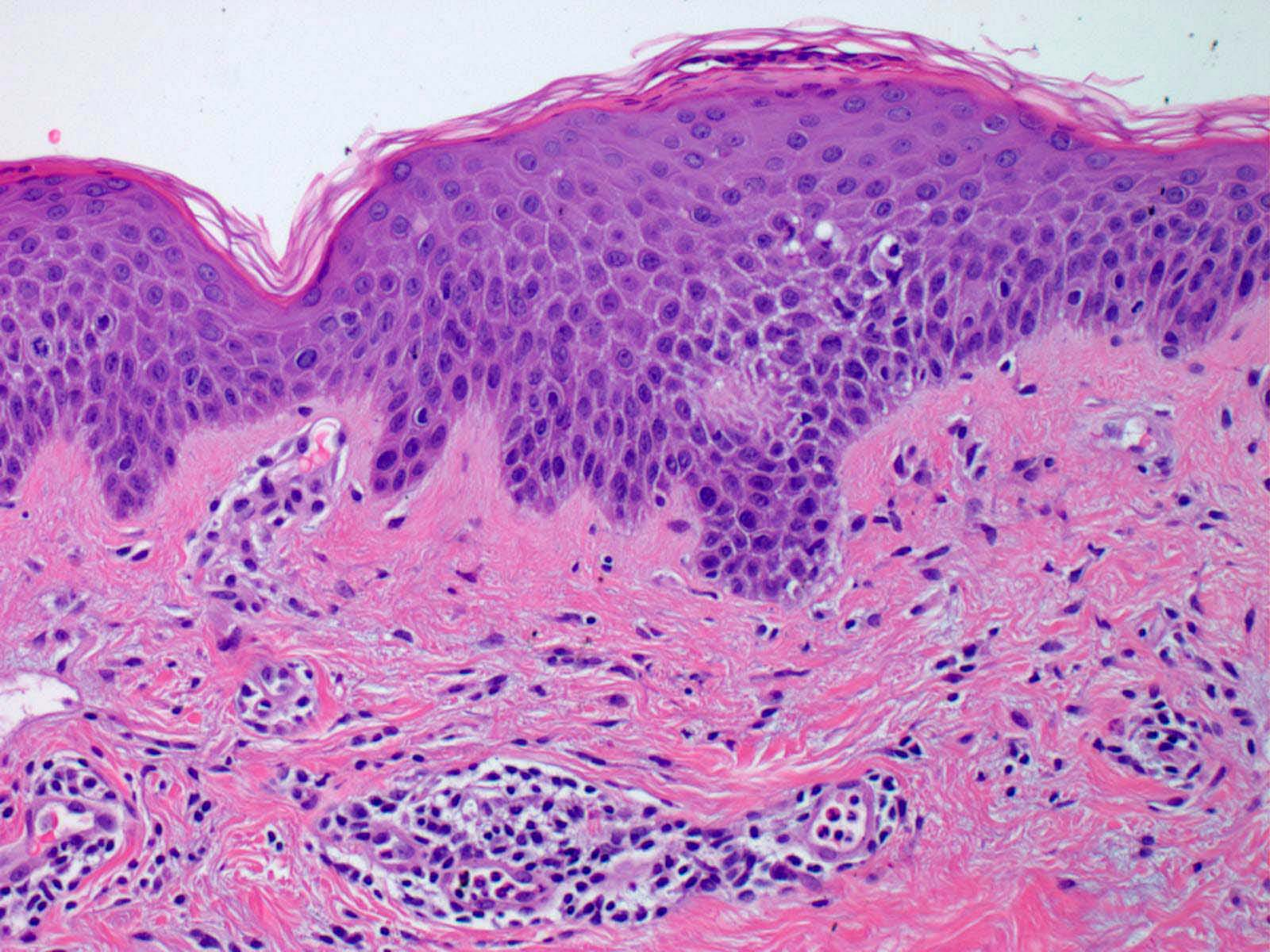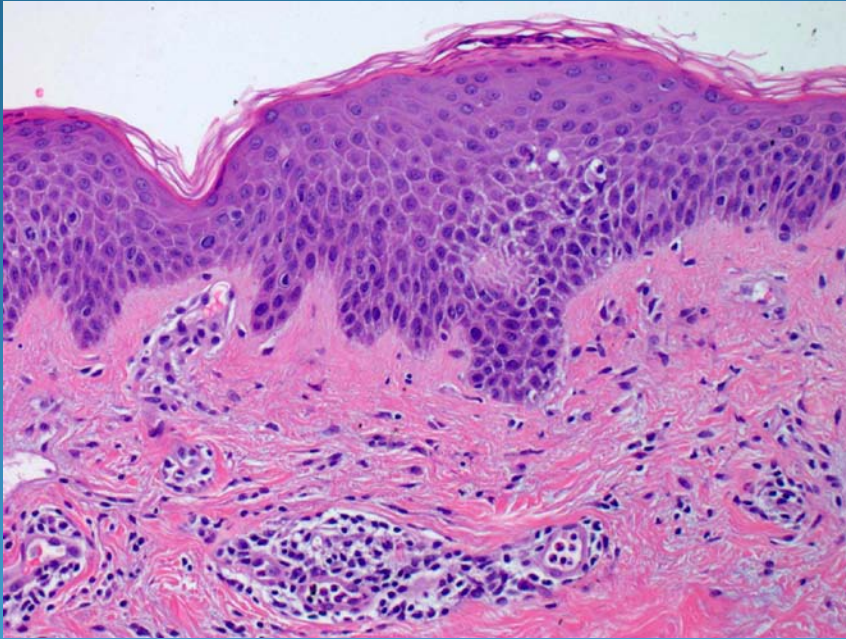


Erythema annulare centrifugum

# Pearls



- “Coat sleeve” perivascular lymphocytic infiltrate
- No interface dermatitis or mucinosis