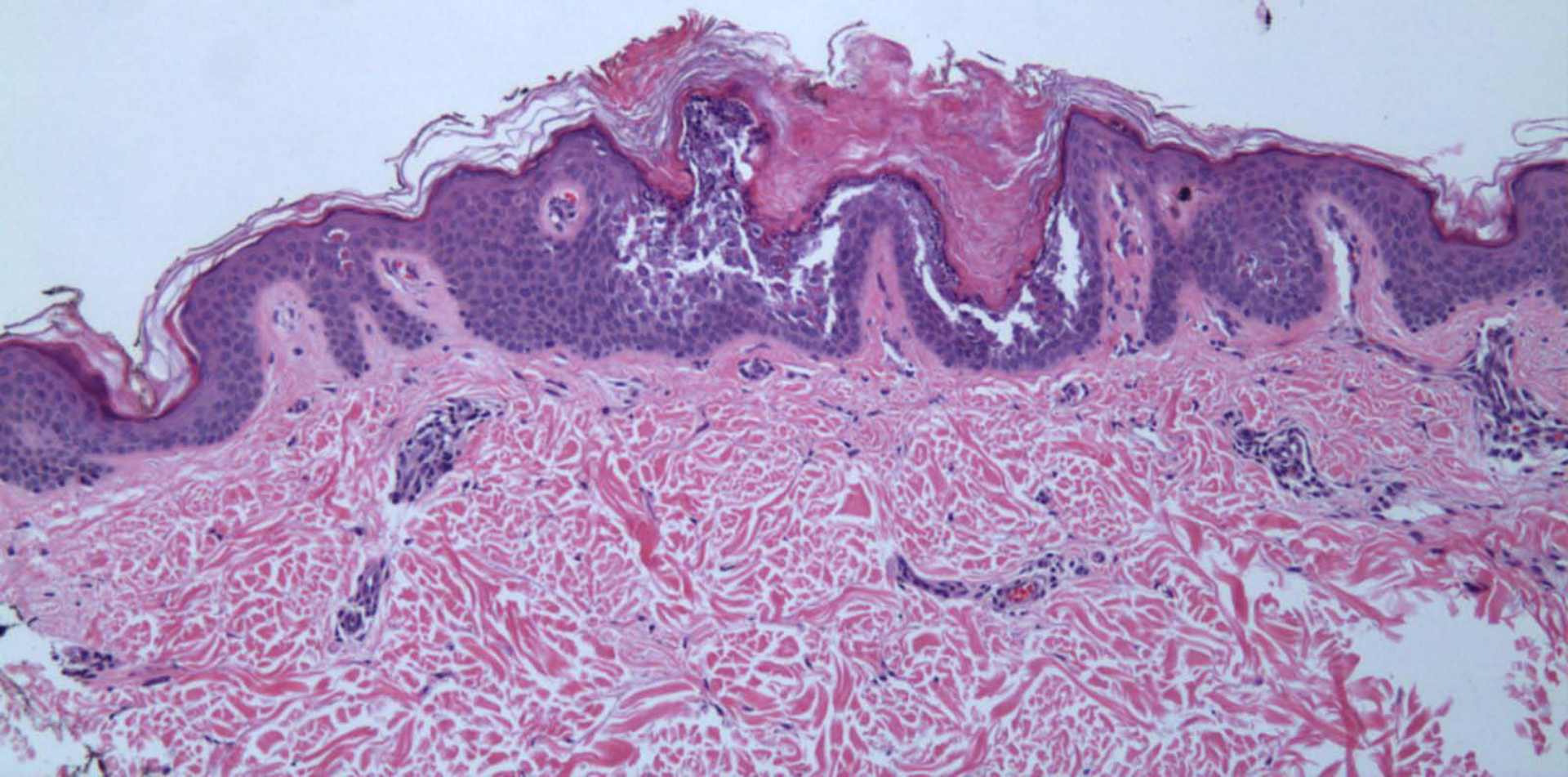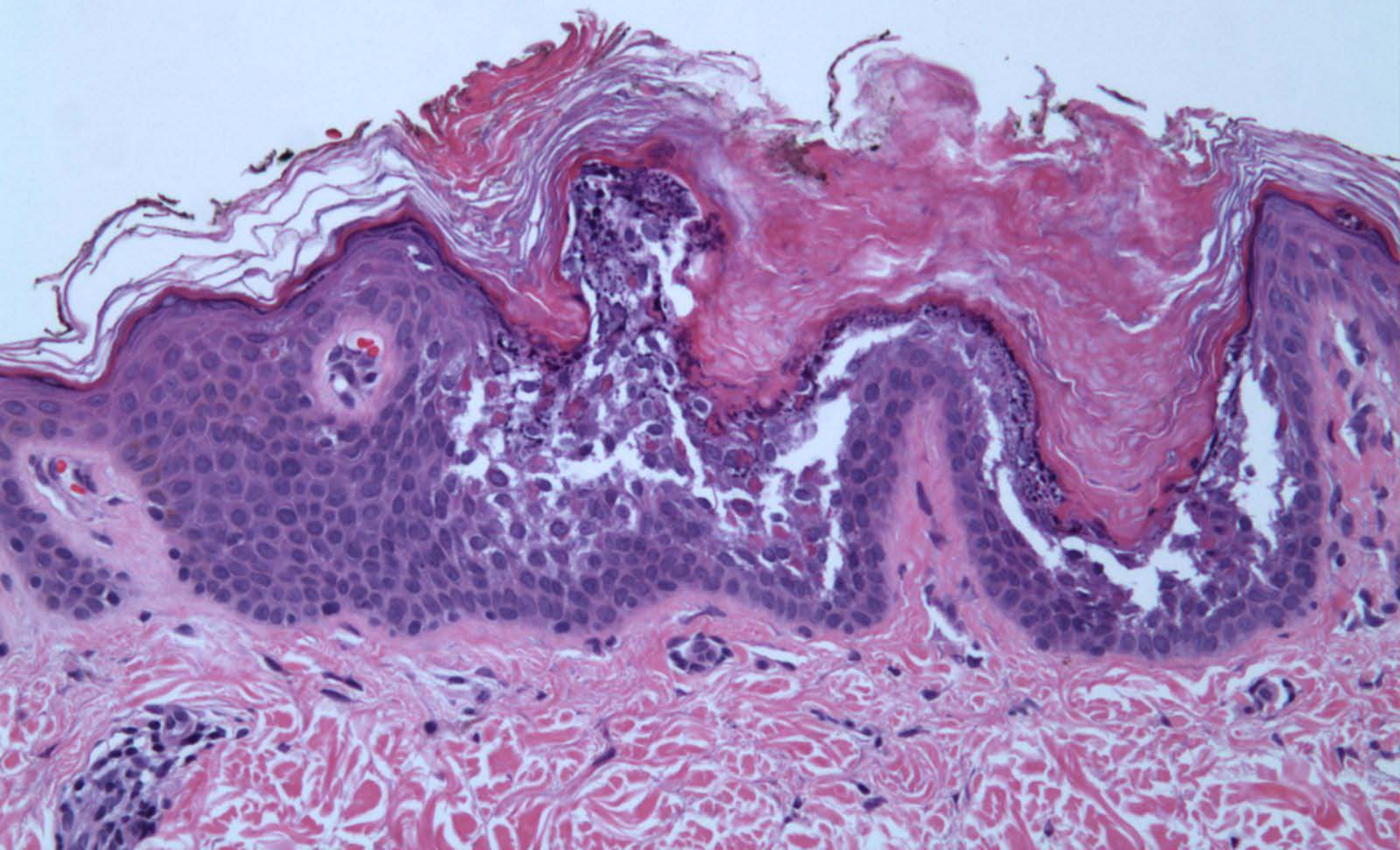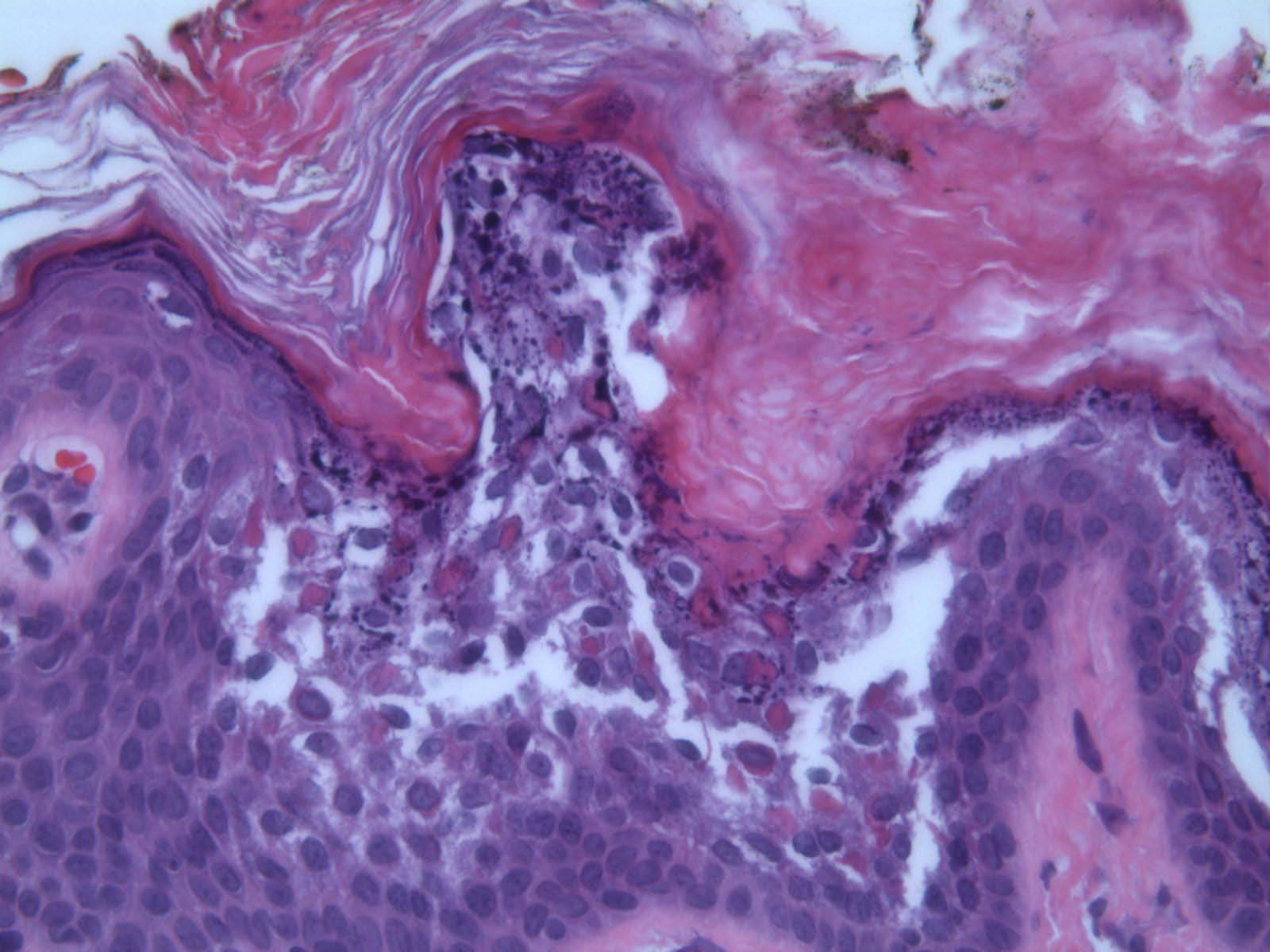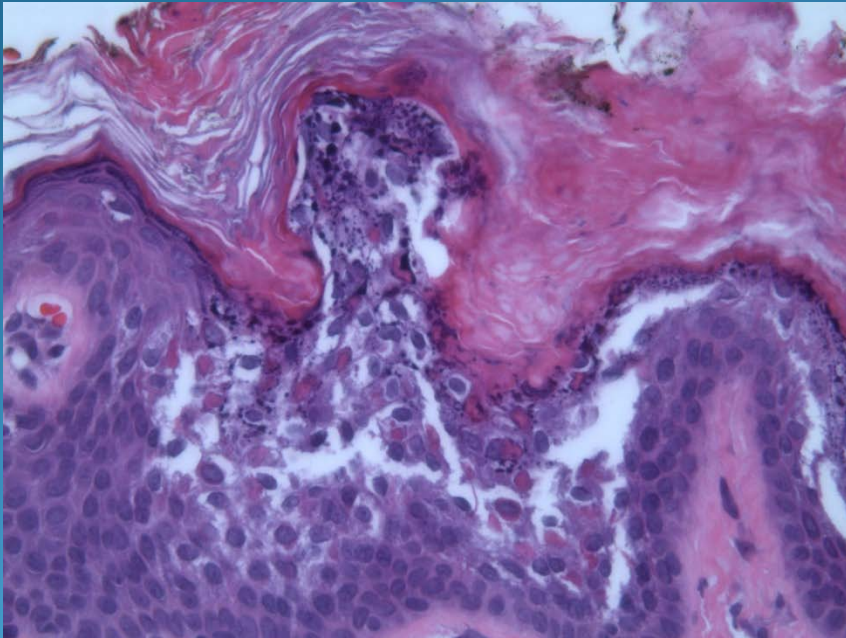


Epidermolytic Hyperkeratosis

Pearls



- Clumped keratohyaline granules
- Empty clear cytoplasmic spaces
- Hyperkeratosis
- No koilocytes or atypia