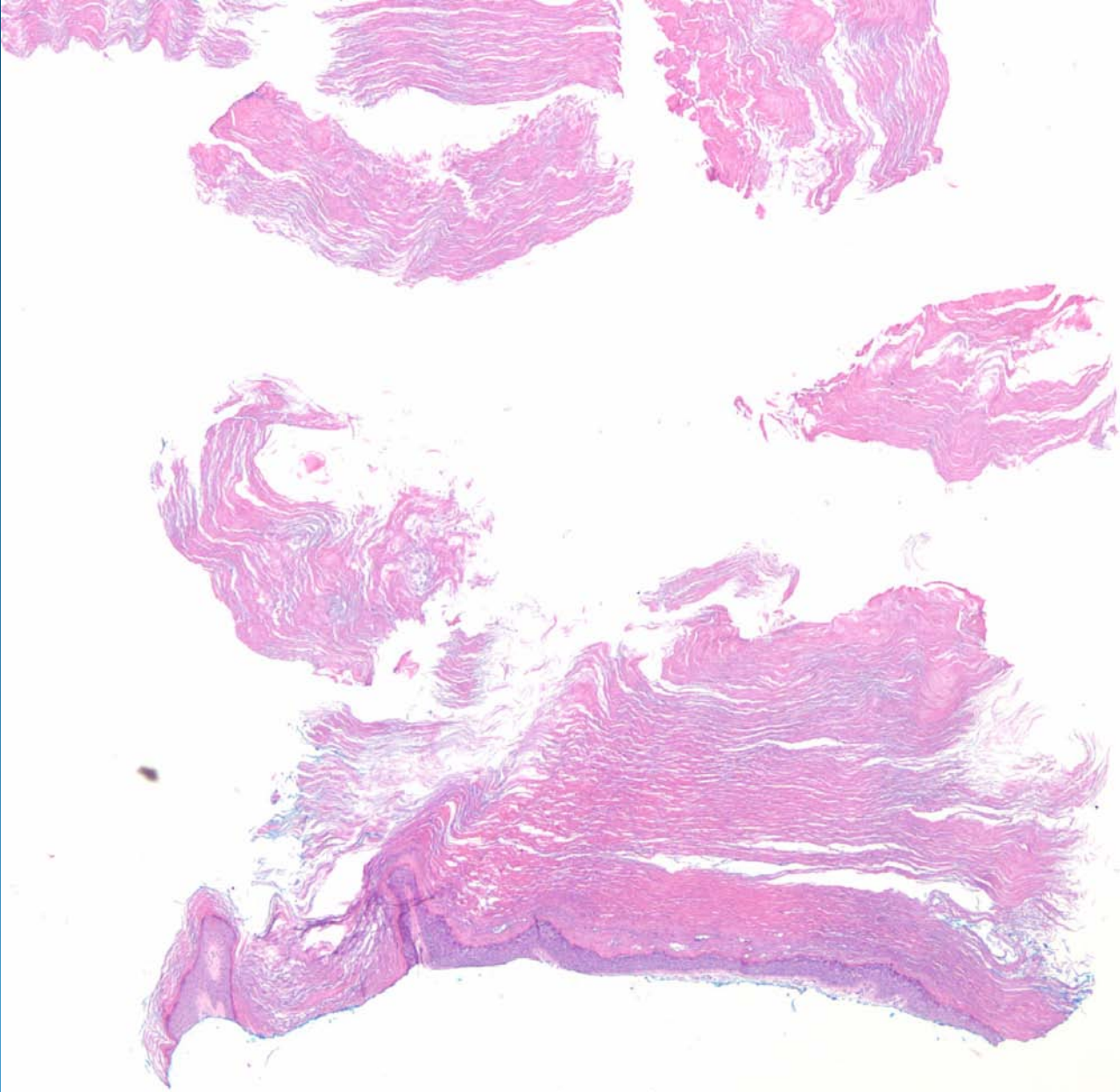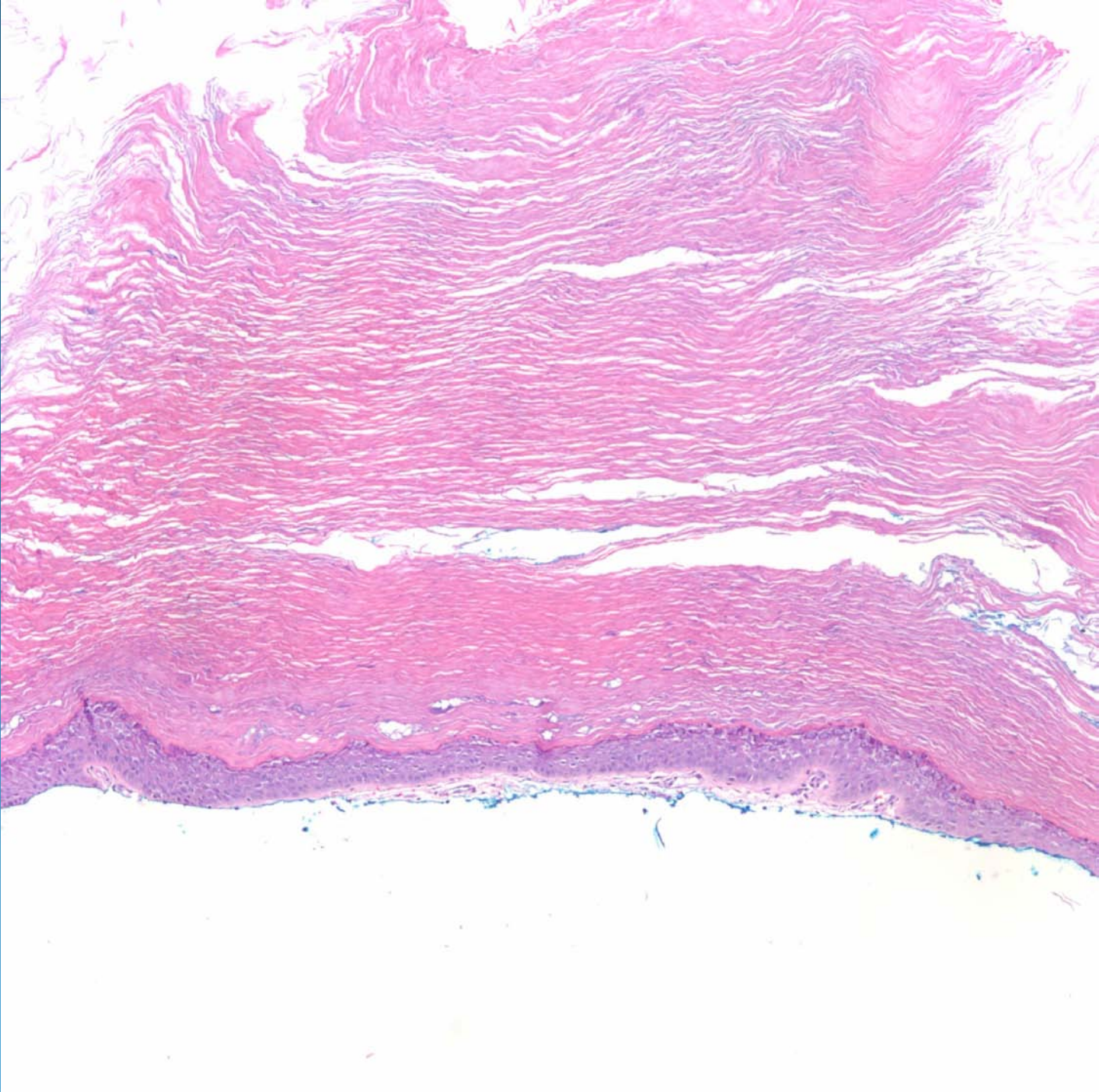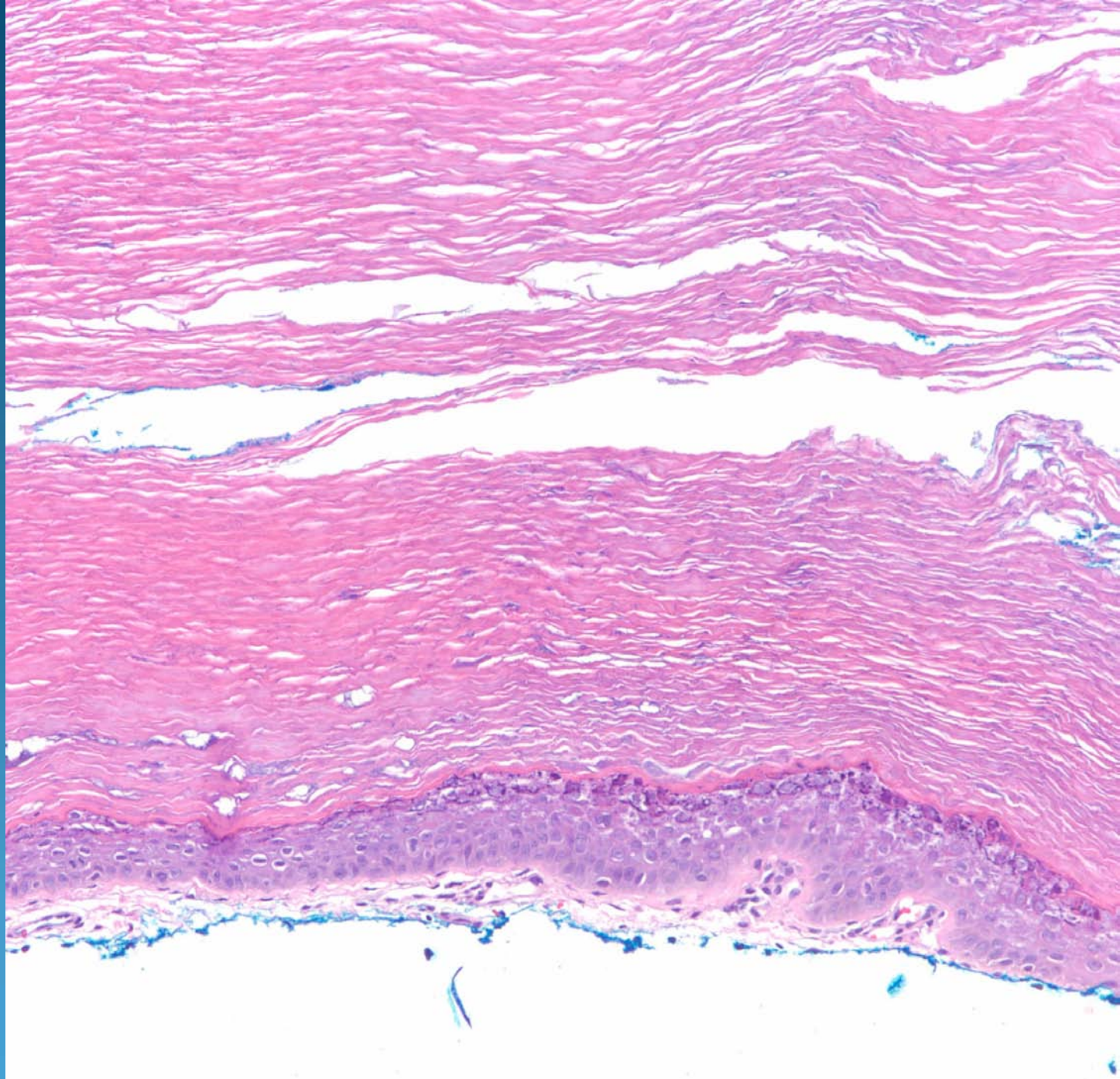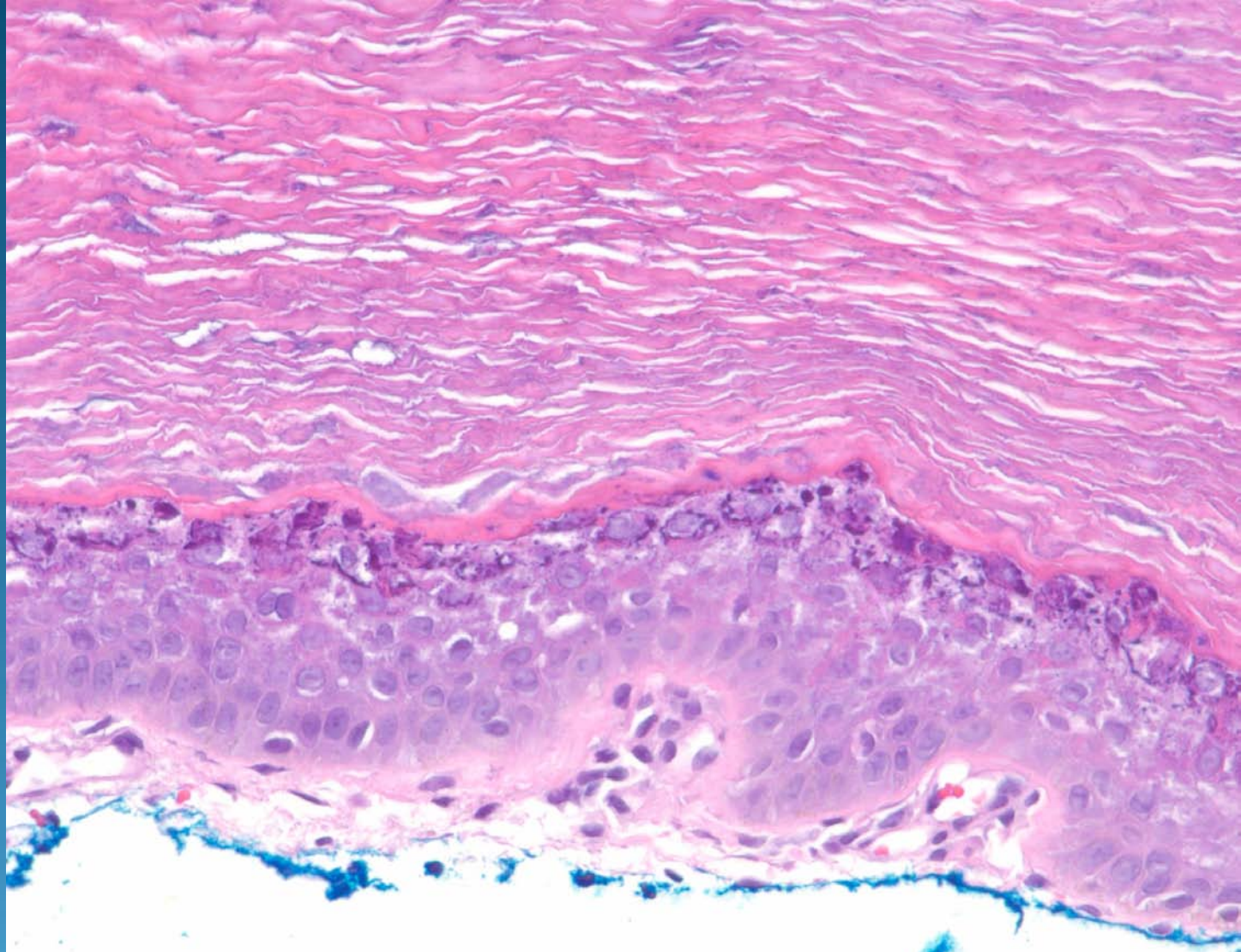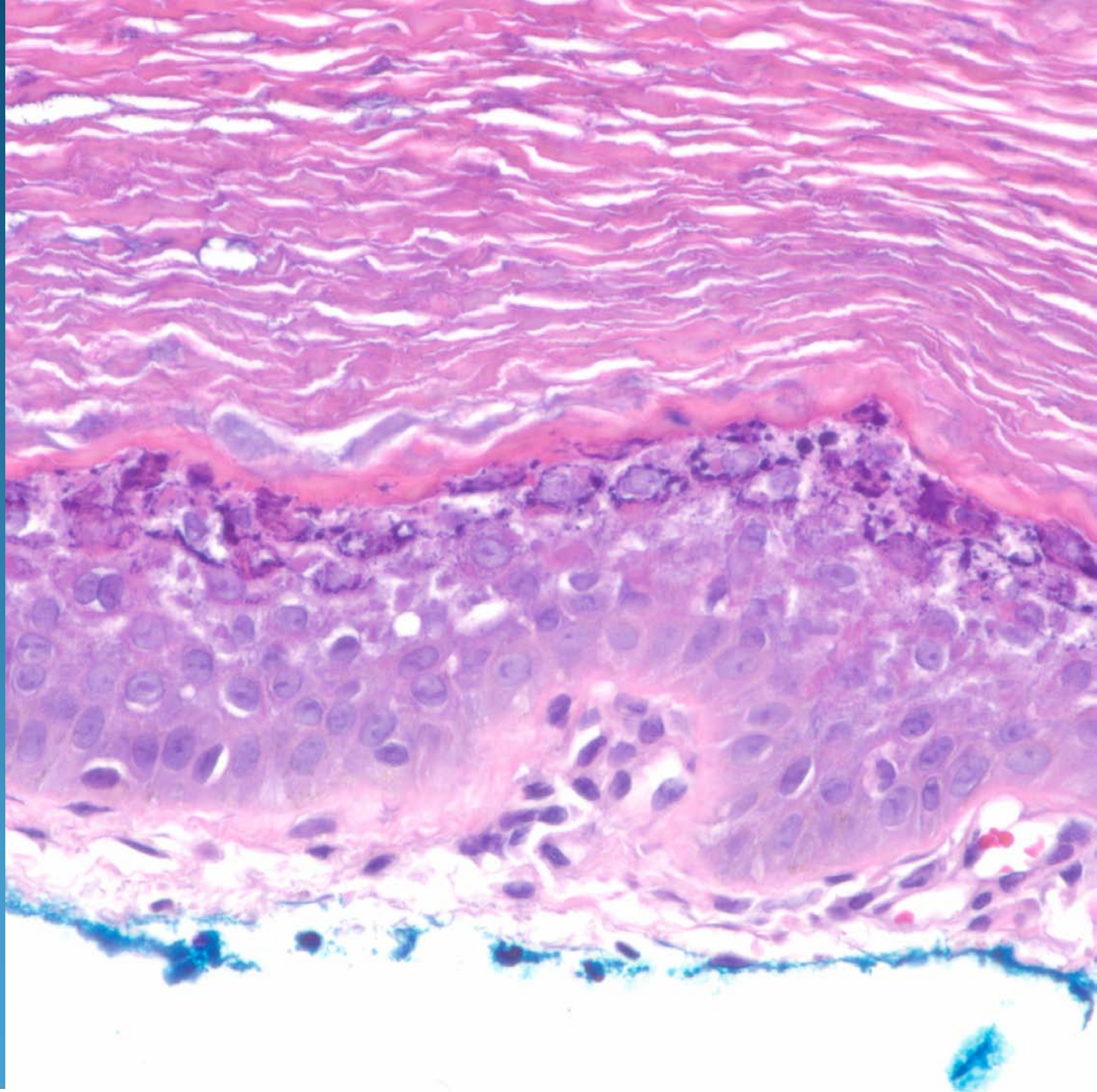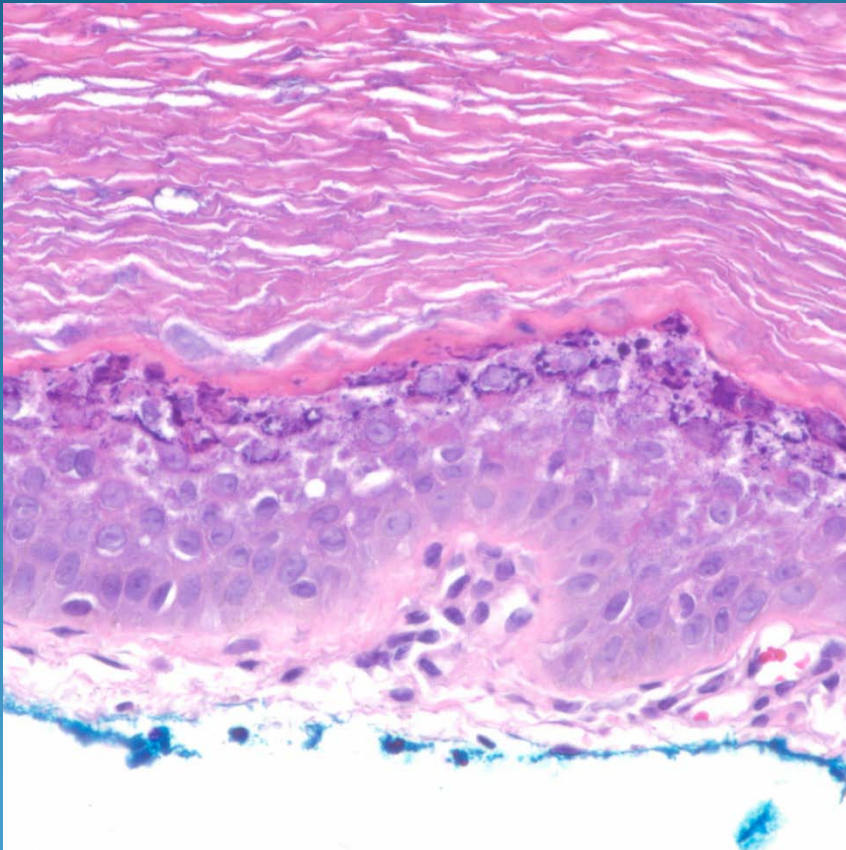


Epidermolytic Hyperkeratosis

Pearls



- Hyper -and parakeratosis
- Dissolution of the granular layer
- No koilocytes or epithelial dysplasia identified