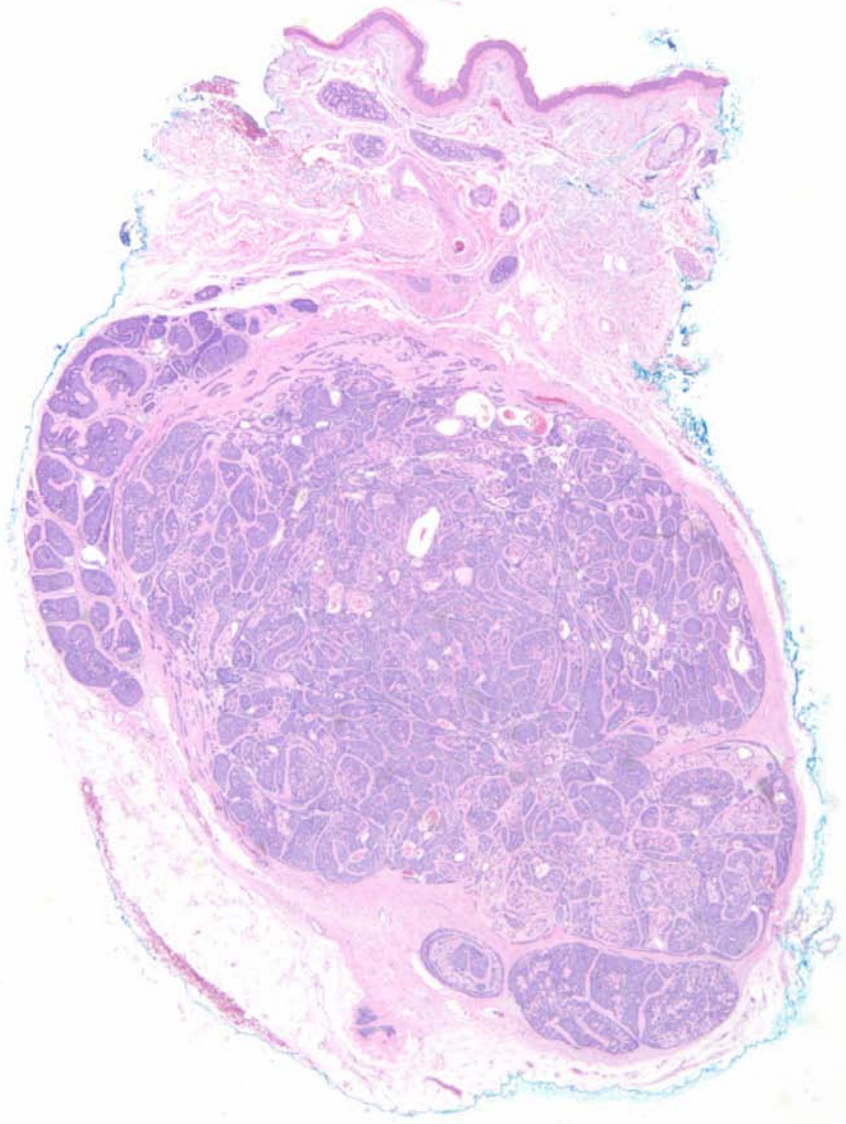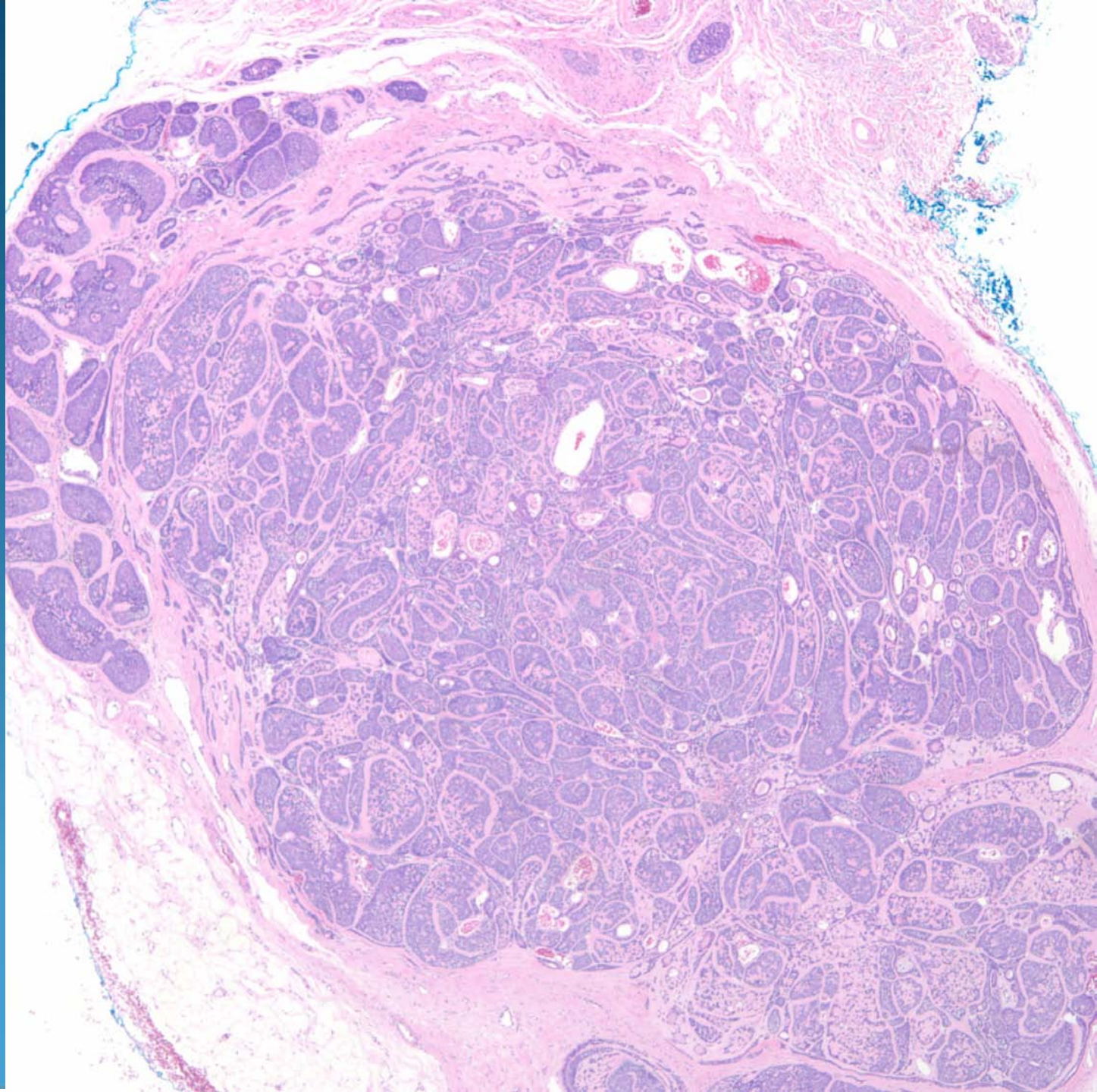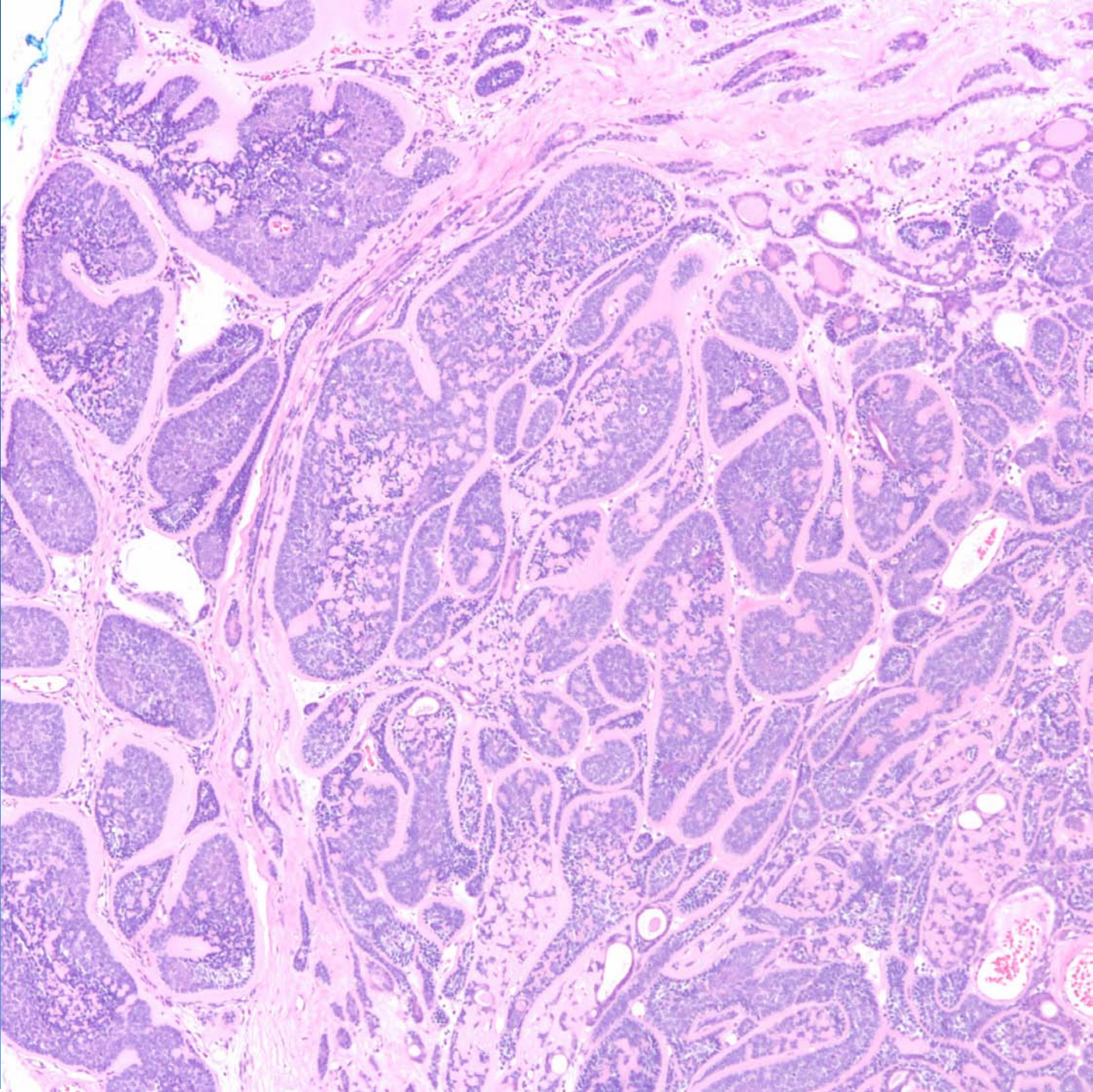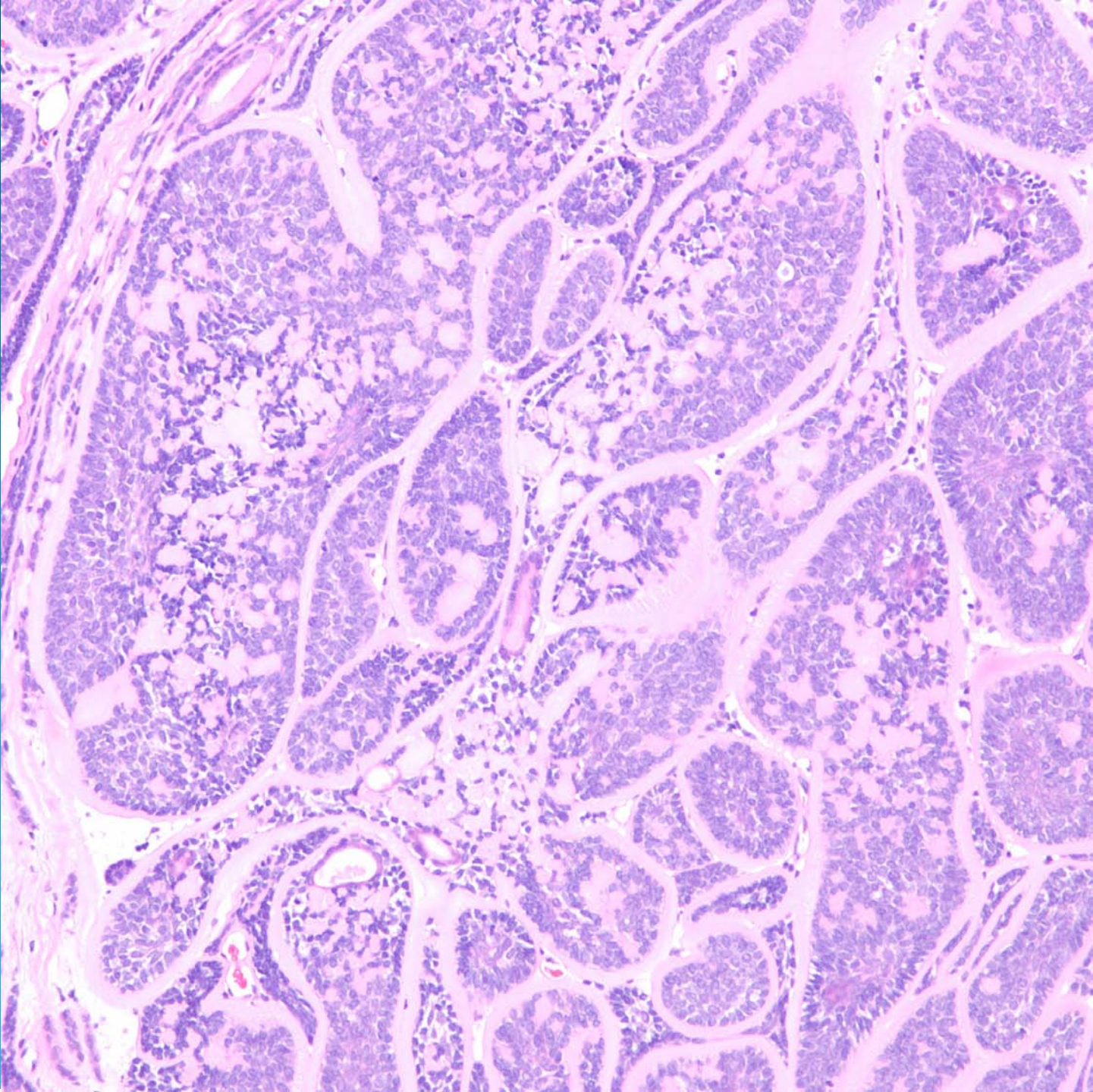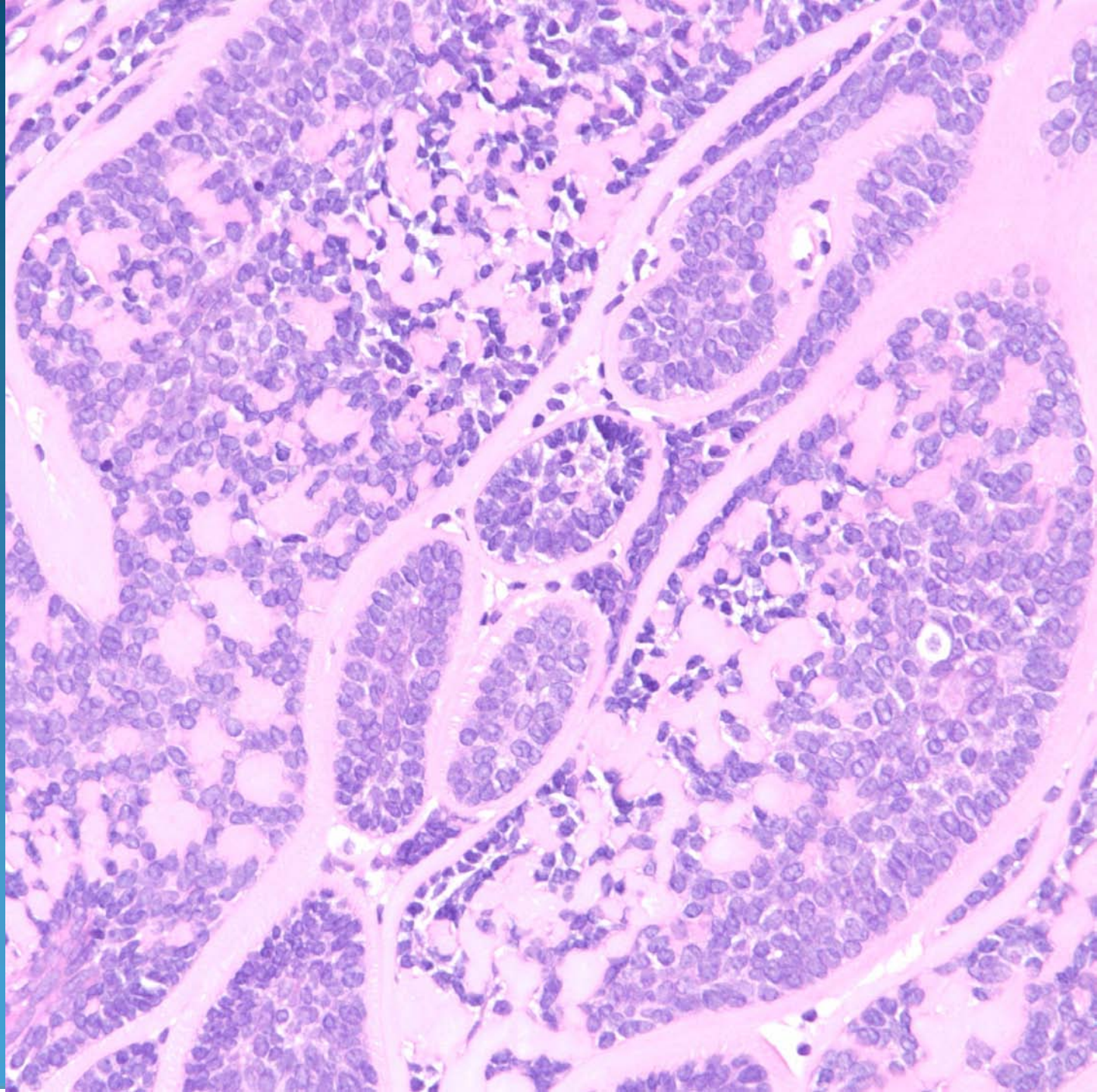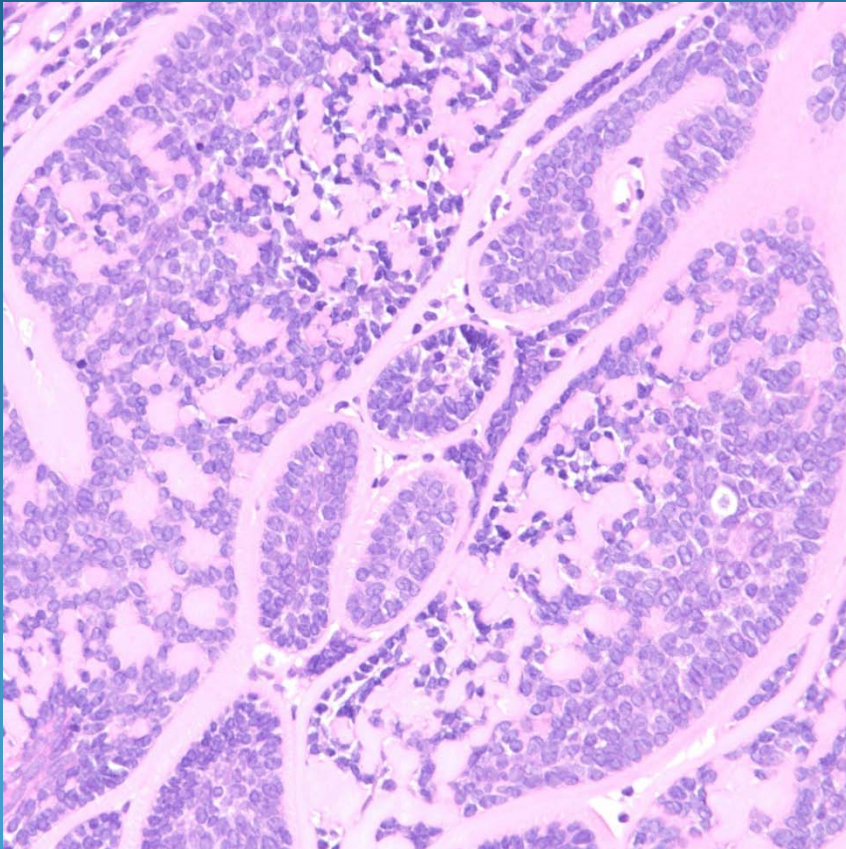


# Eccrine Spiradenoma

# Pearls



- Circumscribed dermal basophilic nodule
- Hyalinized basement membrane subdividing nodules
- Gum-droplets of hyaline
- No cytologic atypia