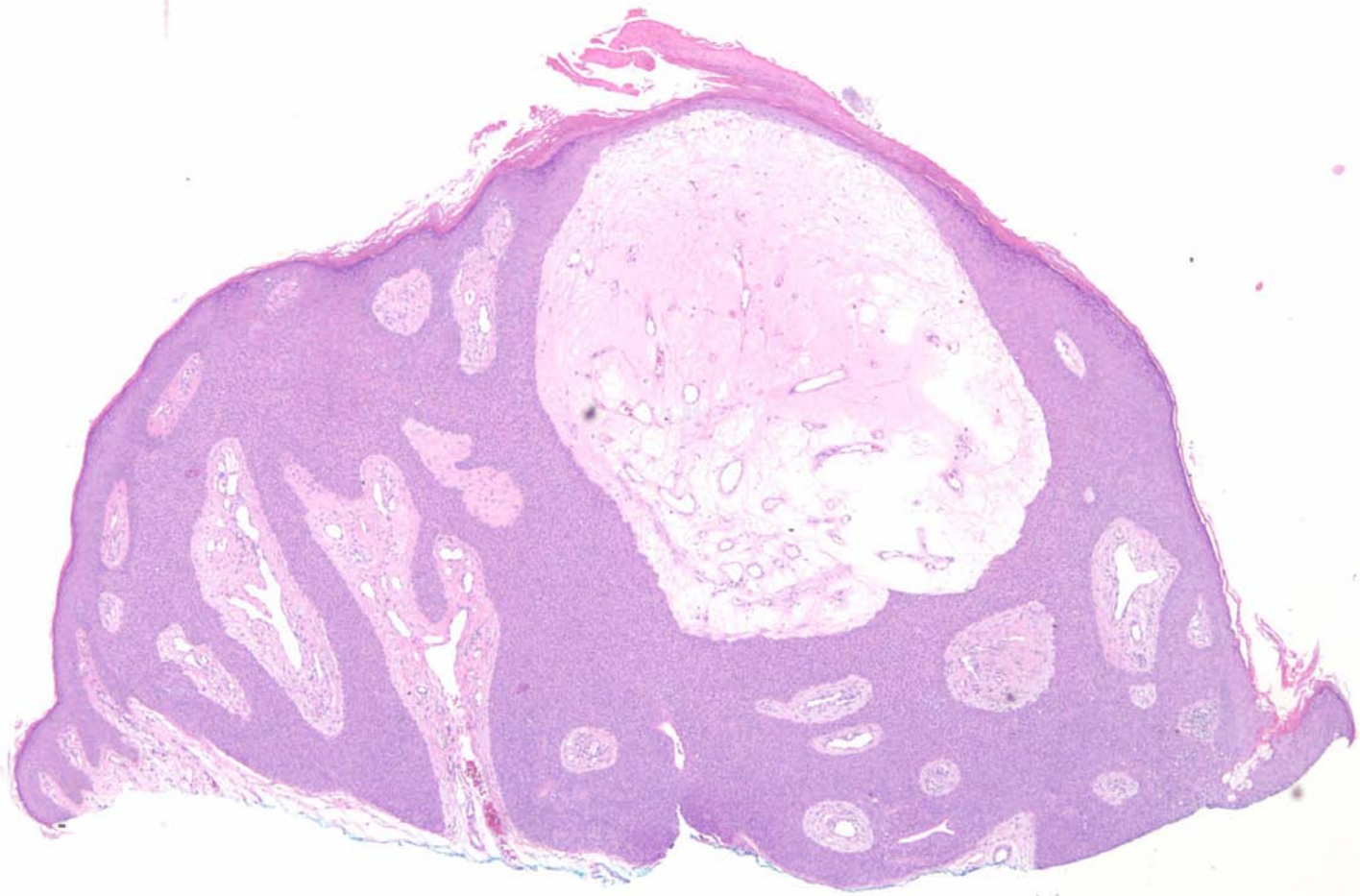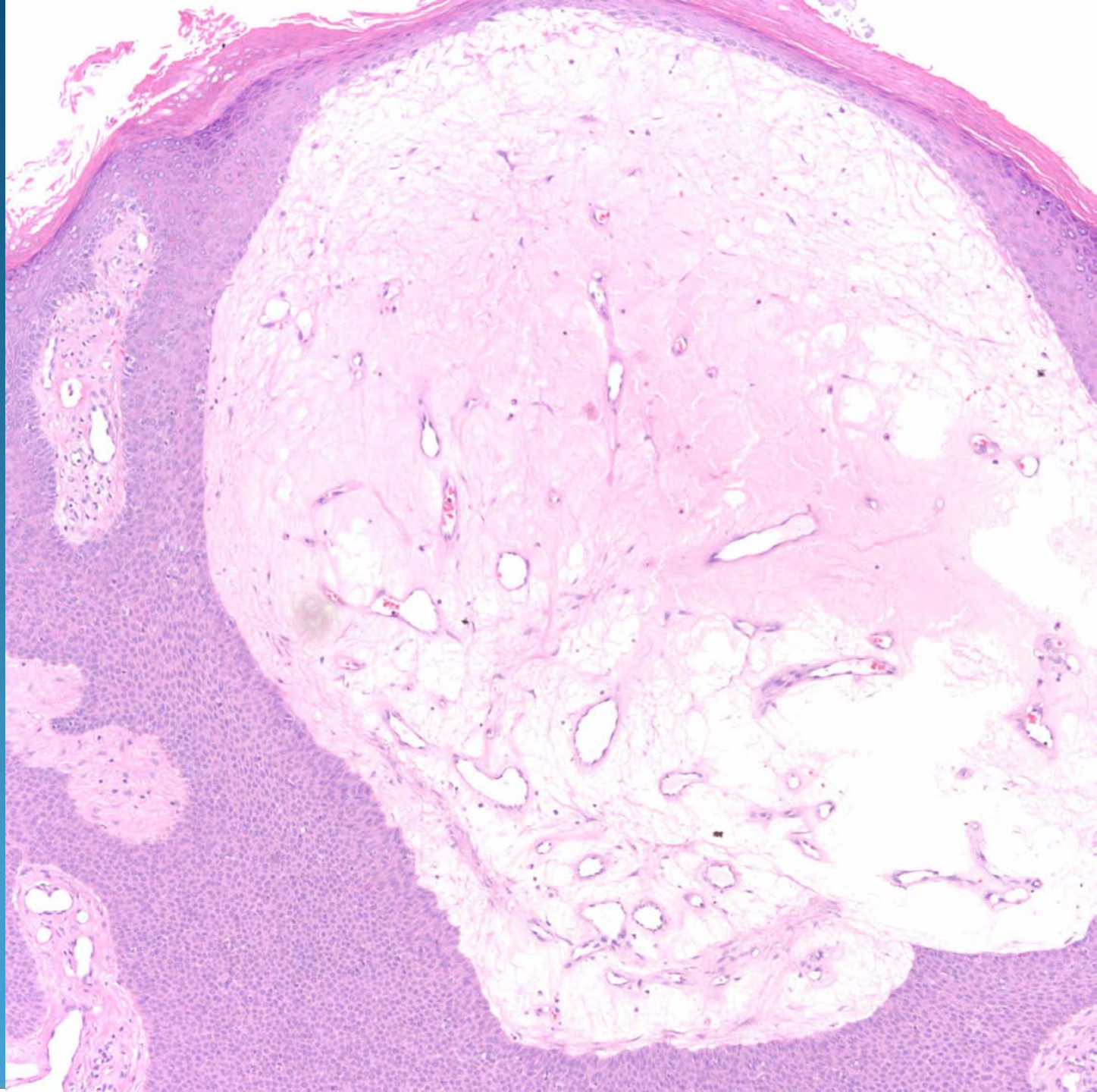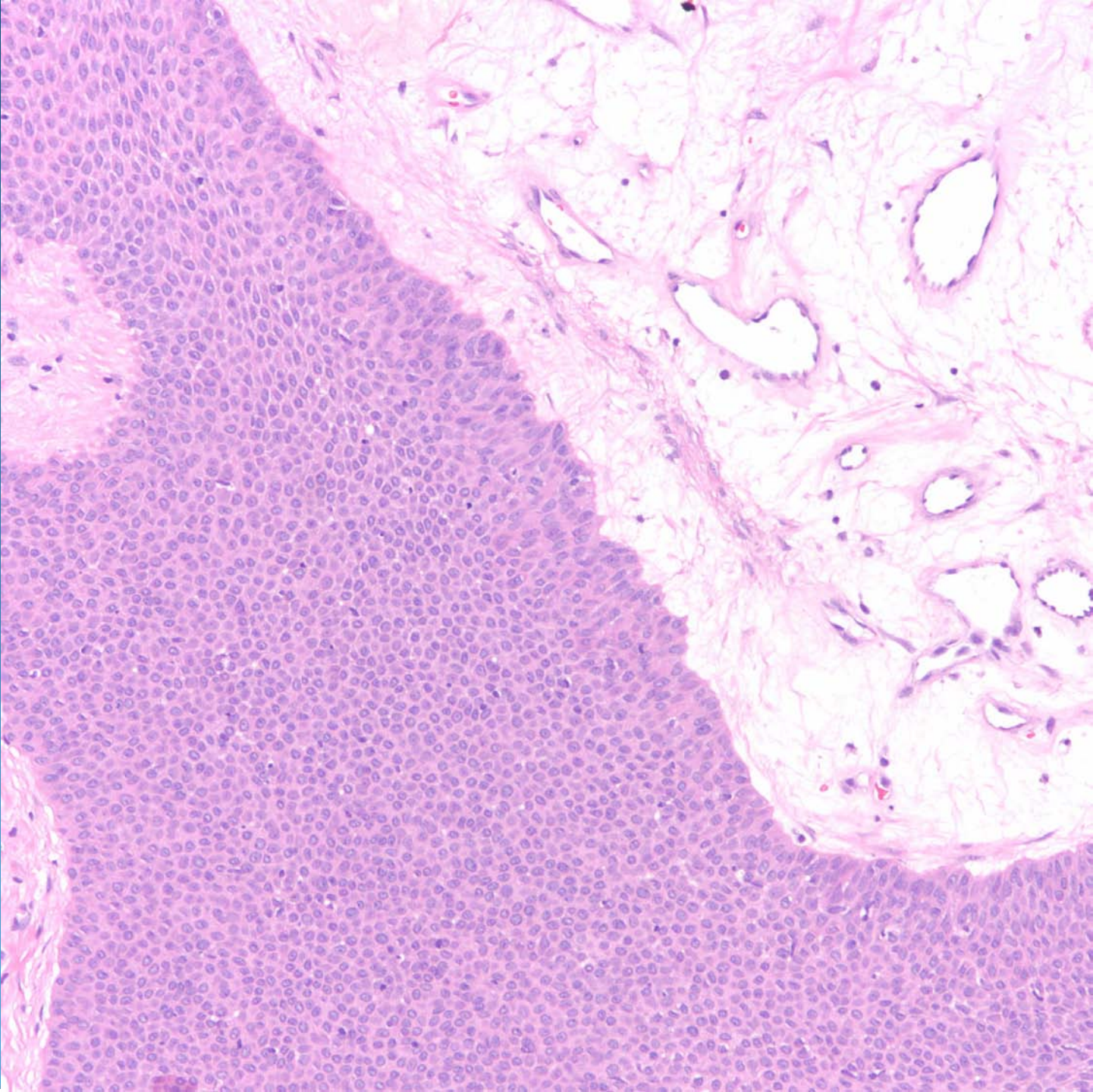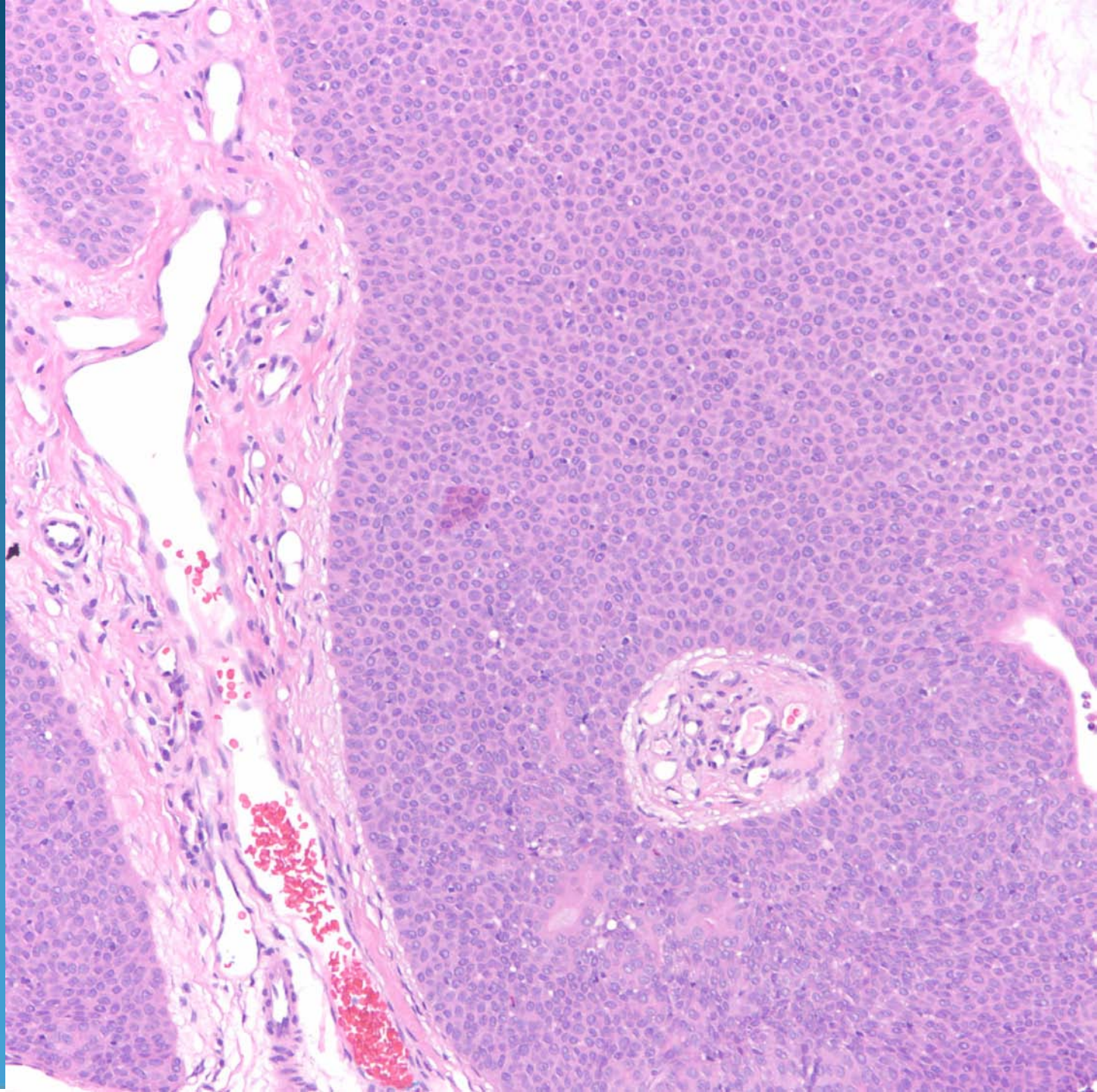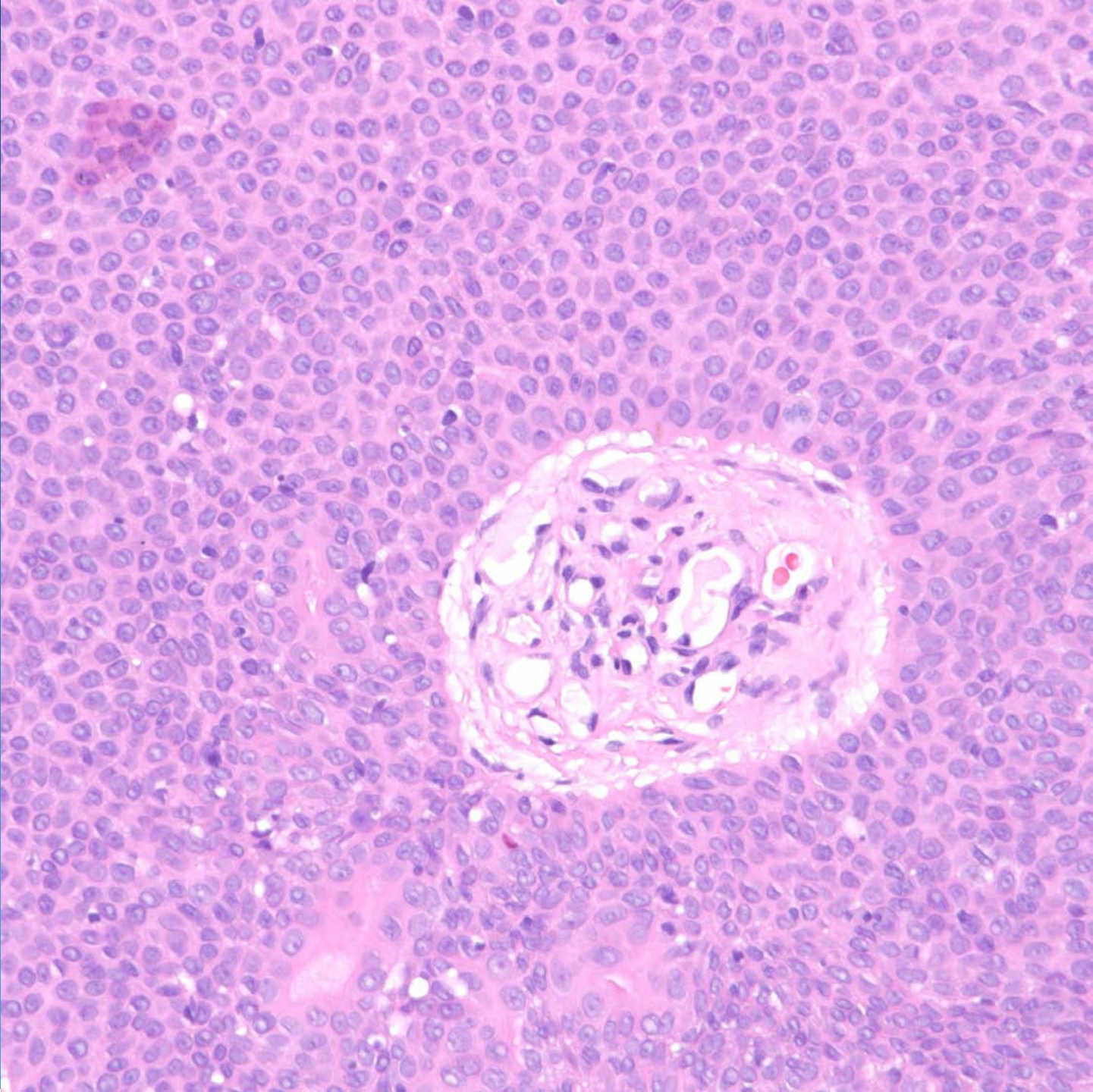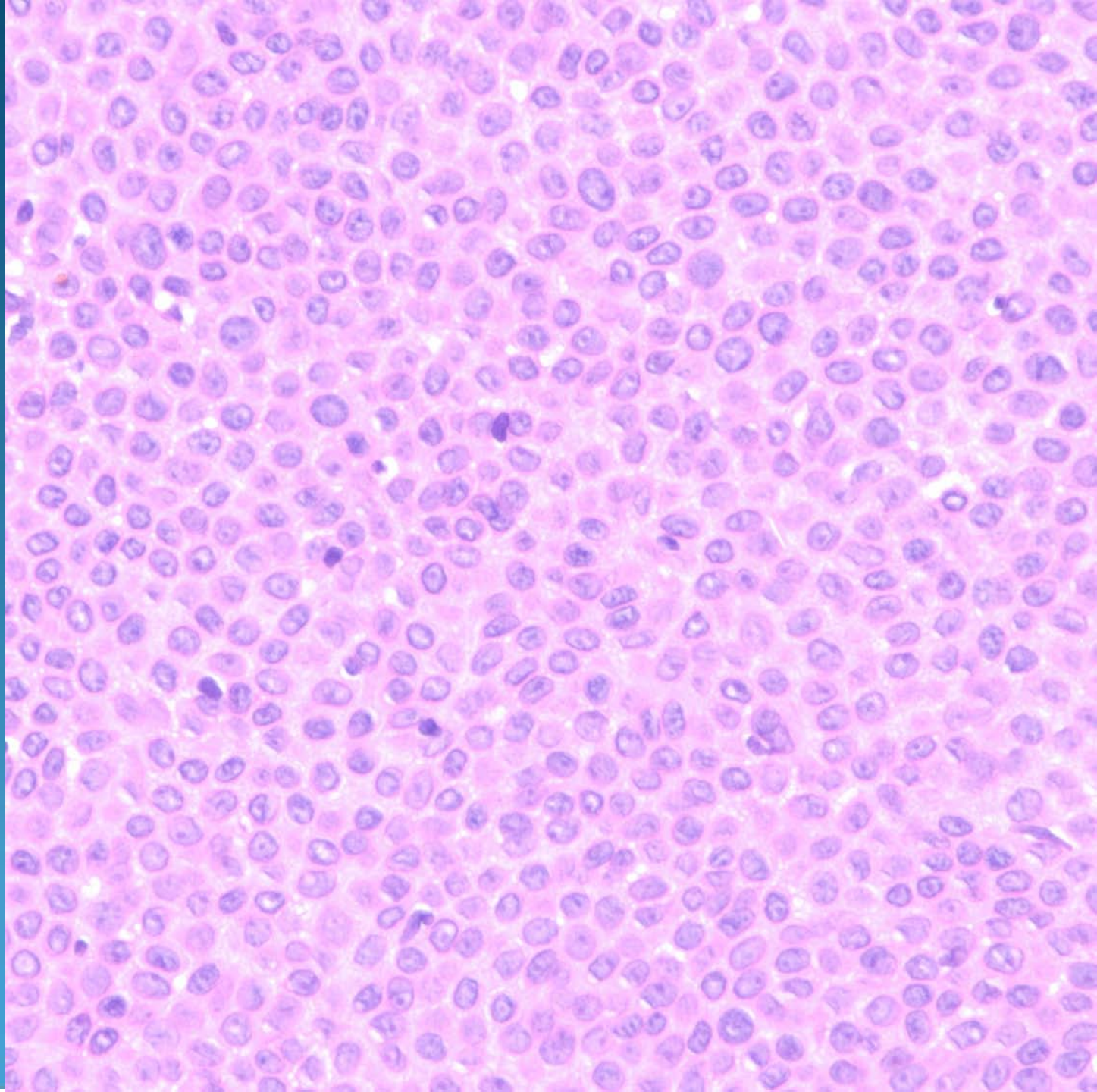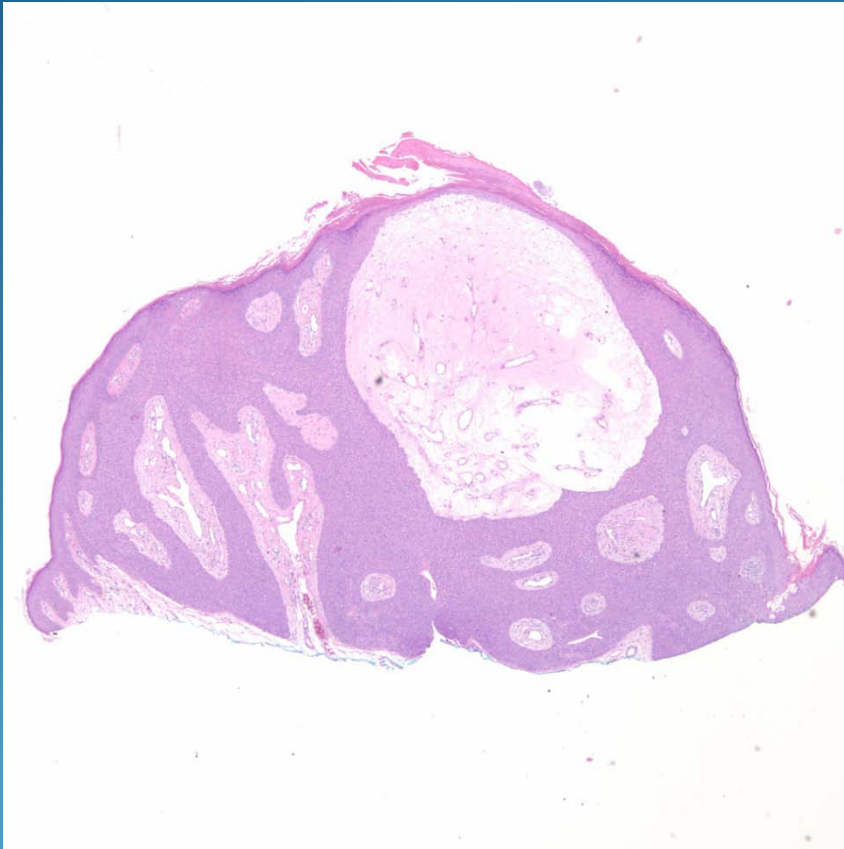


What is the best diagnosis?

- A. Eccrine poroma
- B. Seborrheic keratosis
- C. Glomus tumor
- D. Dermal duct tumor
- E. Tumor of the follicular infundibulum

Eccrine Poroma

Pearls



- Plate-like proliferation of cytologically bland keratinocytes
- Rounded pushing borders unlike seborrheic keratosis
- Hyalinized changes around vessels
- May have horn pseudocysts