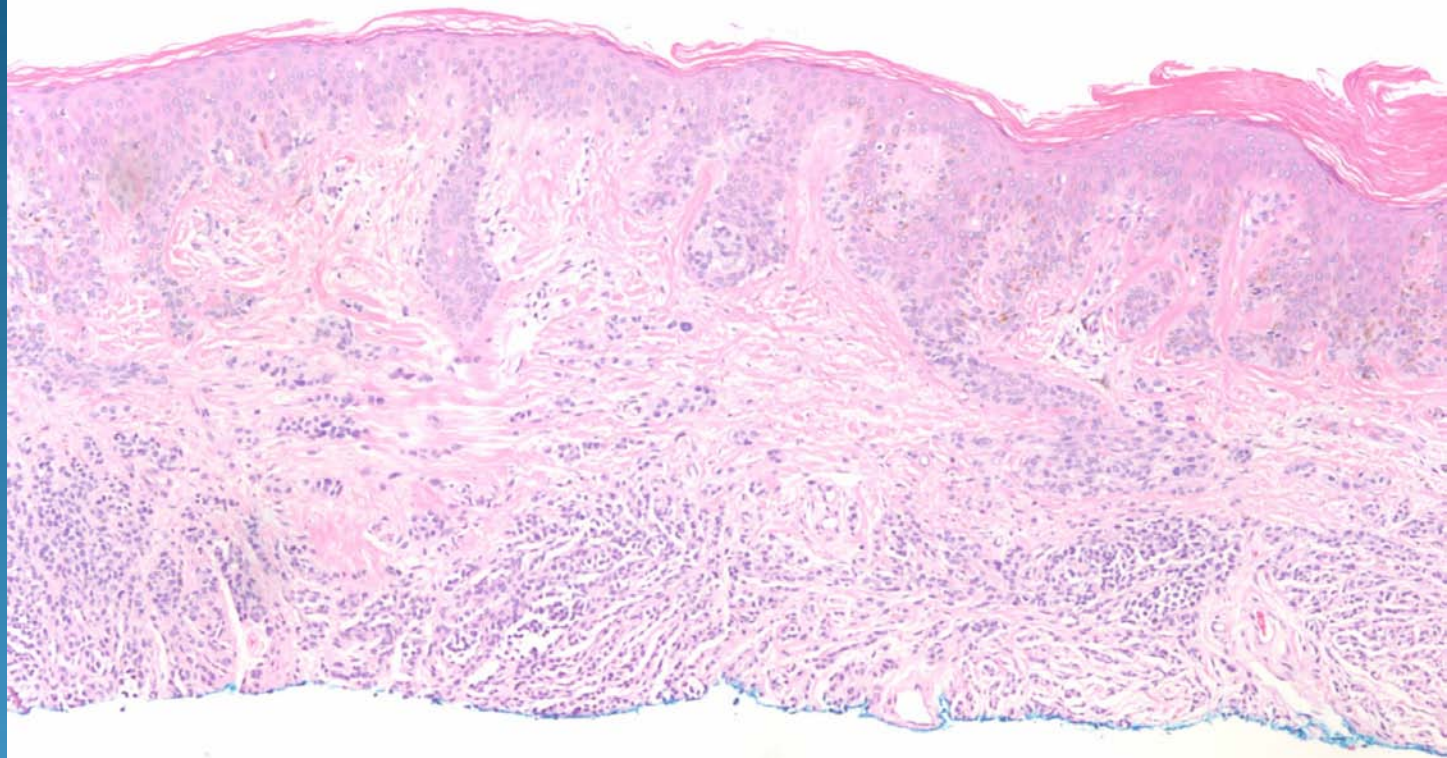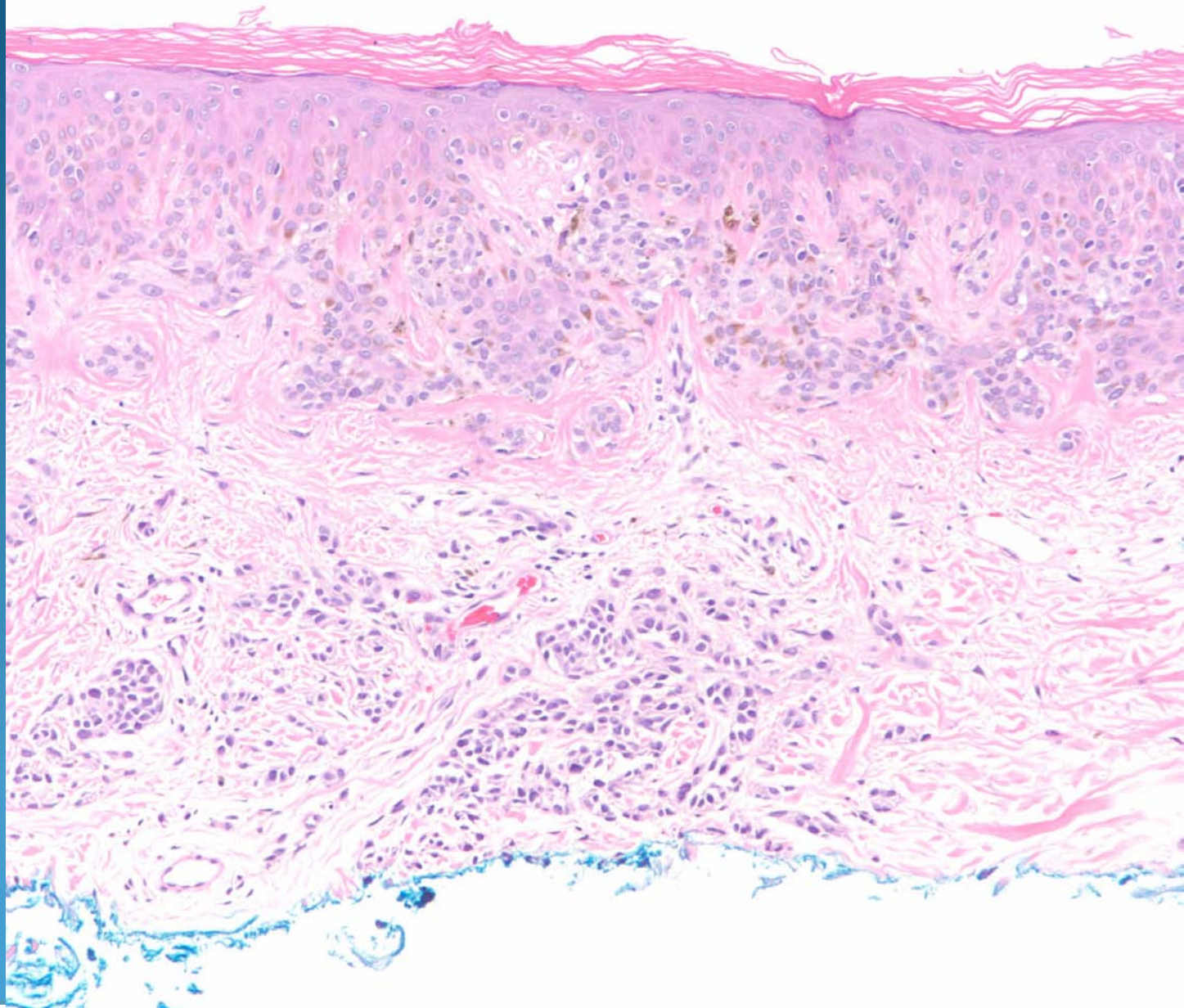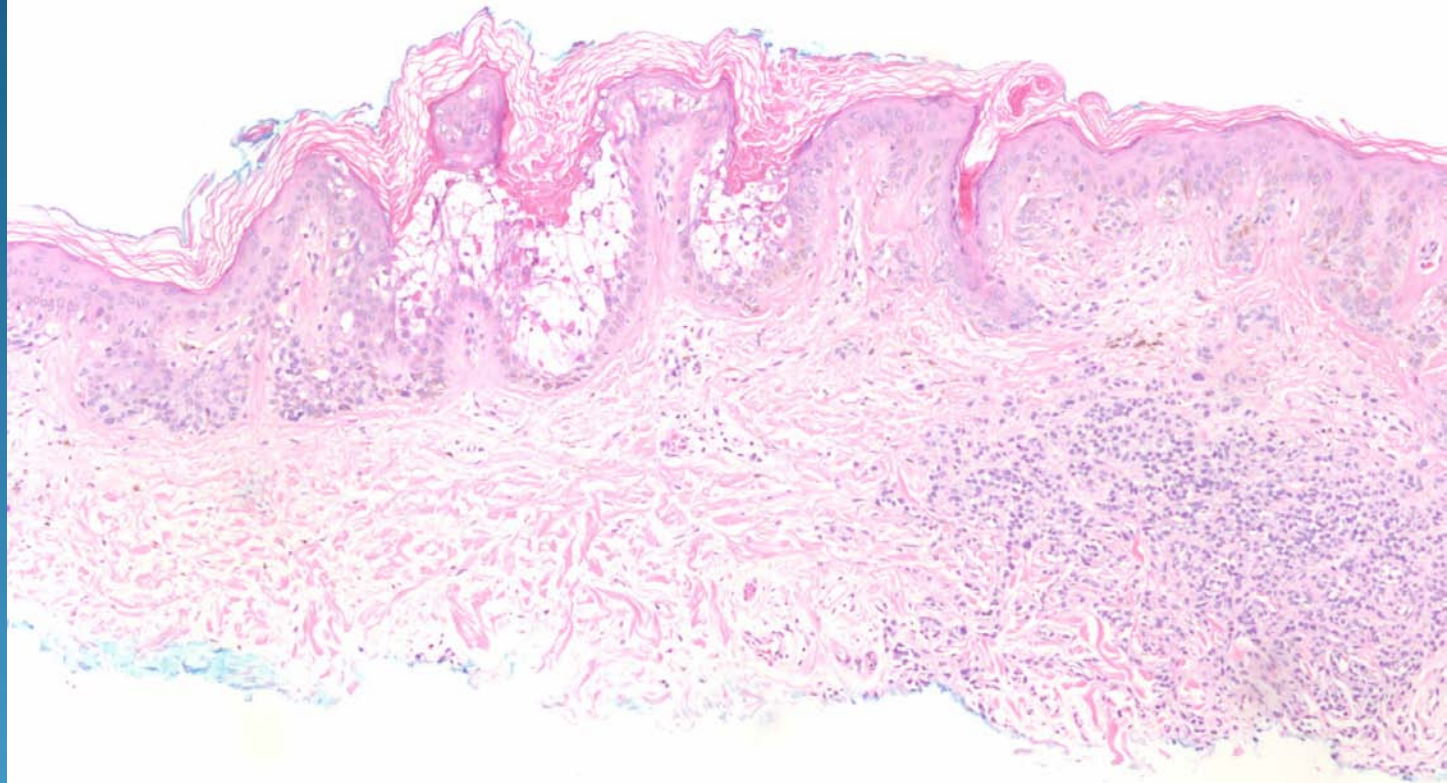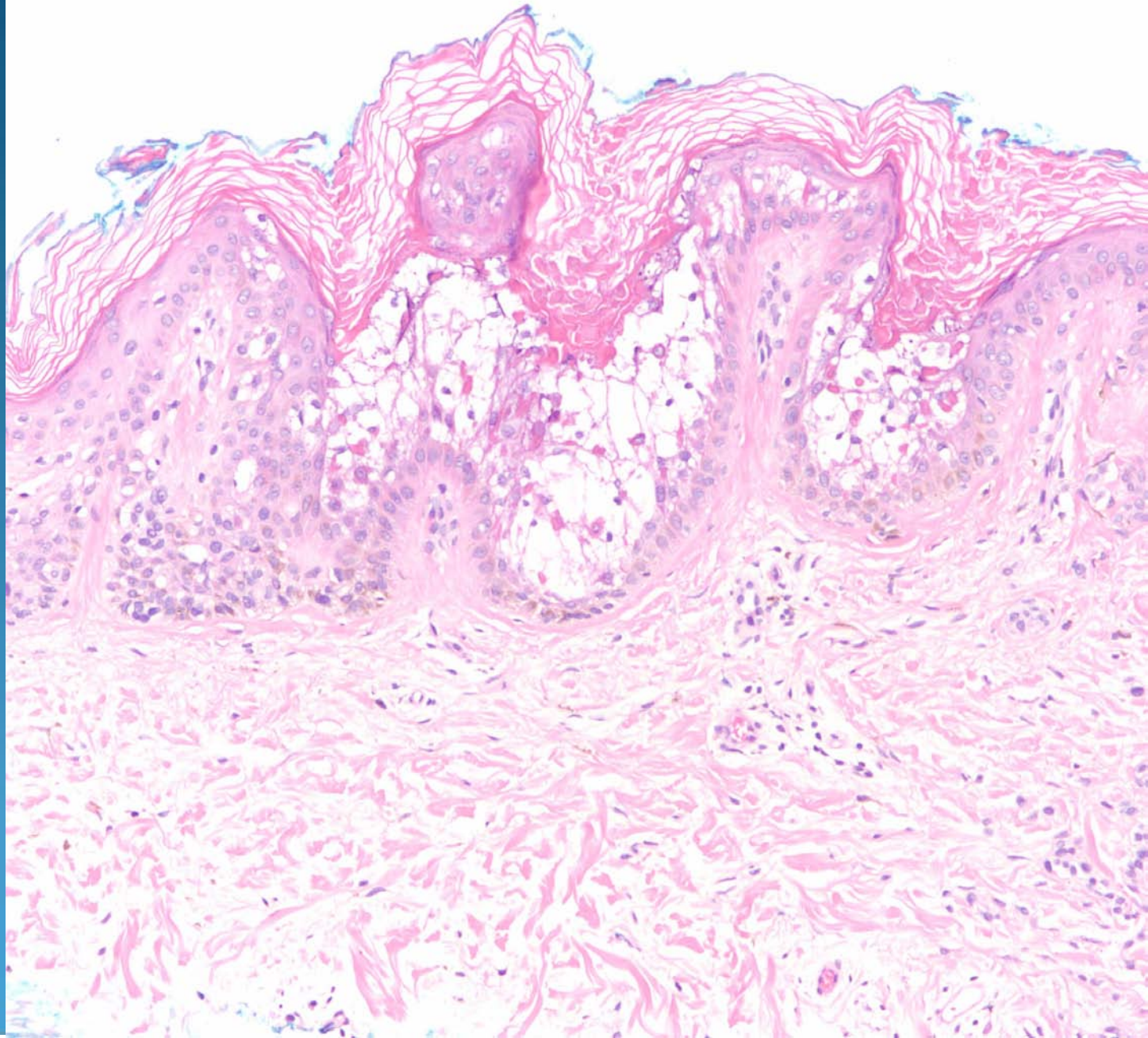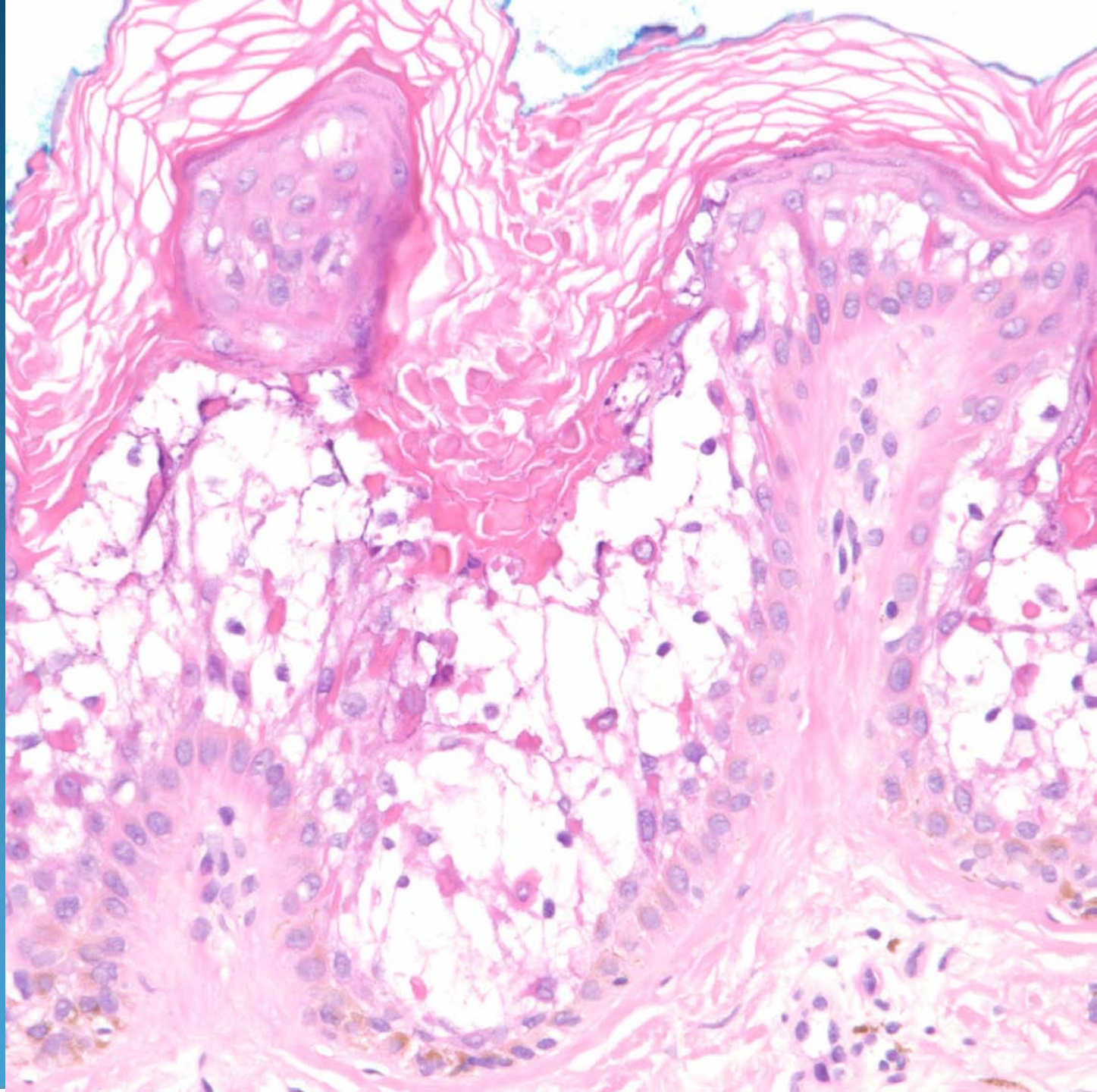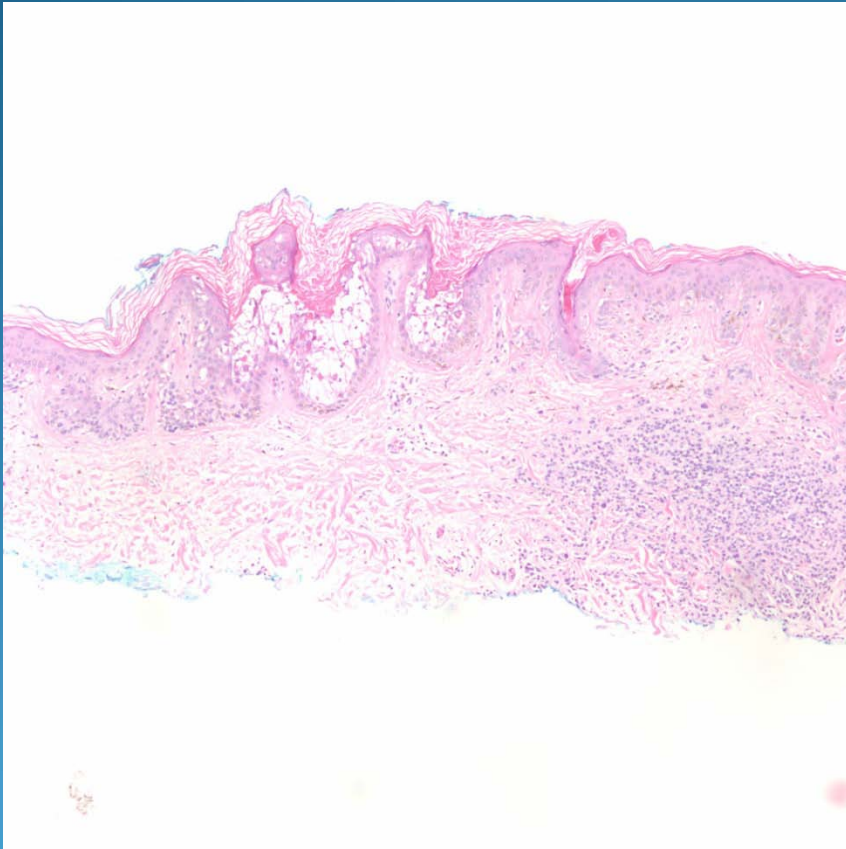


Dysplastic Nevus arising with Epidermolytic Hyperkeratosis

Pearls



- Epidermolytic hyperkeratosis may be a marker for atypical melanocytic nevi
- If seen in an otherwise banal melanocytic nevus, cut deeper to rule out an atypical melanocytic nevus