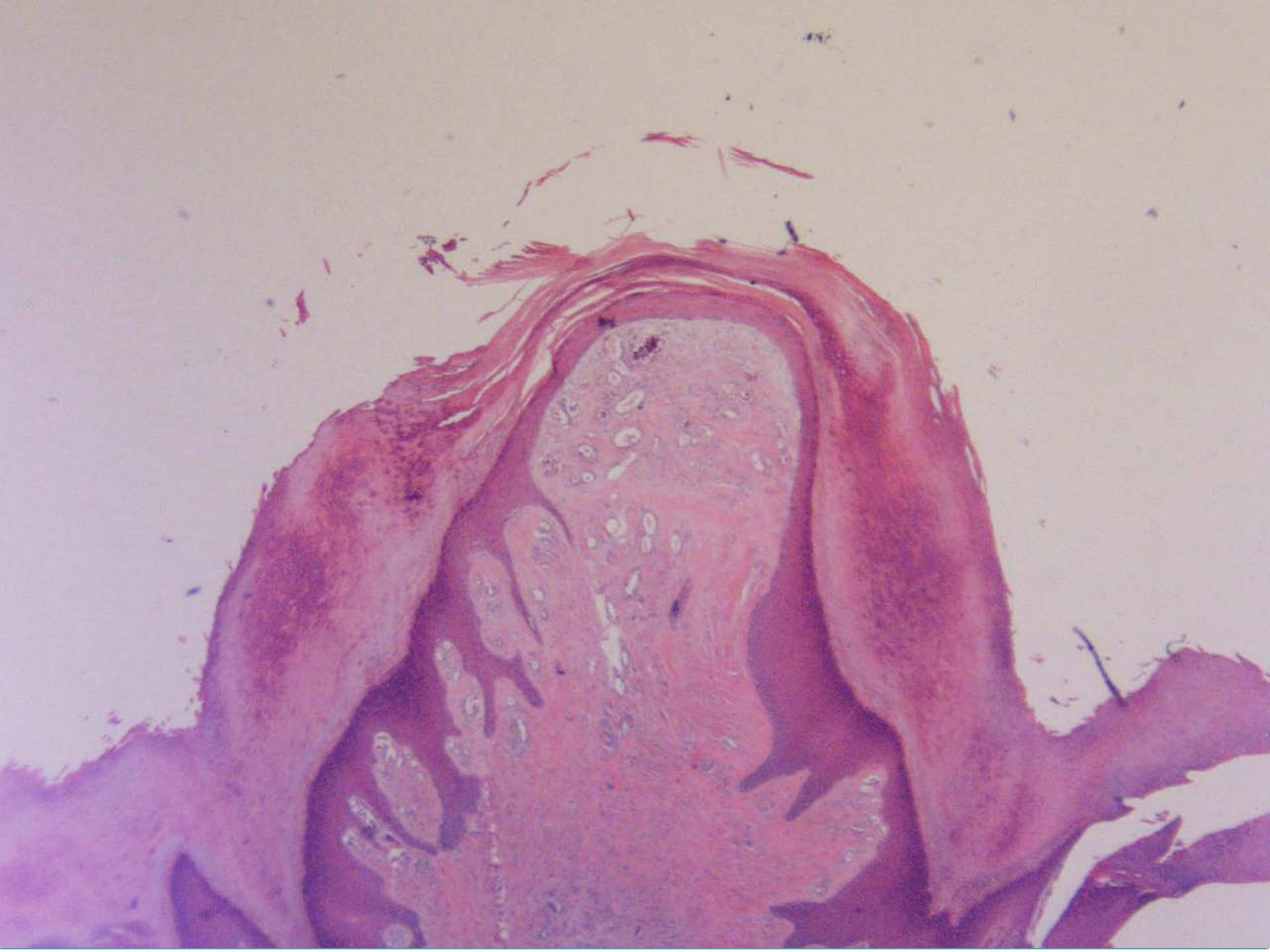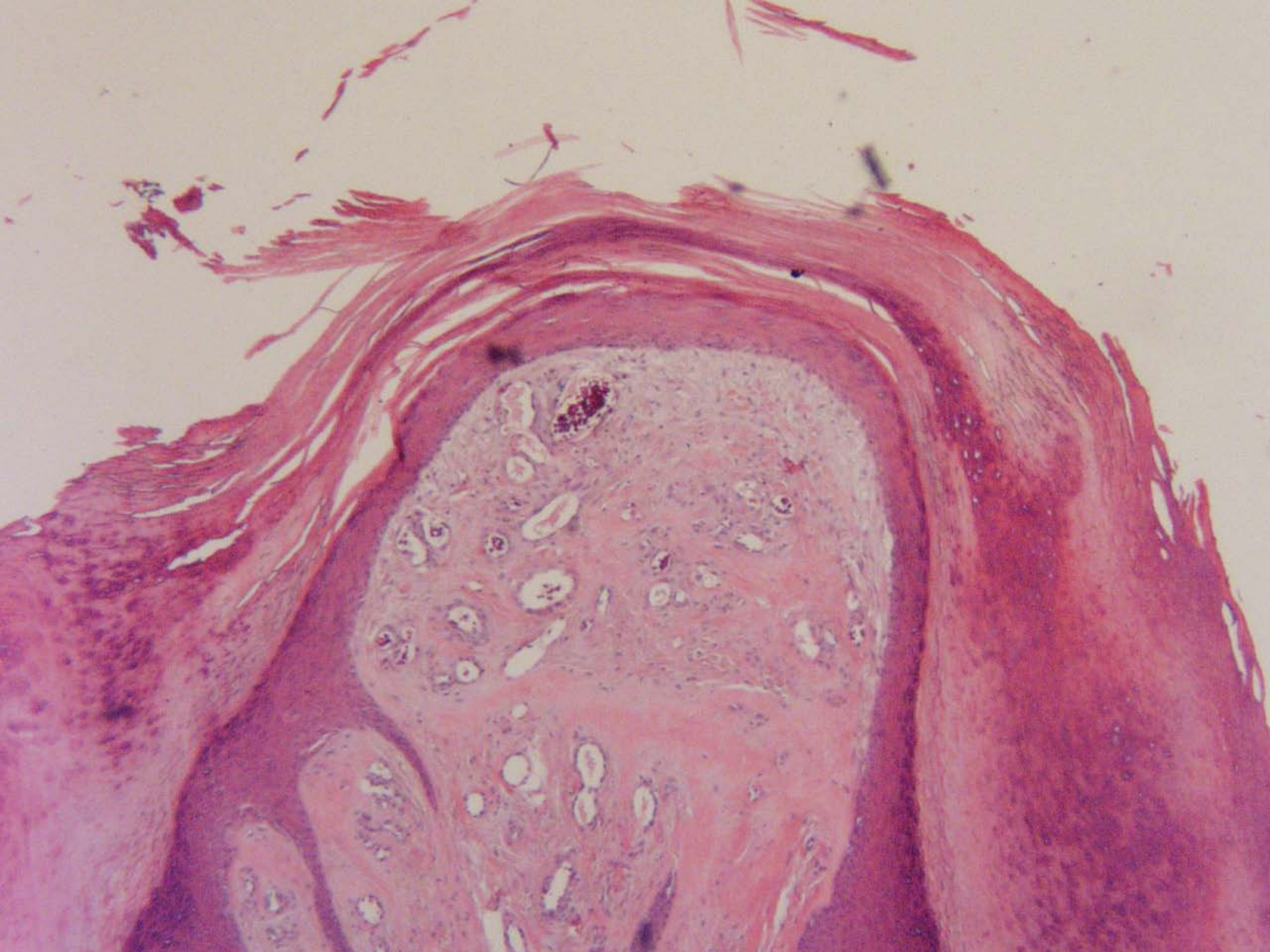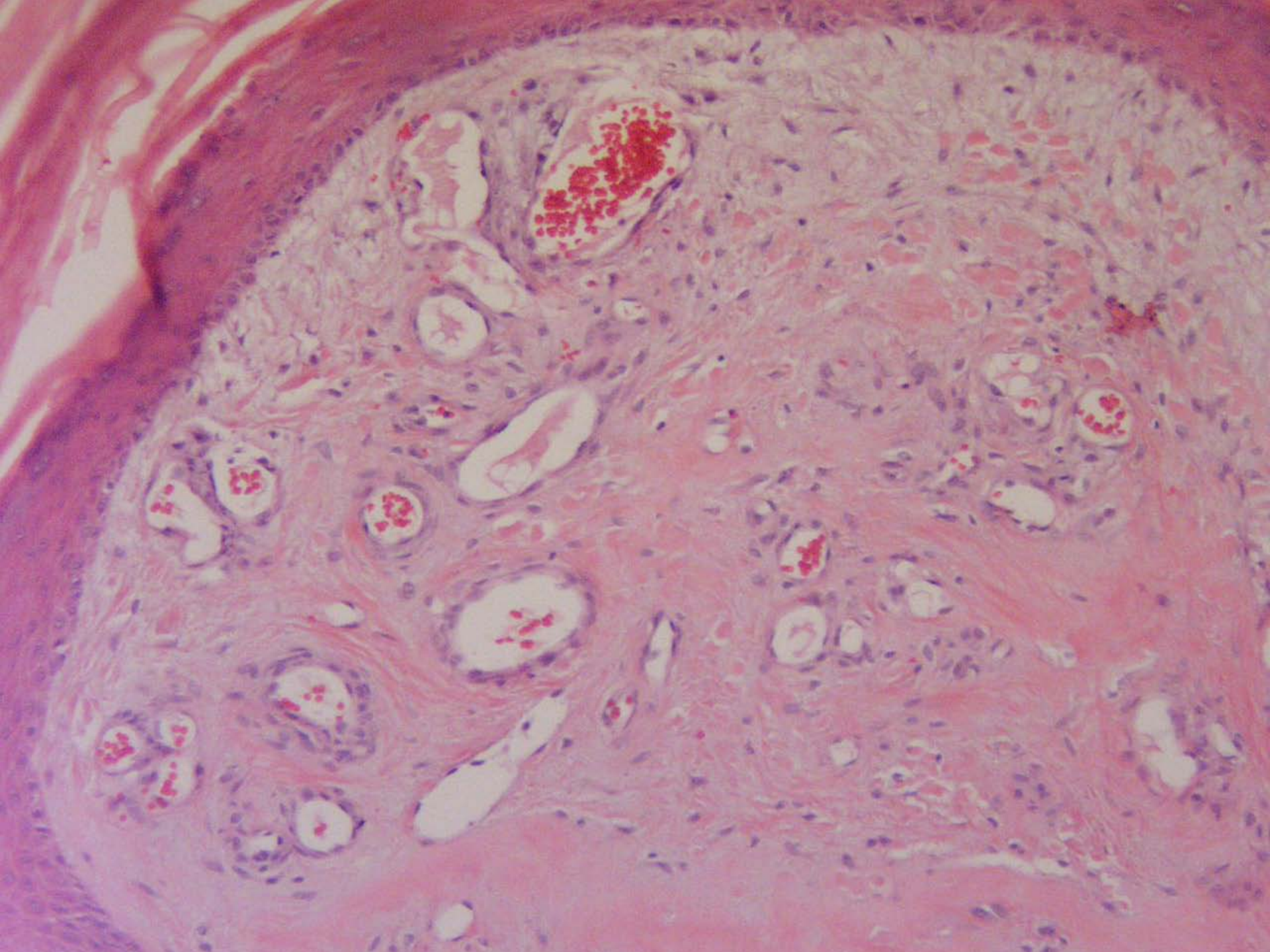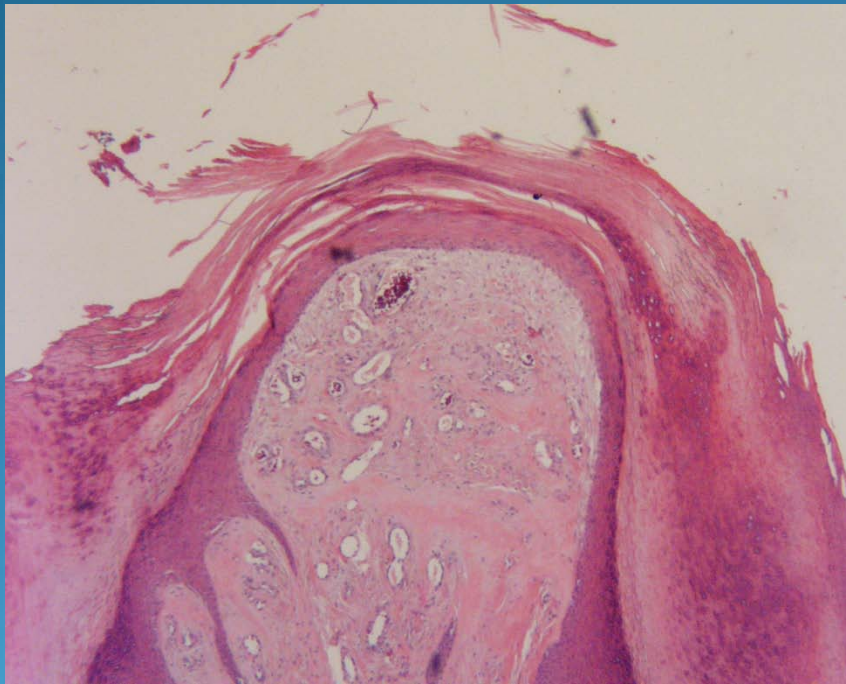


# Digital Fibrokeratoma

# Pearls



- Acral location
- Polypoid lesion with vertical streaking collagen and capillary sized vessels
- No nerve bundles-rule out supernumerary digit
- No viral cytopathic changes-rule out verruca vulgaris