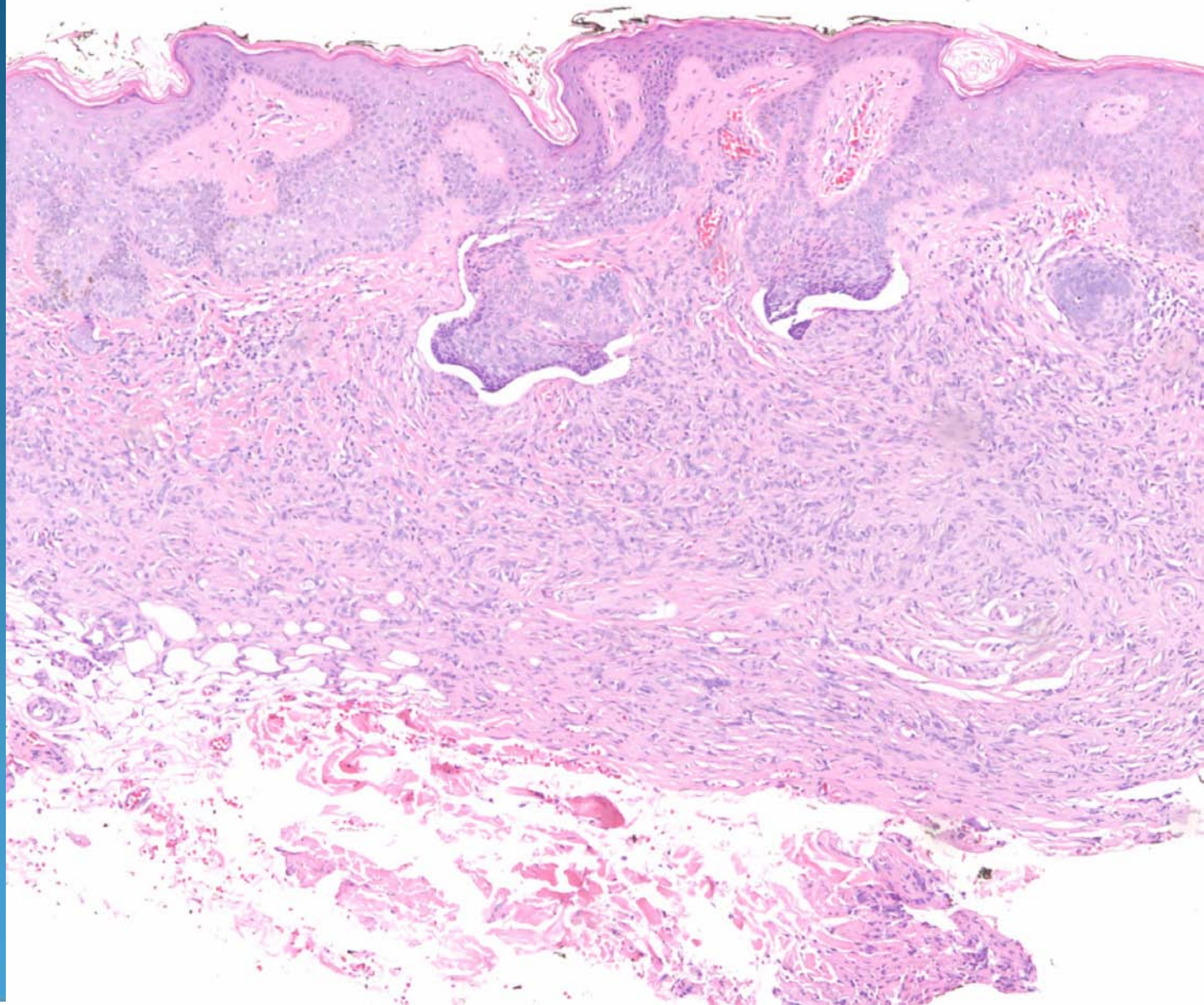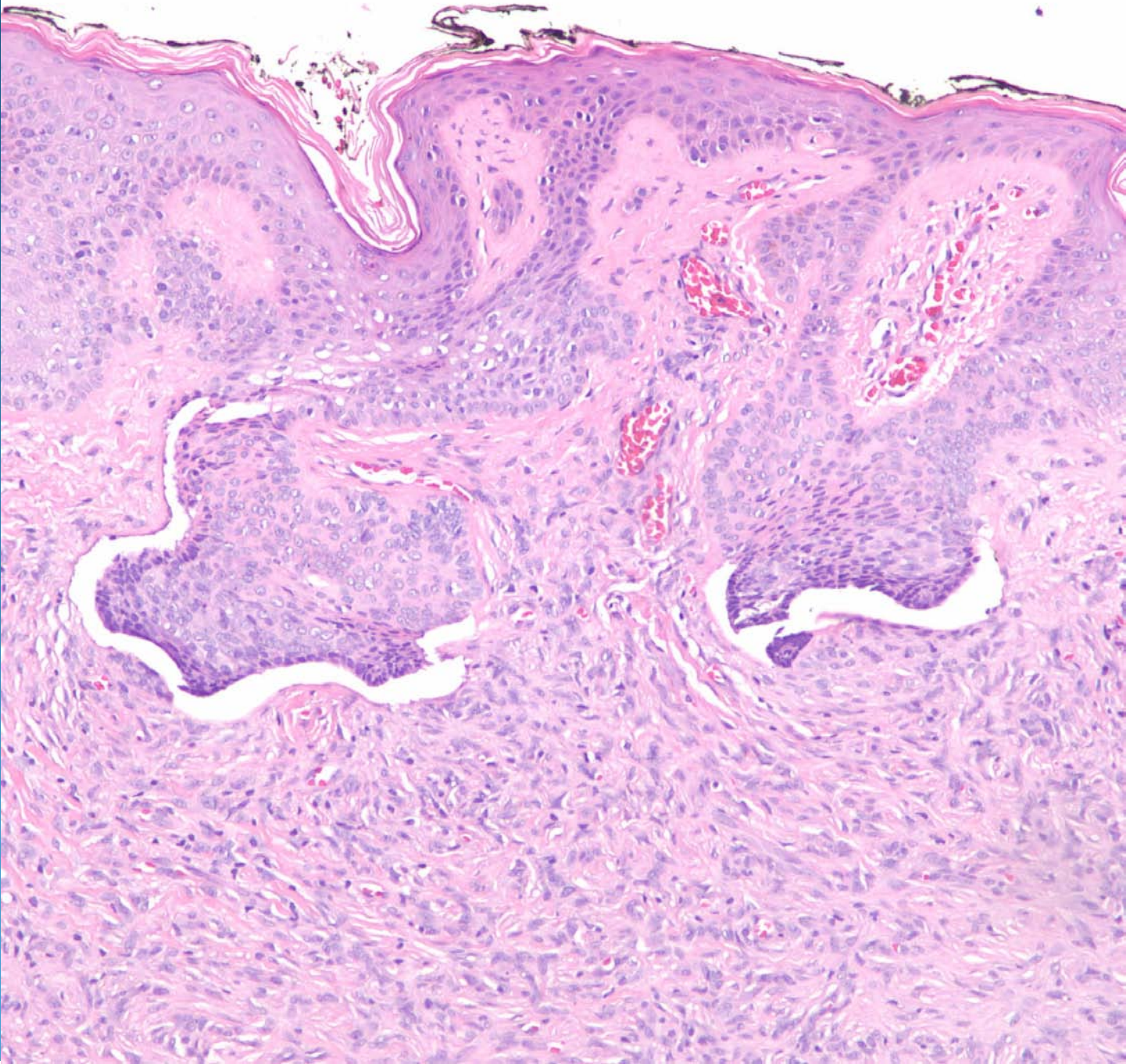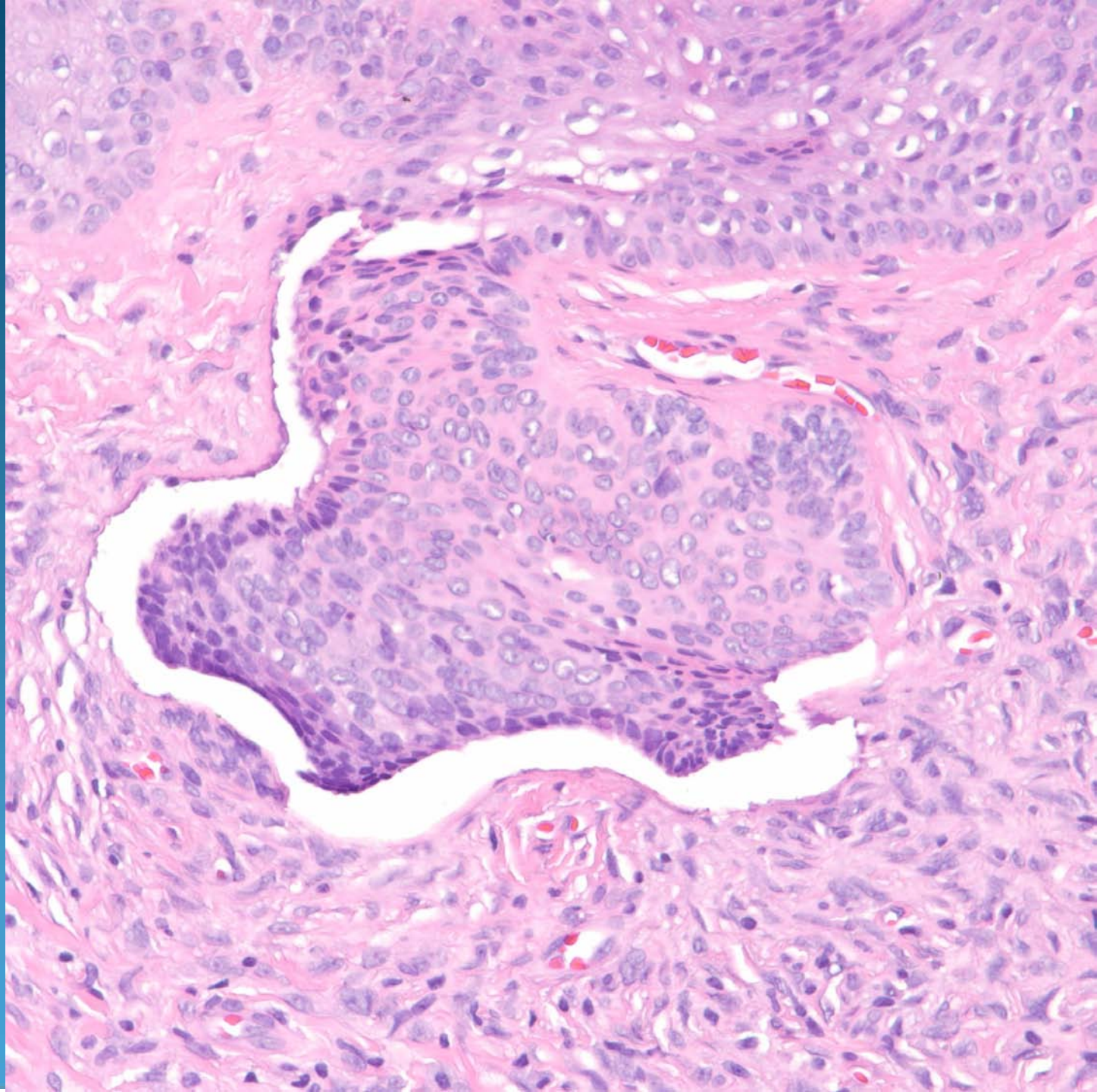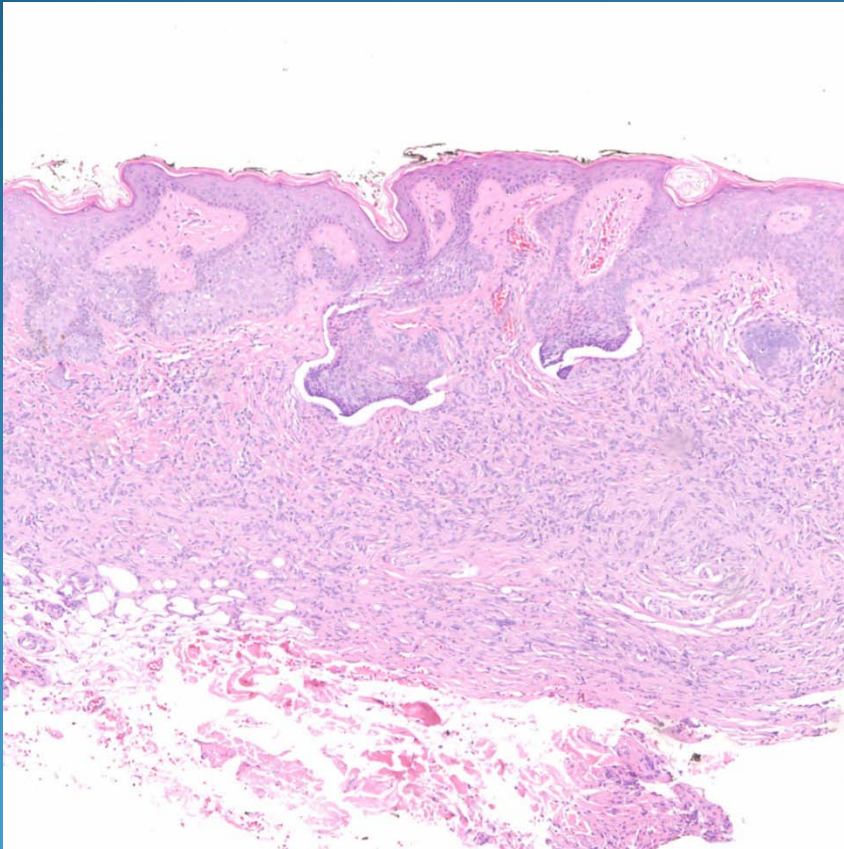


Dermatofibroma with Basaloid Follicular Induction

Pearls



- Classic dermatofibroma with basaloid follicular induction mimicking a basal cell carcinoma
- Note the characteristic spindle cells as well as primitive or abortive follicular structures
- Epidermis usually hyperplastic