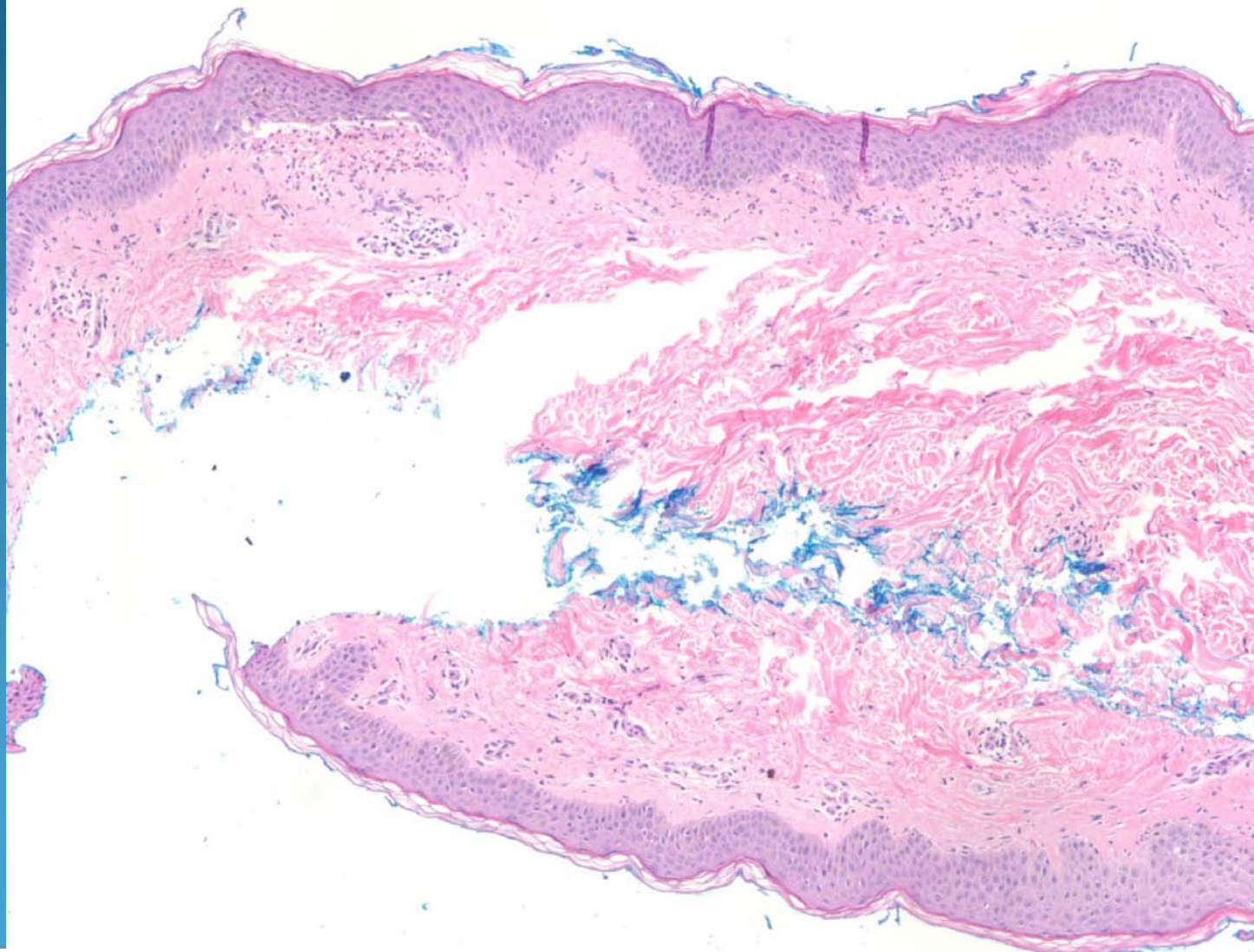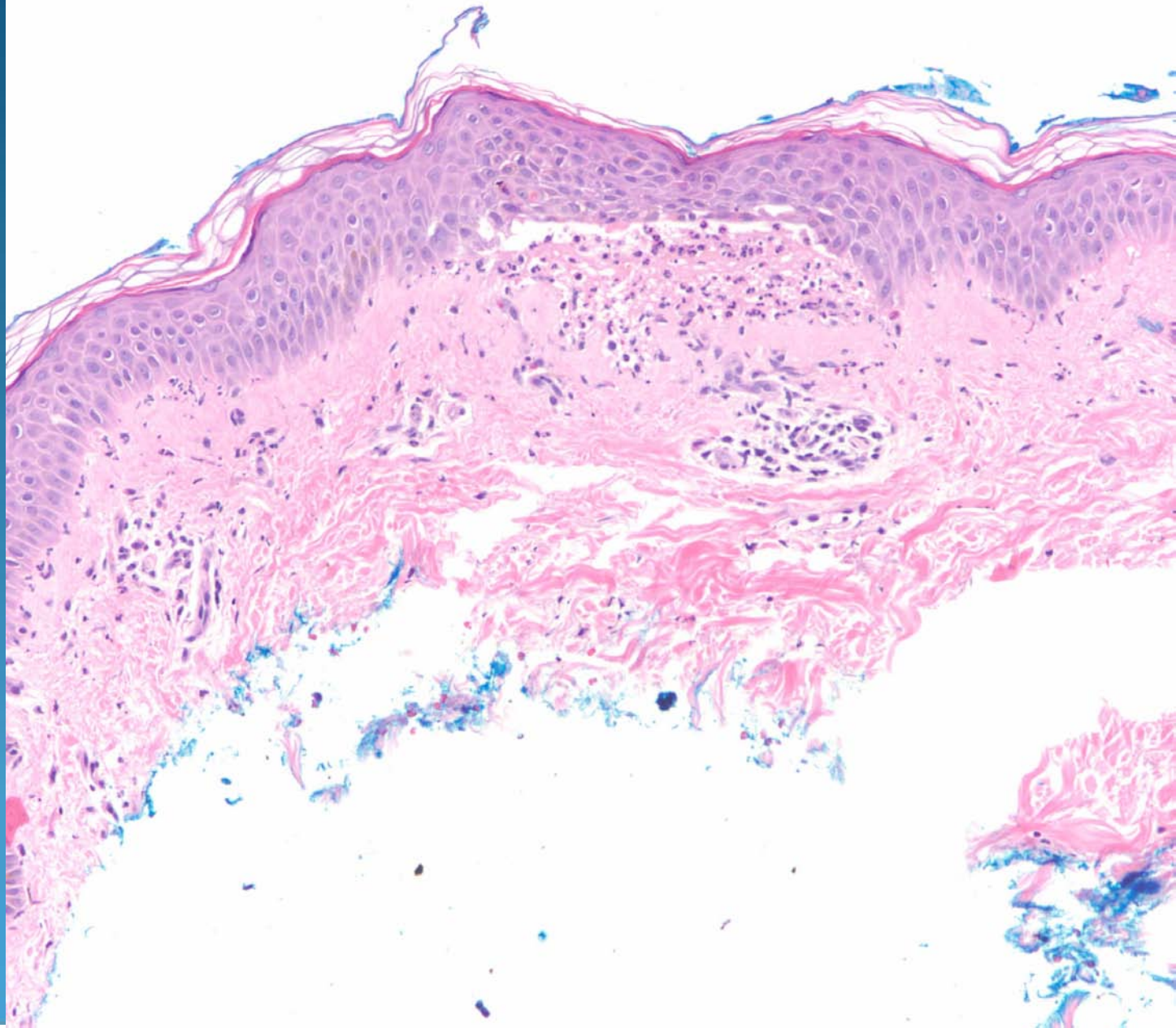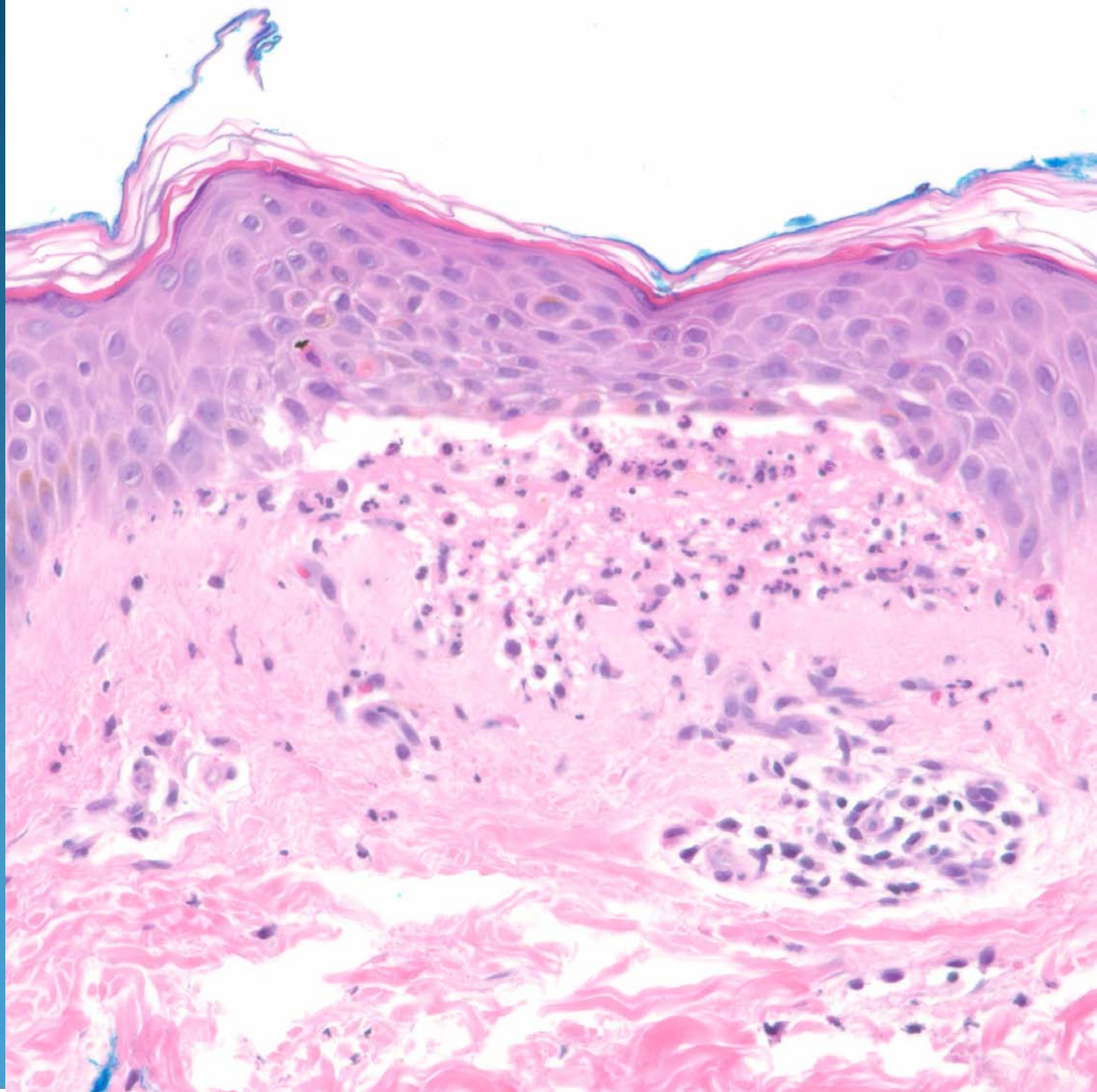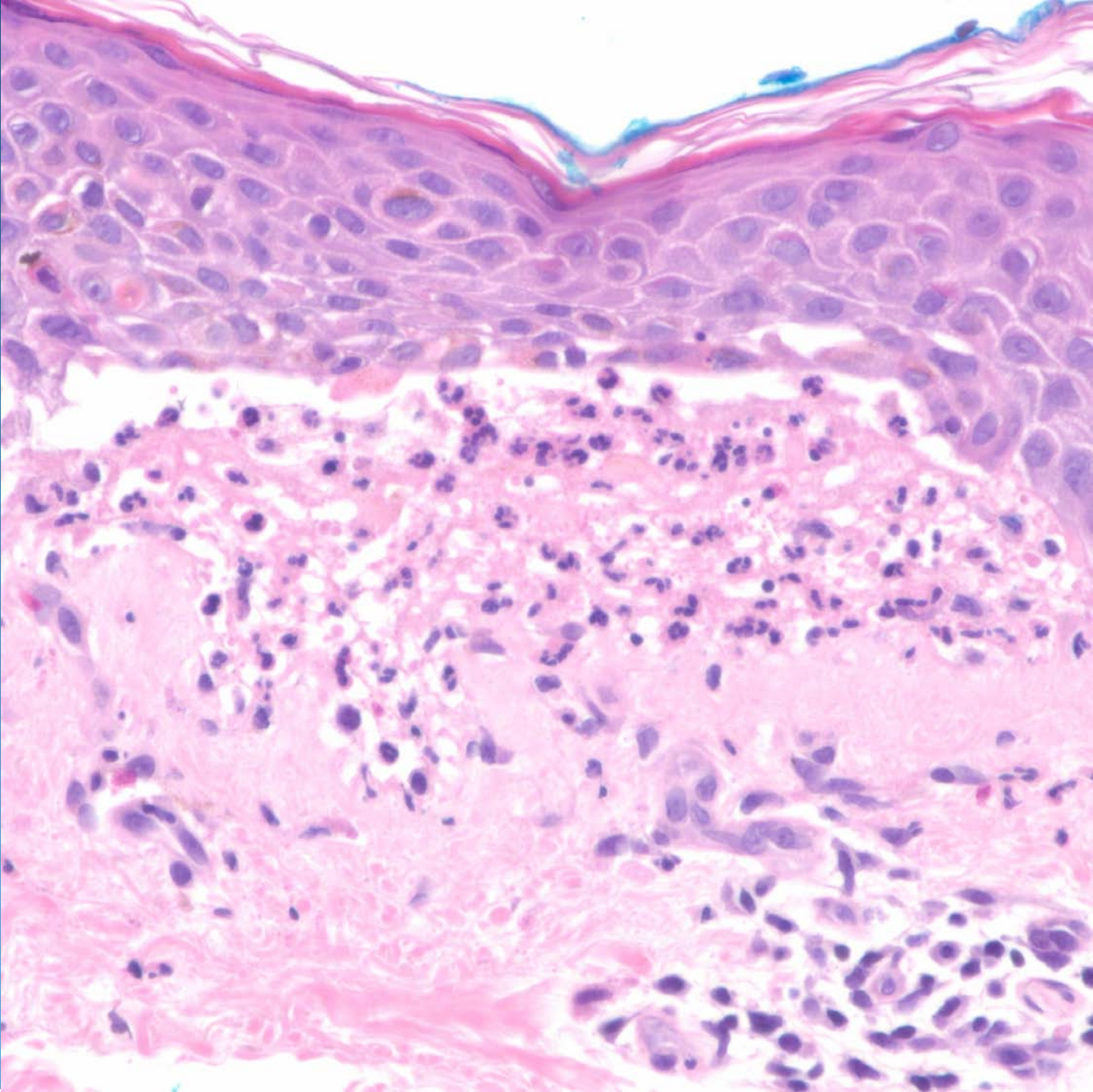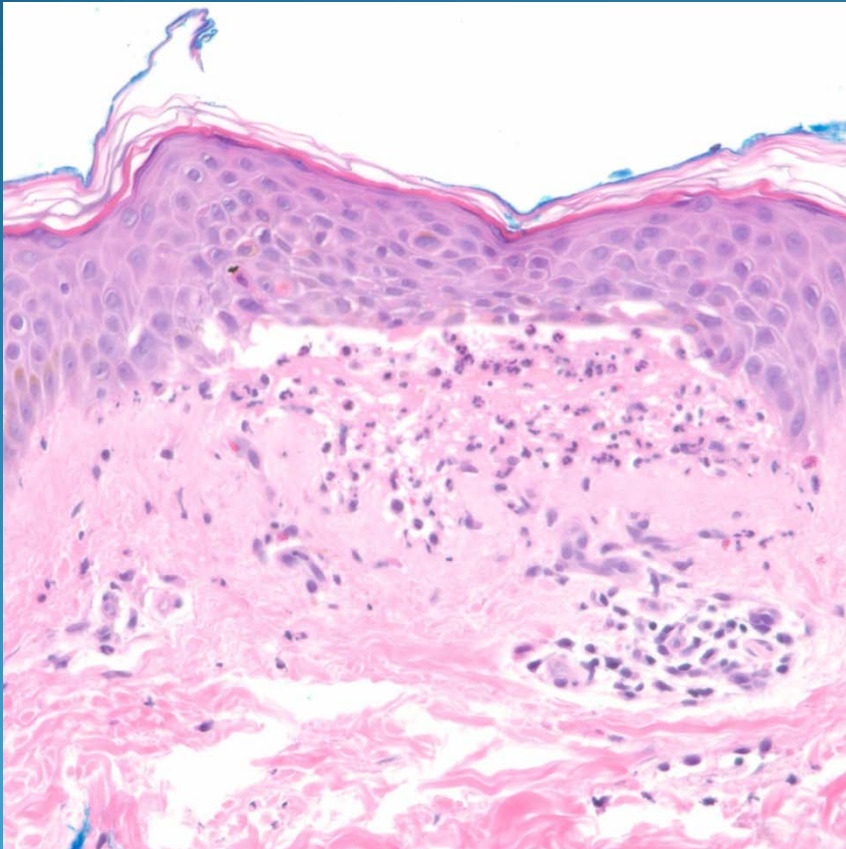


Dermatitis herpetiformis

Pearls



- Subepithelial collections of neutrophils forming papillary dermal microabscesses
- Minimal eosinophils
- Histologically identical to Linear IgA disease—distinguish by DIF
- DDX: Bullous pemphigoid, EBA, bullous LE