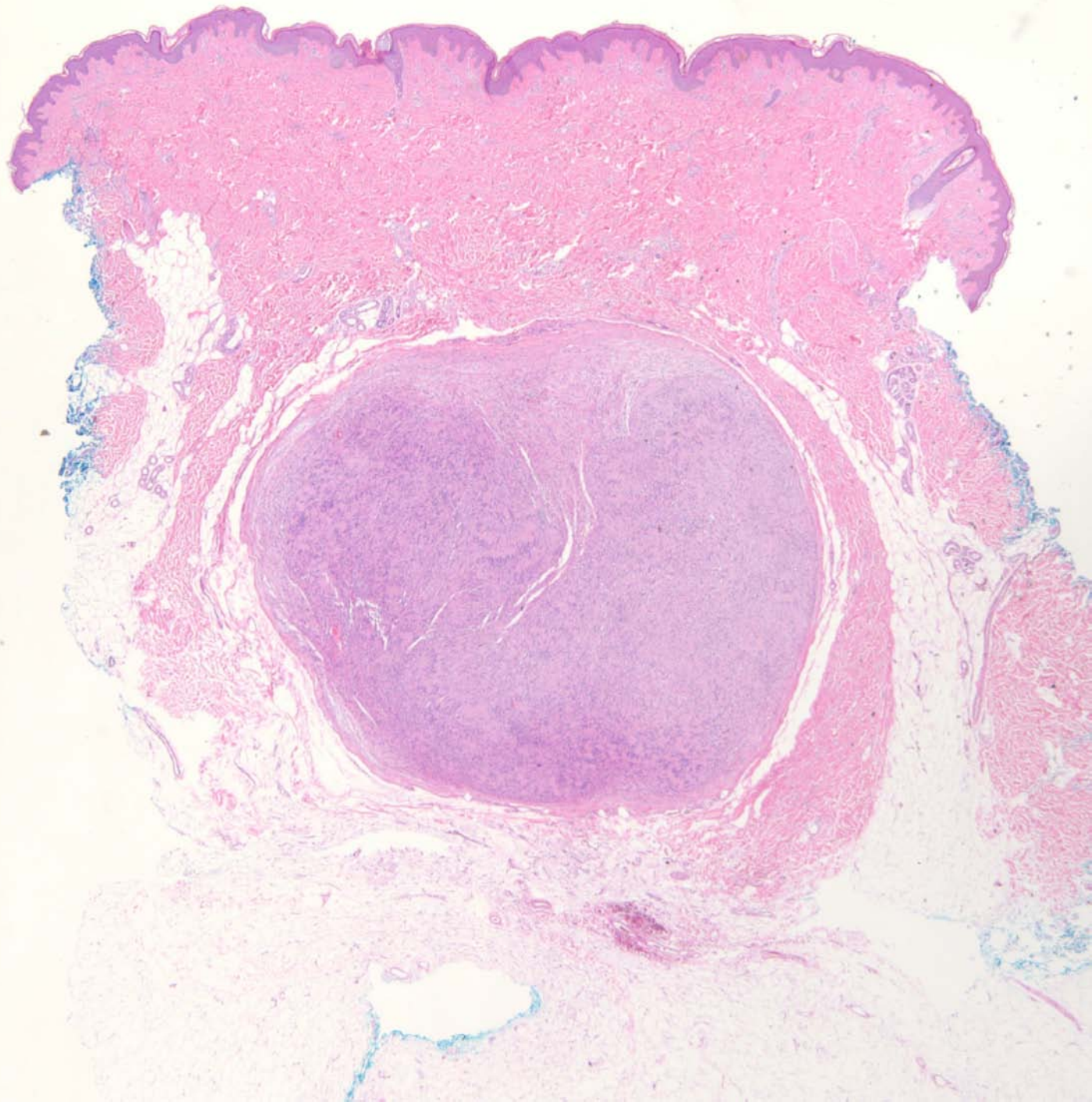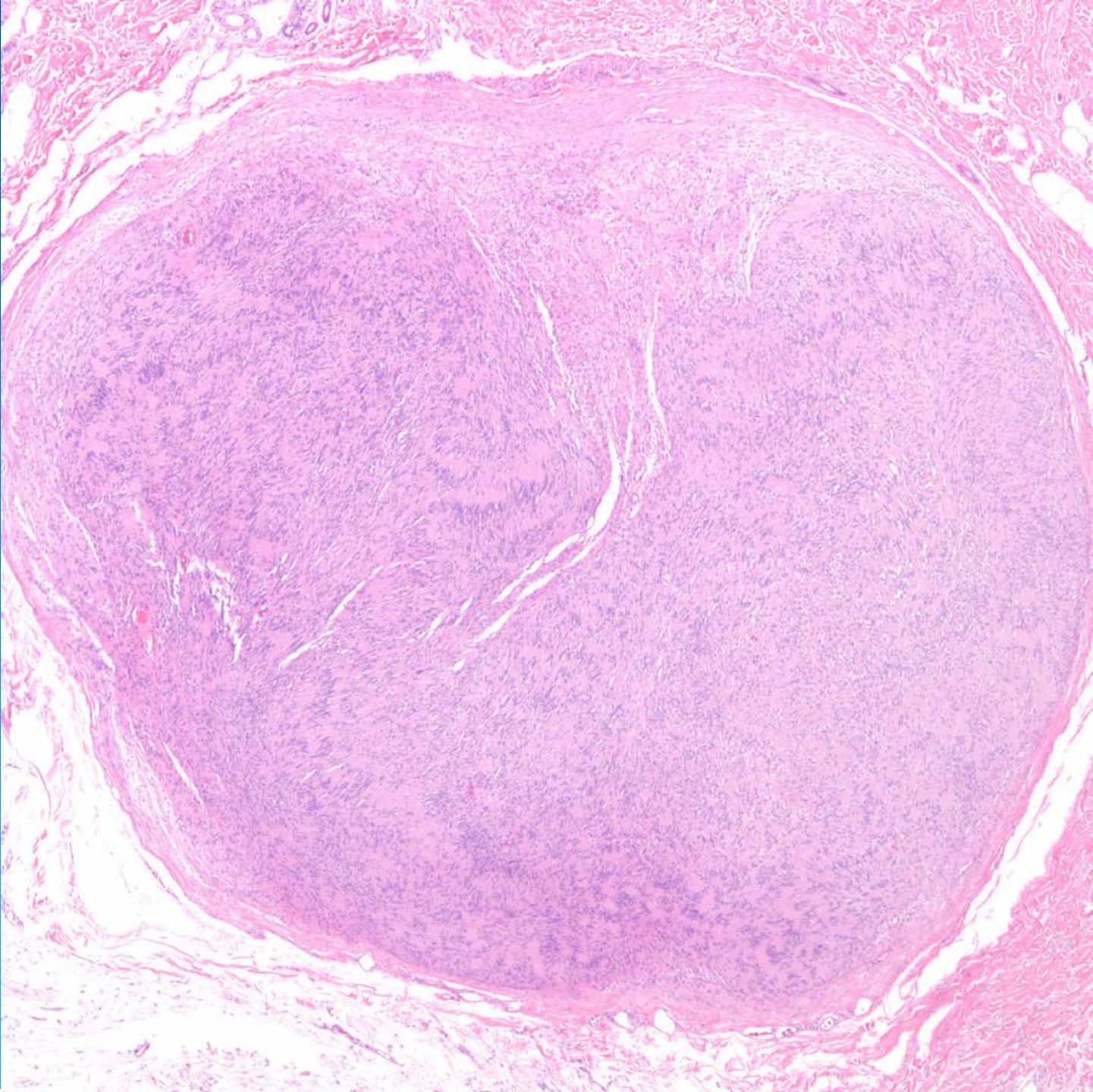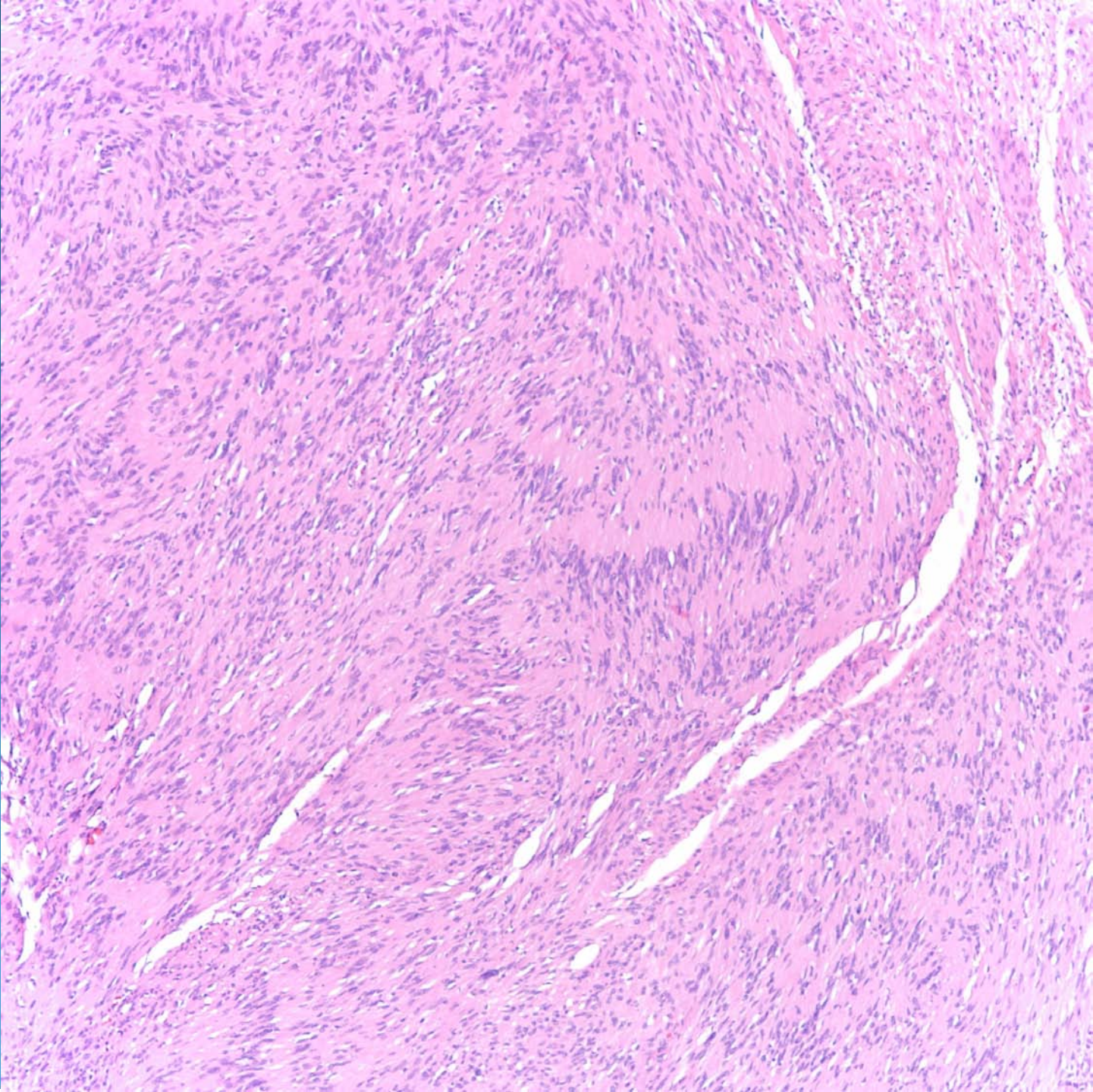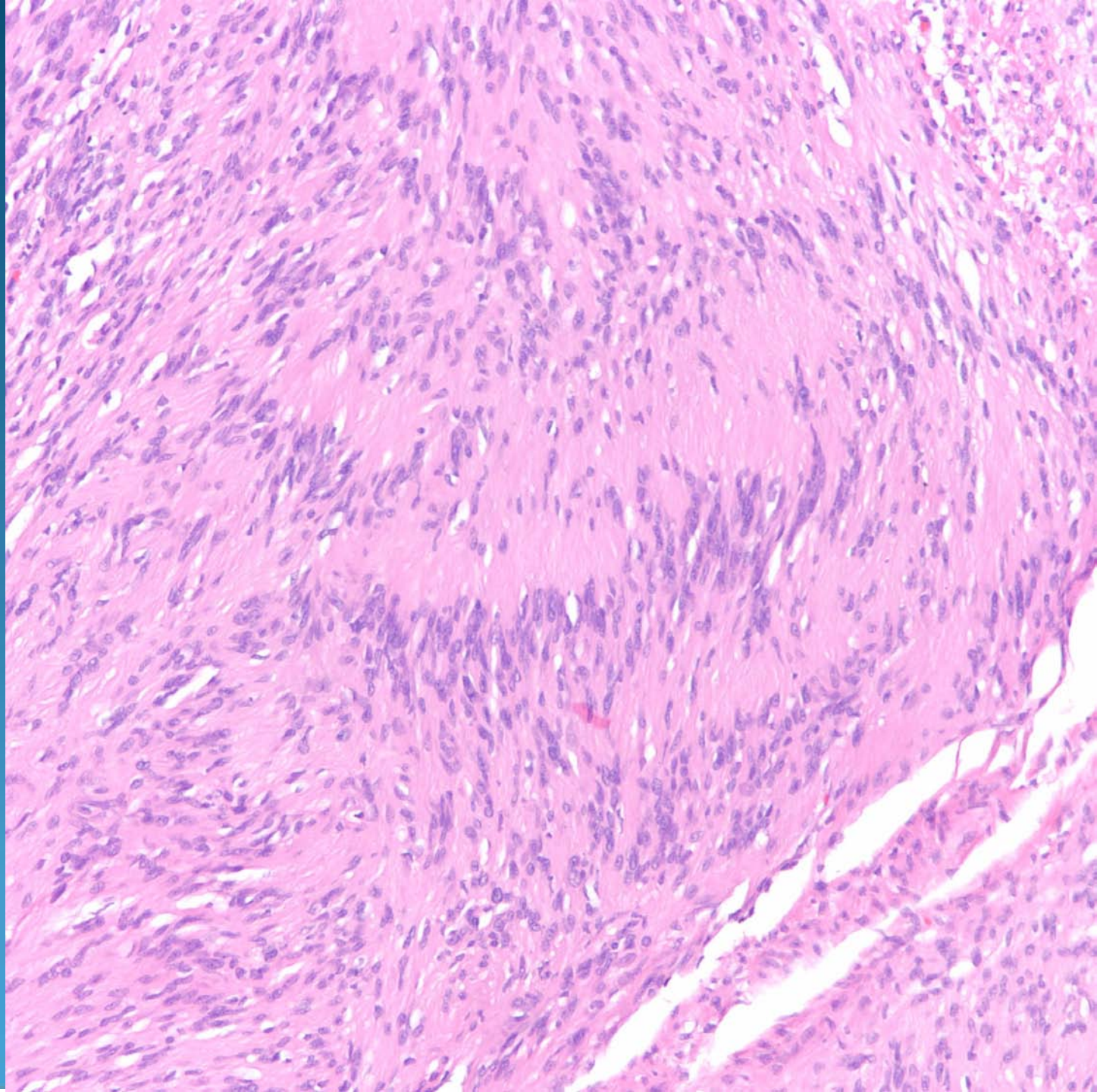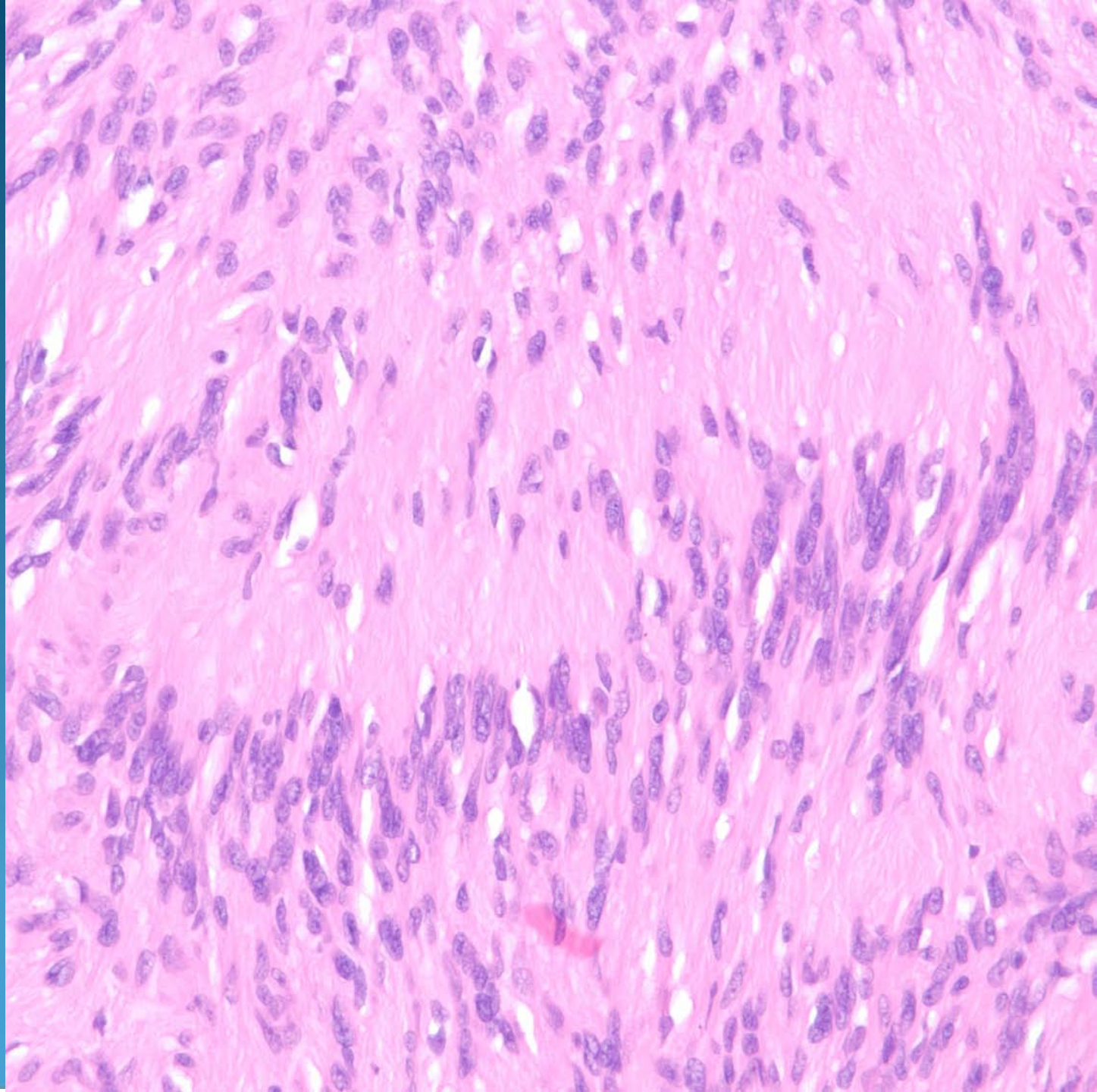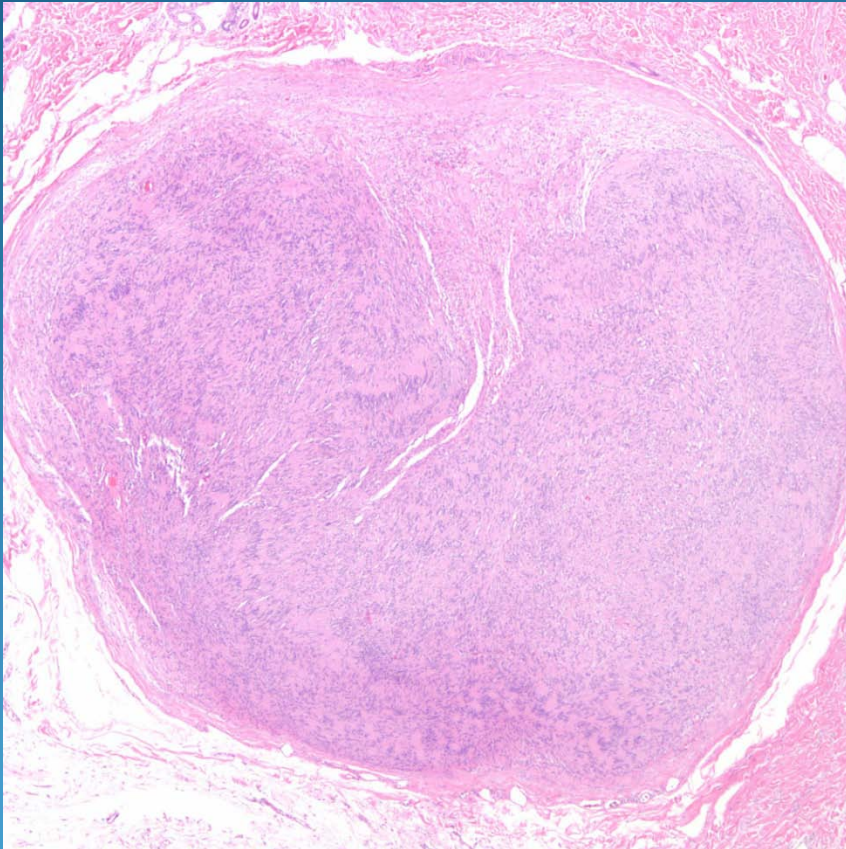


Cutaneous Schwannoma

Pearls



- Circumscribed dermal neoplasm, may extend into subcutaneous adipose tissue
- Wavy nuclei in myxoid stroma
- Palisading of nuclei form characteristic Verocay bodies
- DDX: Palisaded and encapsulated neuroma - this is S100 - EMA+