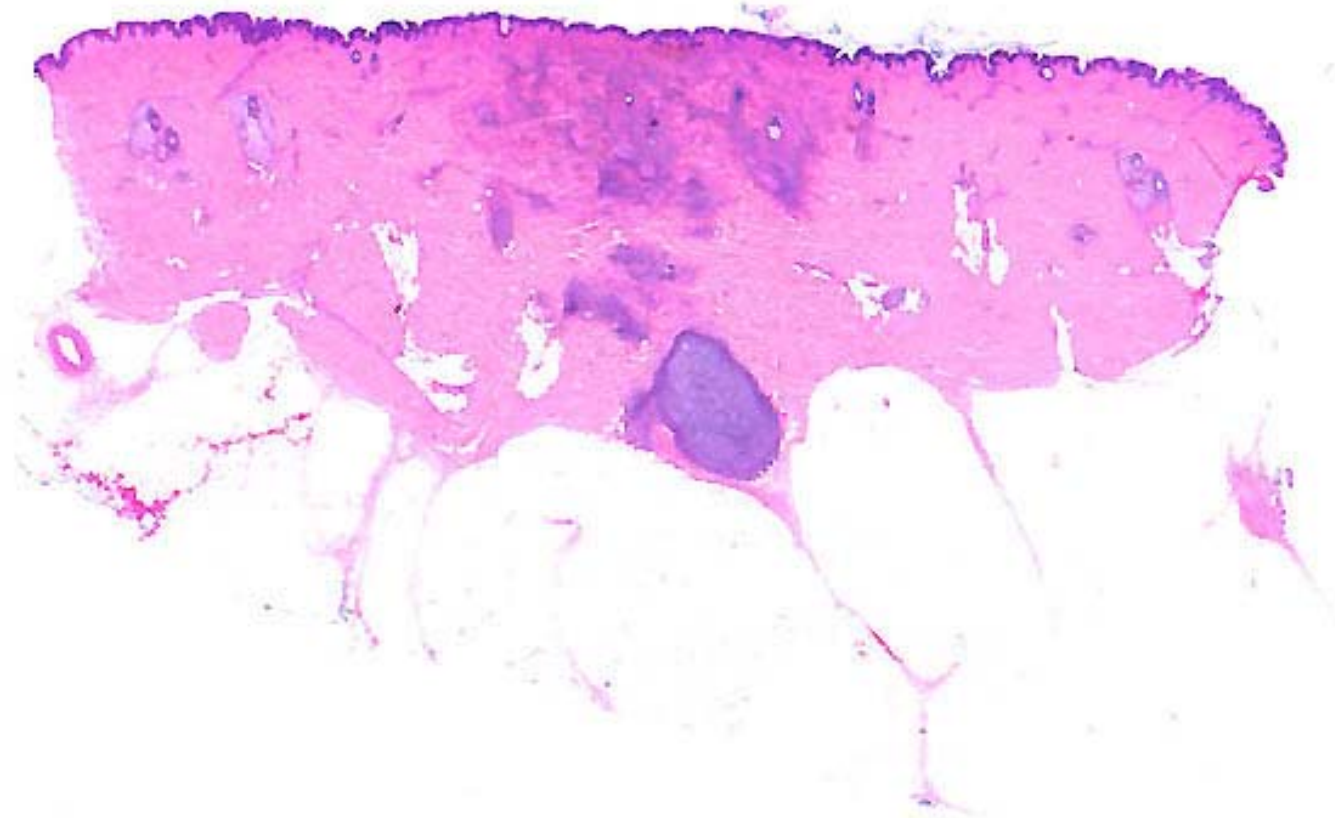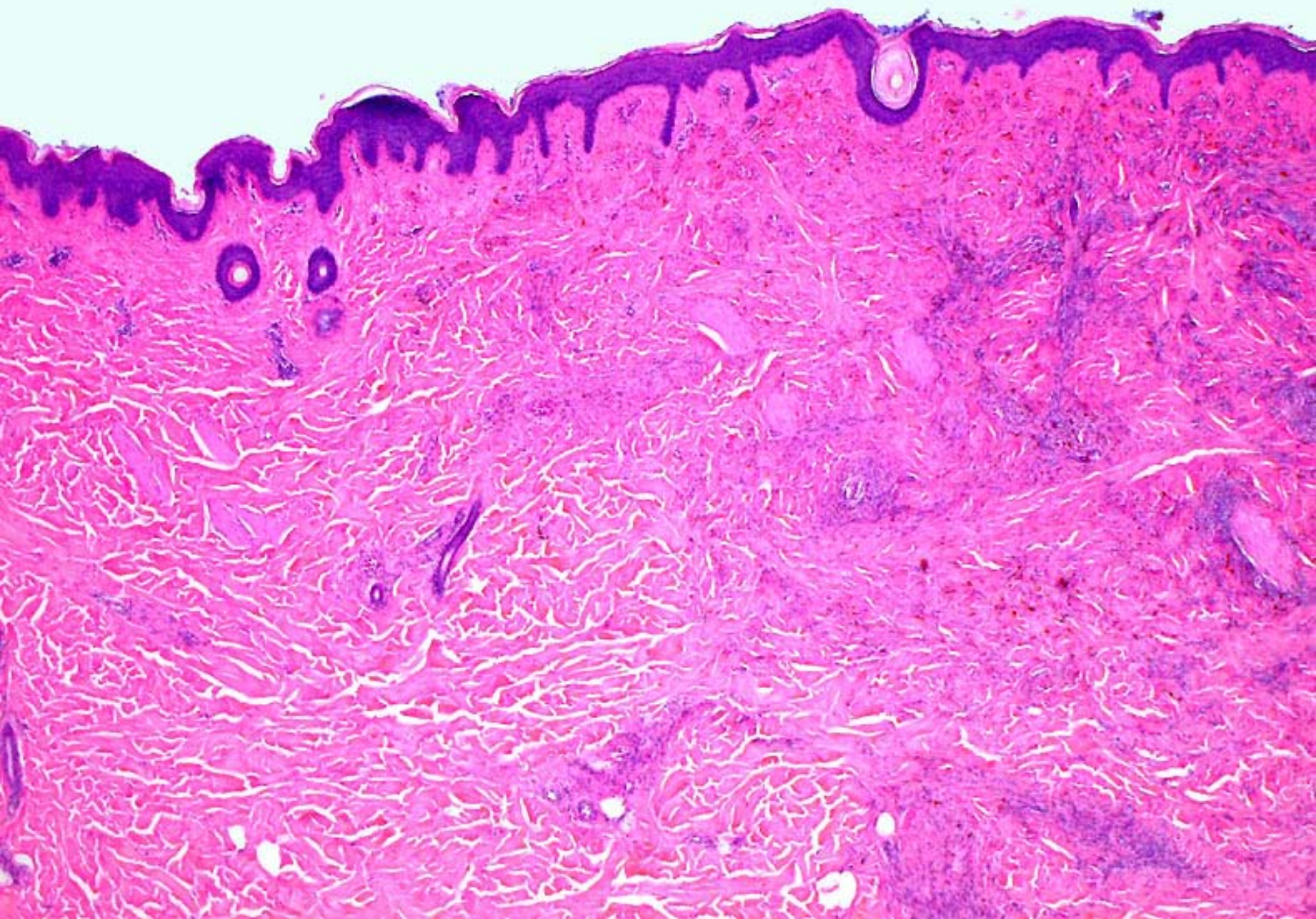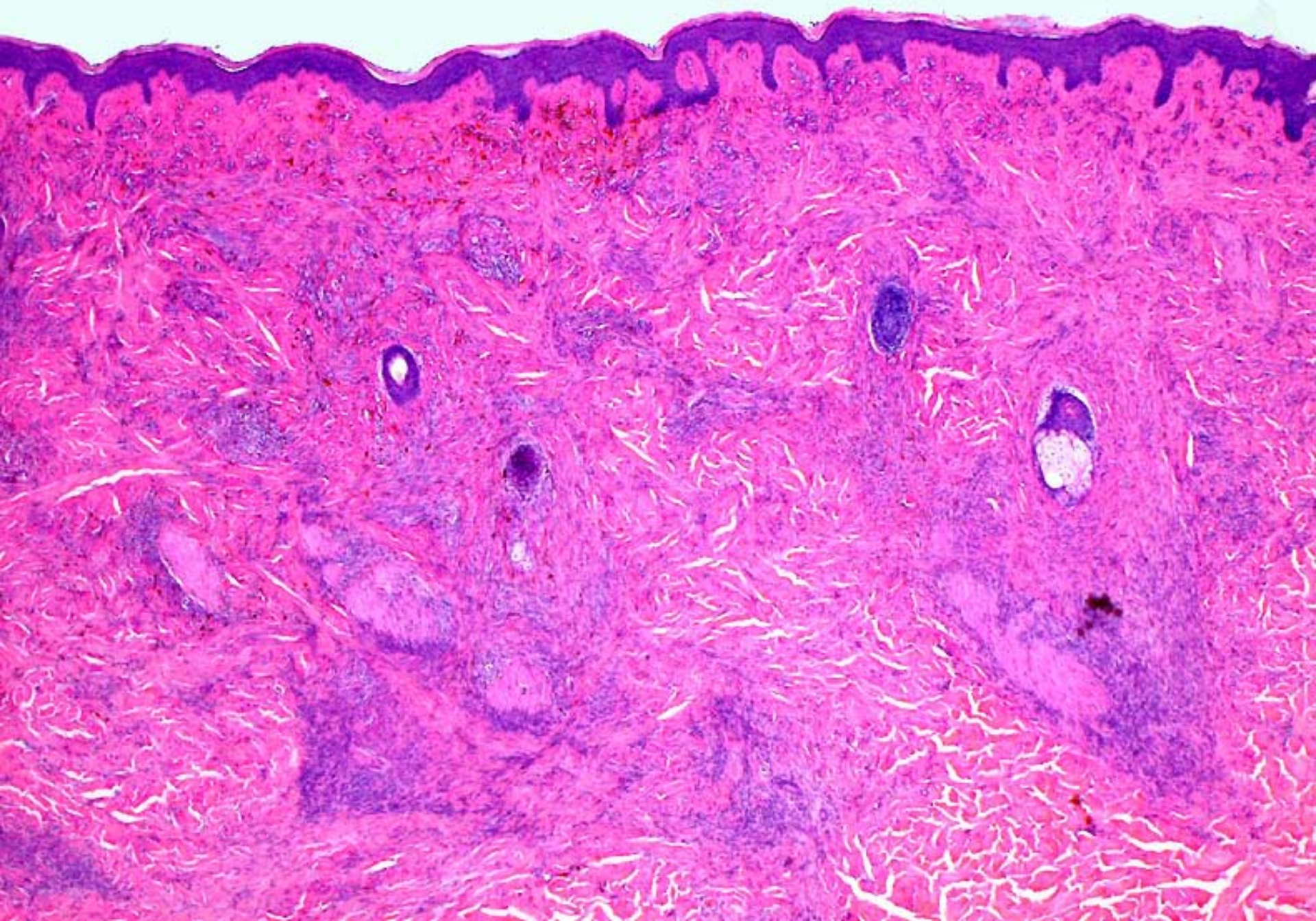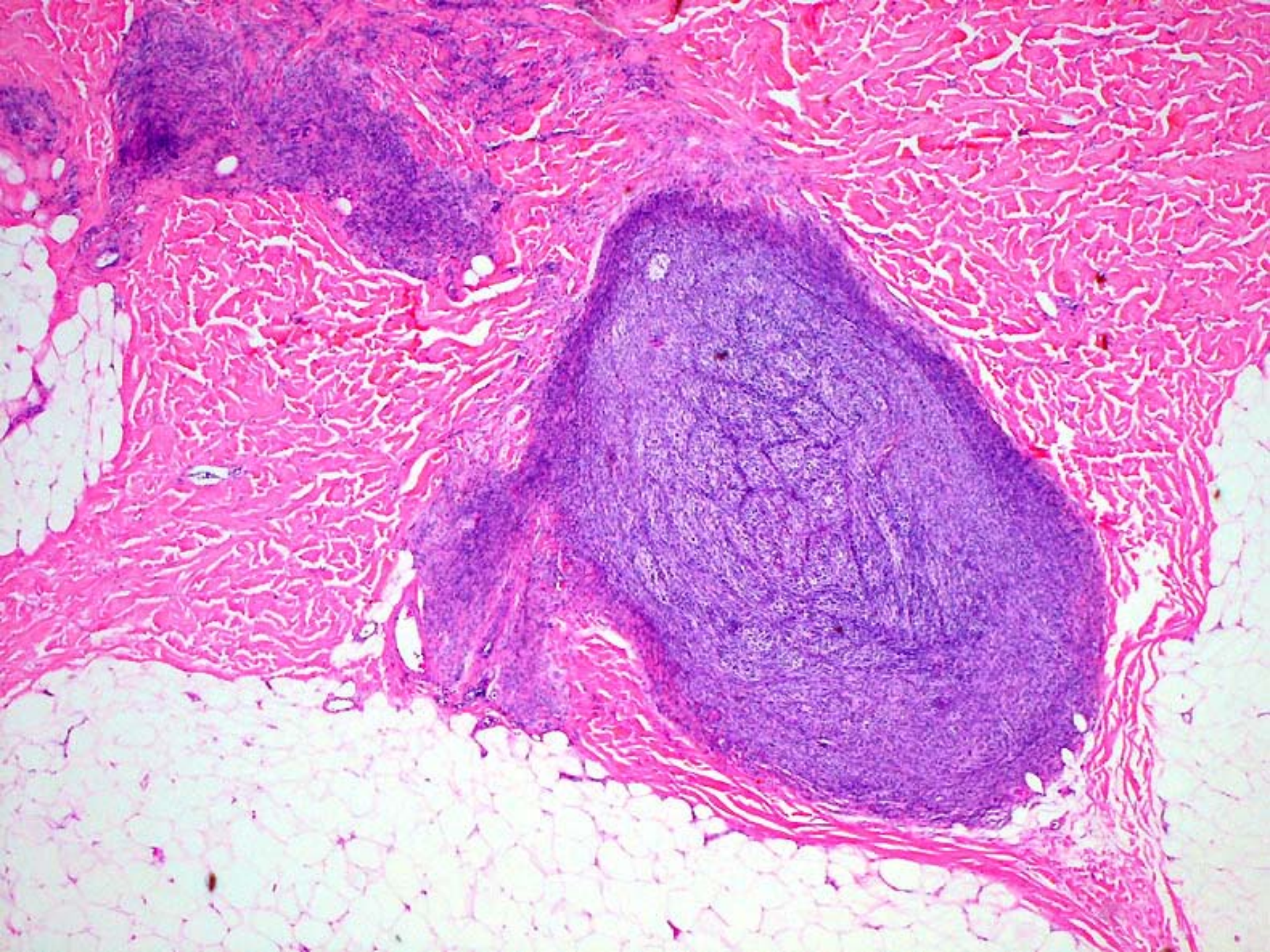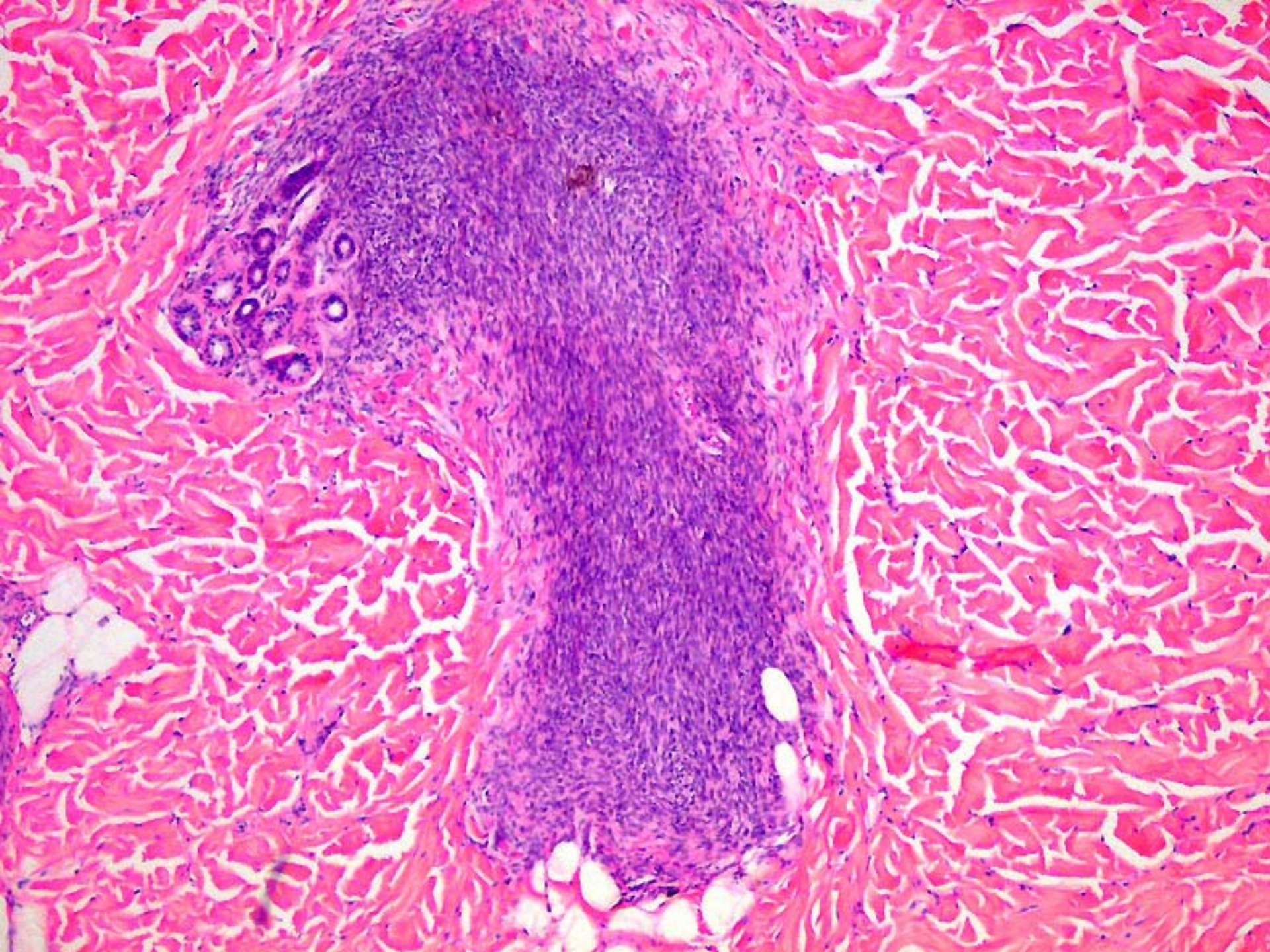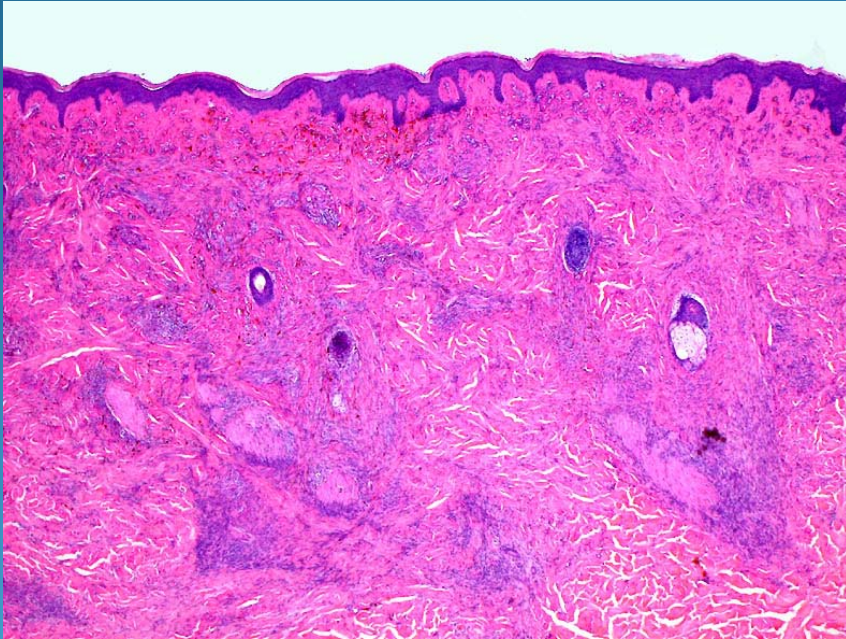


Congenital Melanocytic Nevus

Pearls



- Large asymmetric proliferation of bland melanocytes
- Look for extensive infiltration into pilosebaceous units and eccrine ducts
- May infiltrate pilar arrector muscles