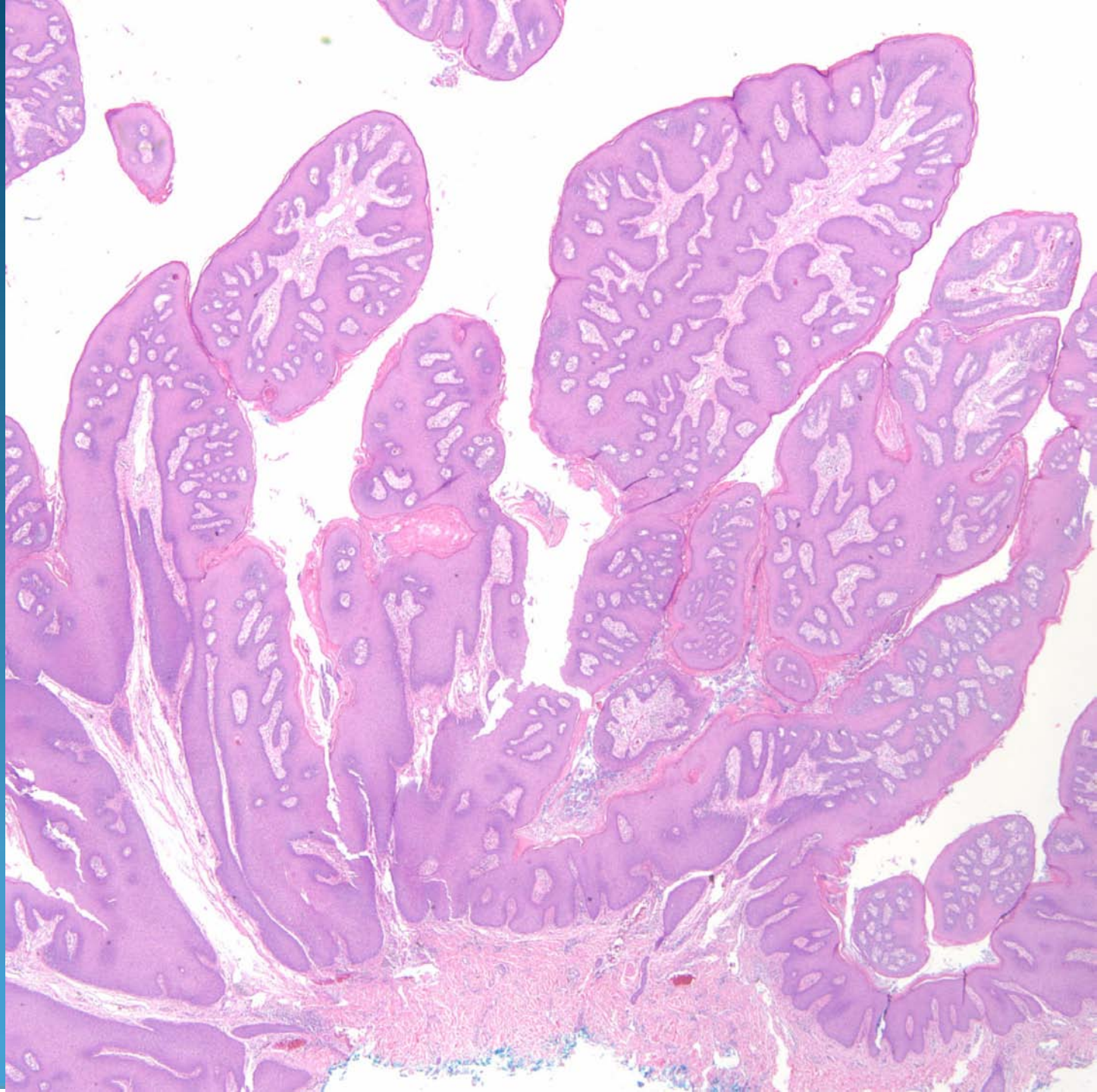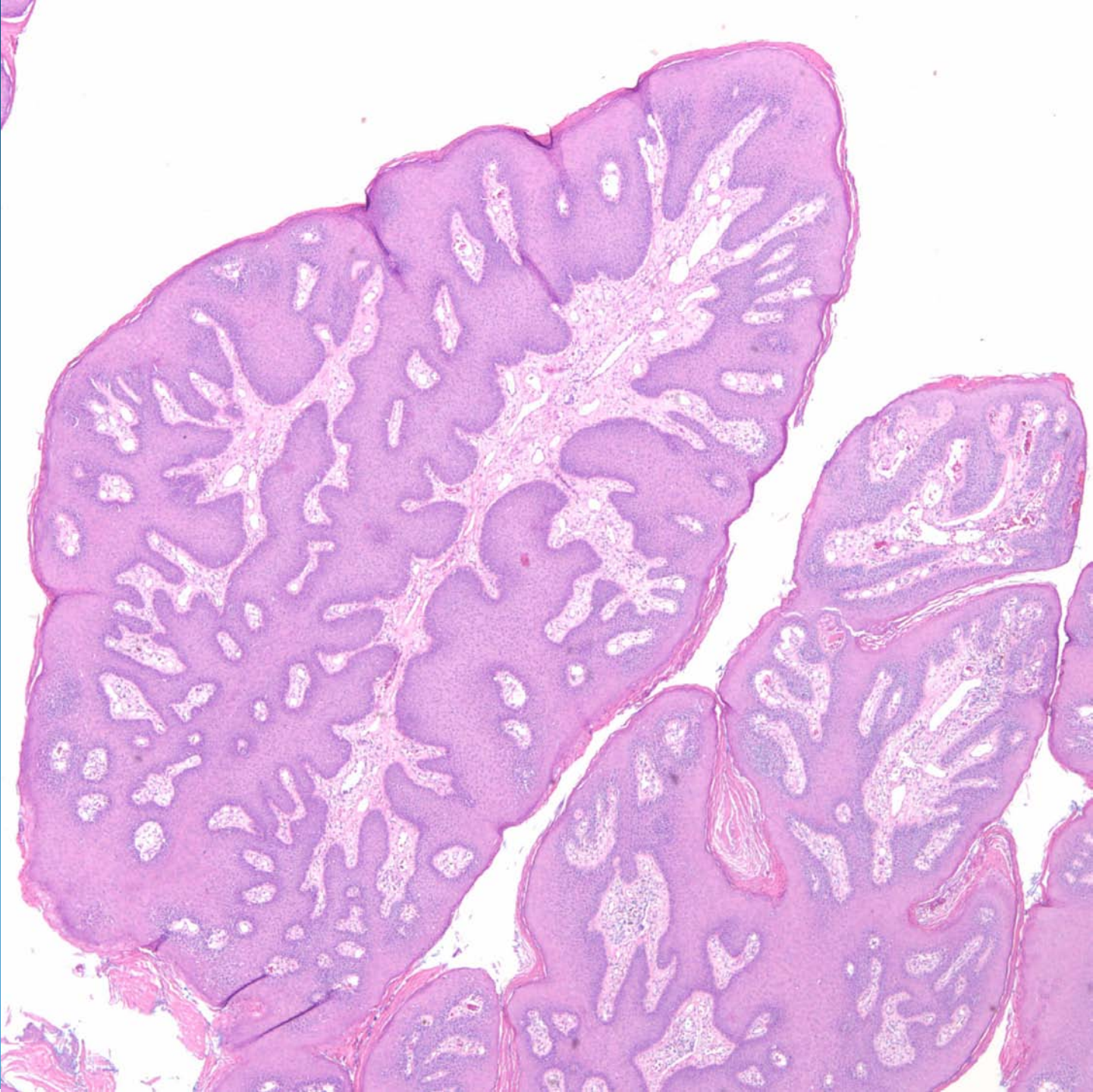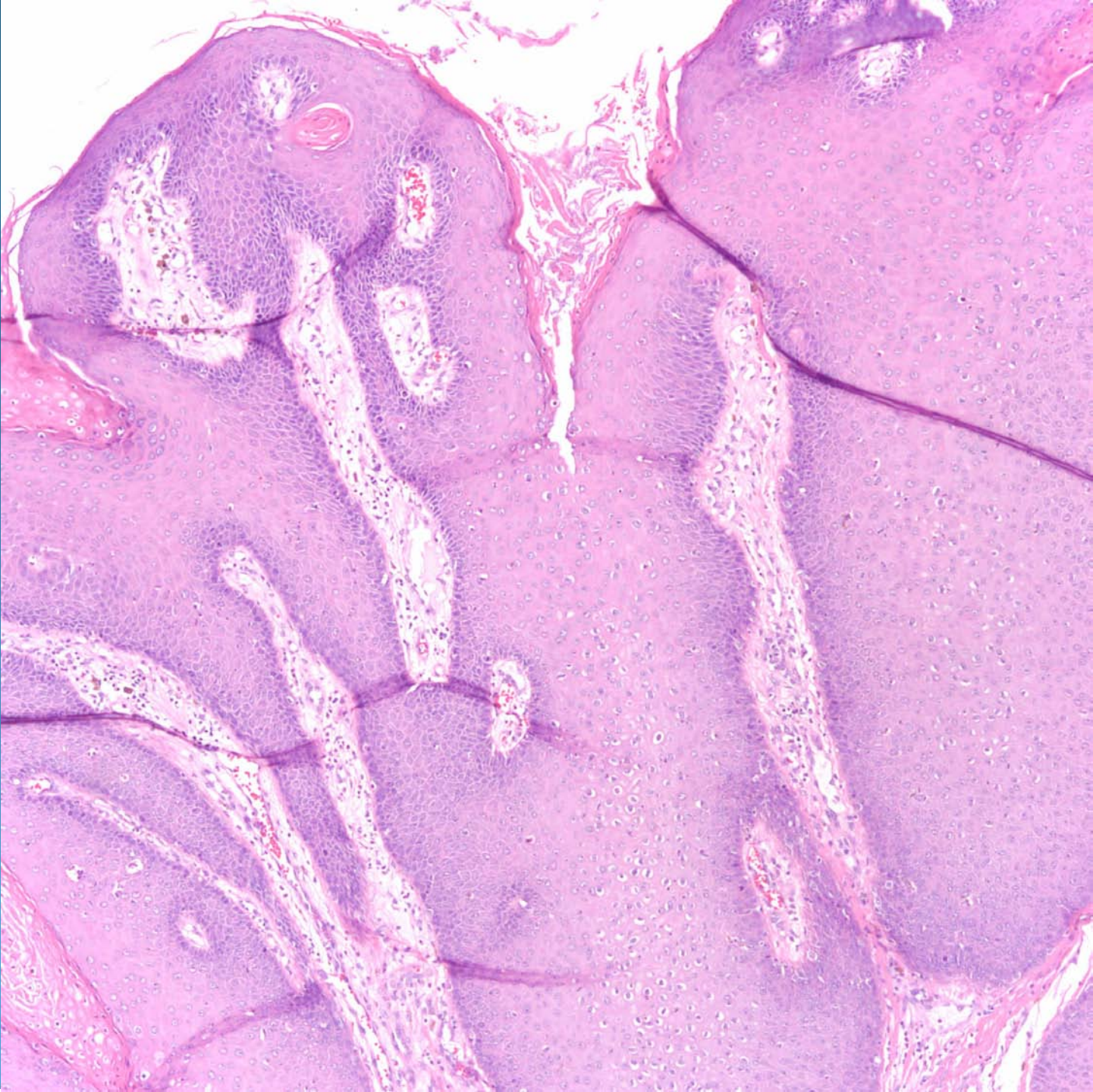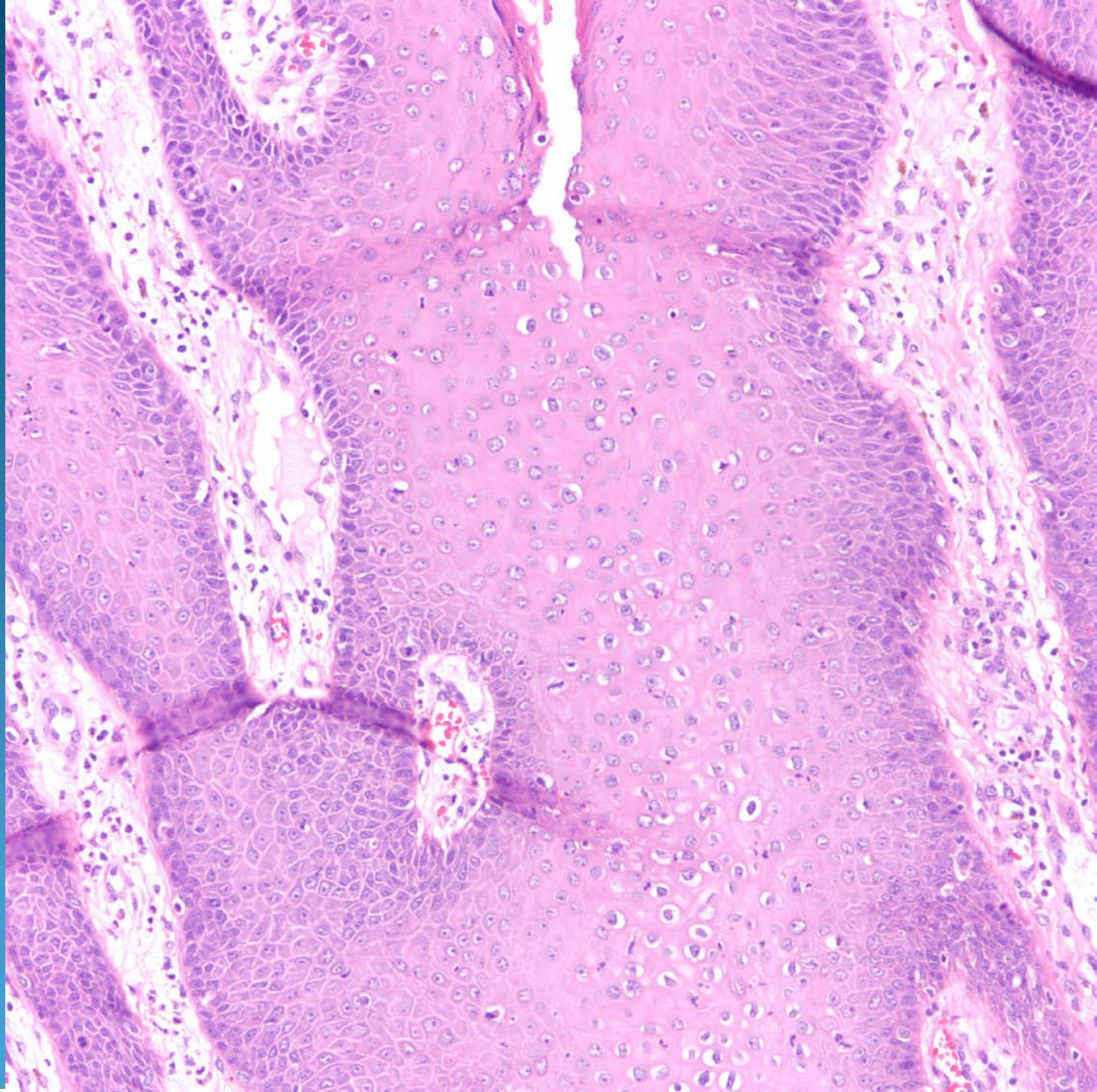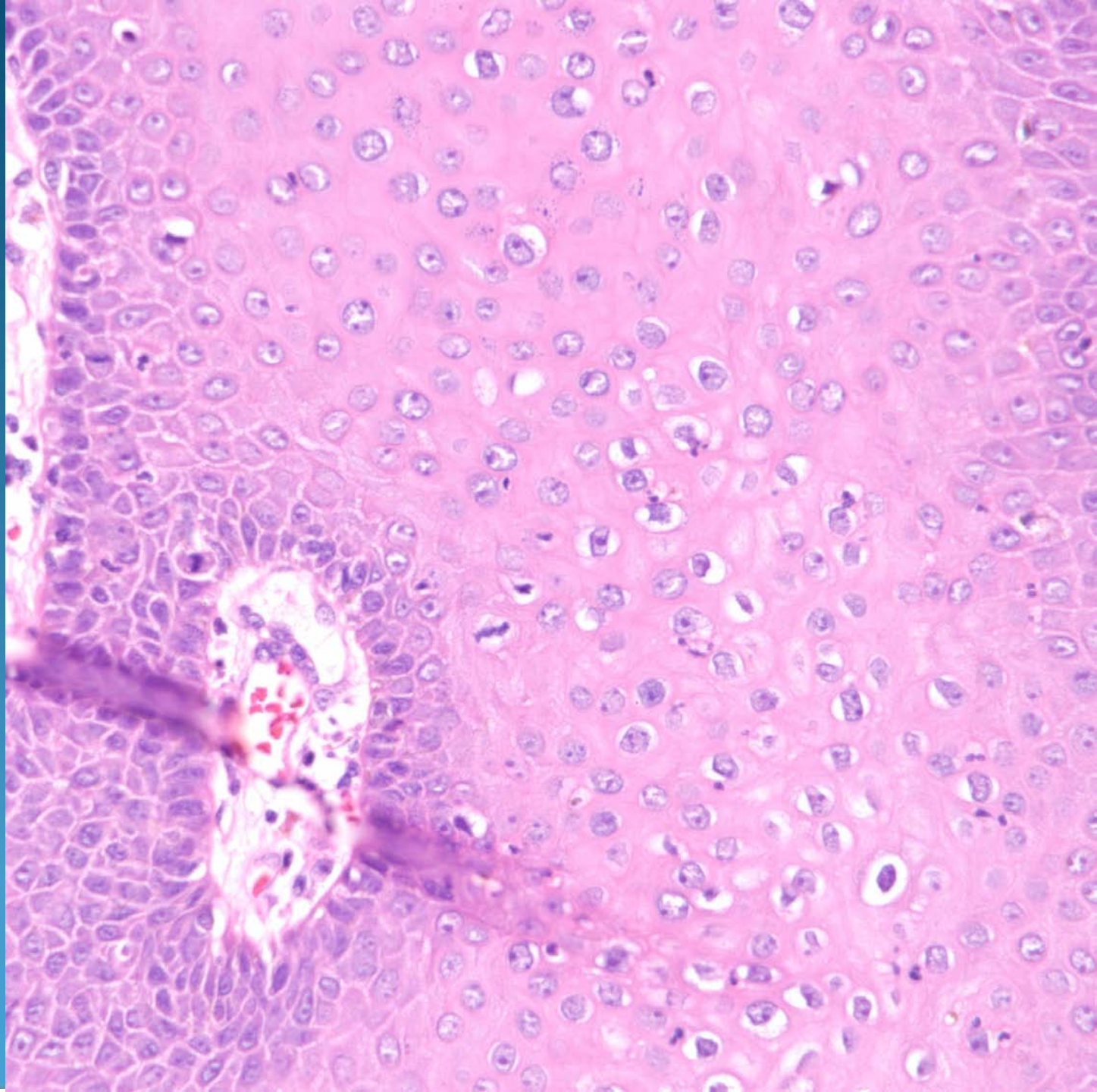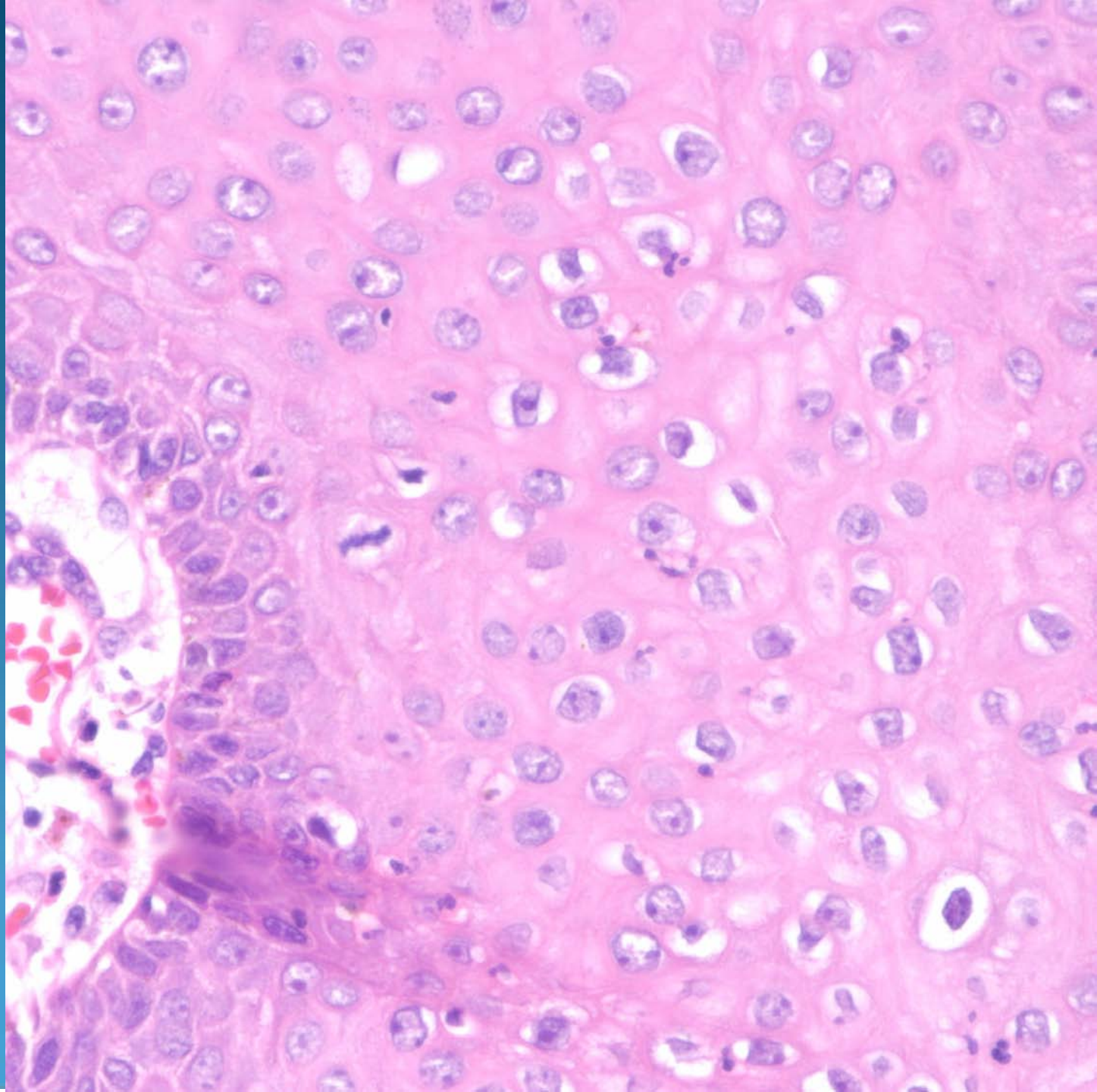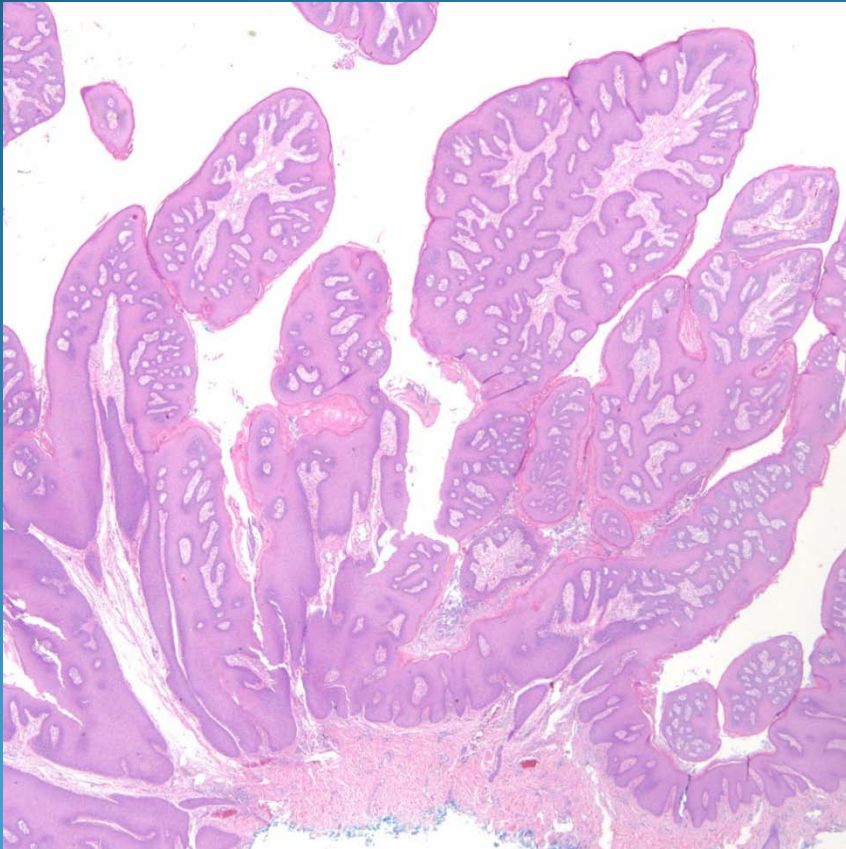


Condyloma accuminatum

Pearls



- Papillary fronds of squamous epithelium with fibrovascular core
- Superficial koilocytes
- Always examine base to exclude squamous dysplasia or invasive carcinoma