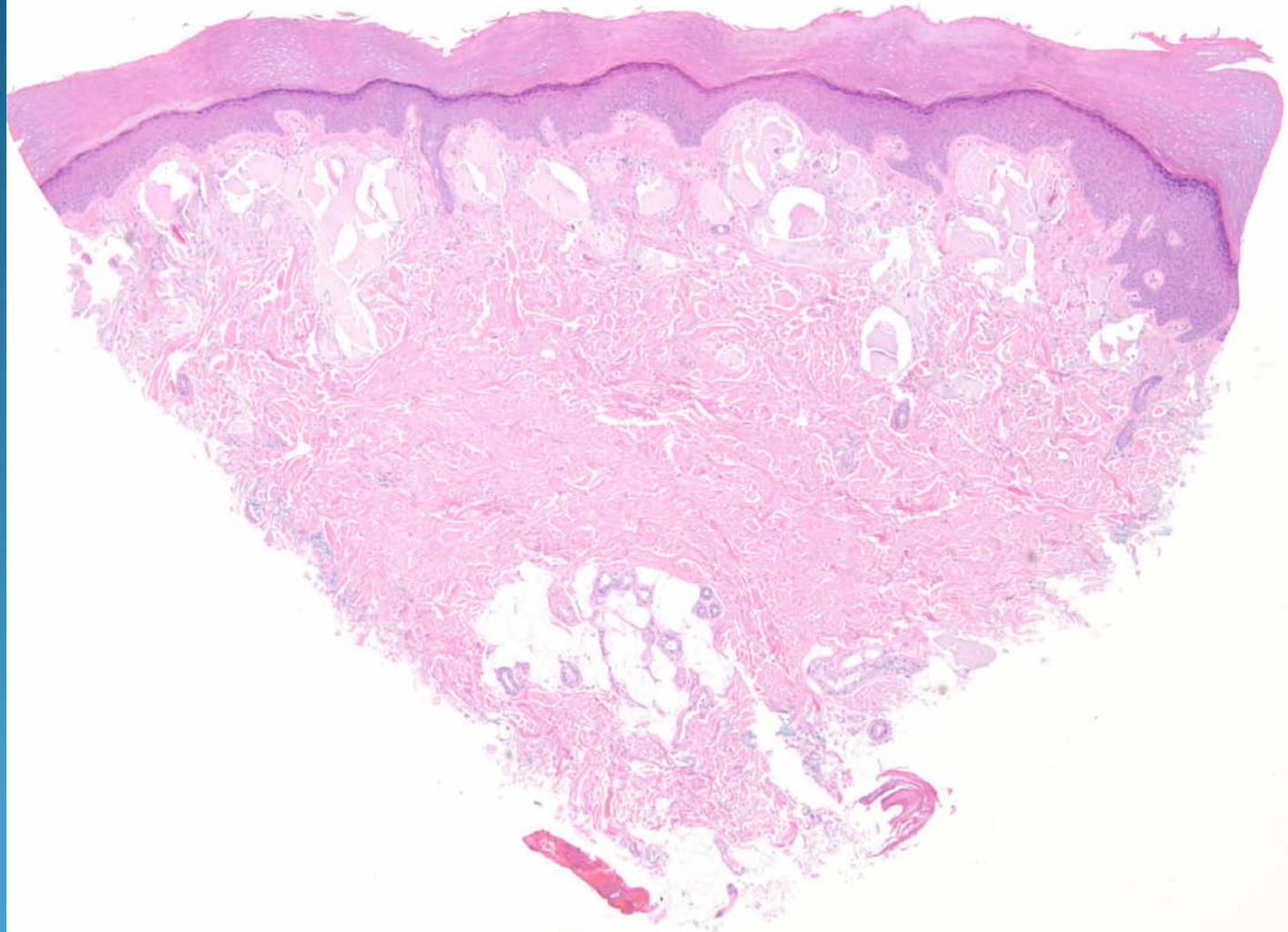
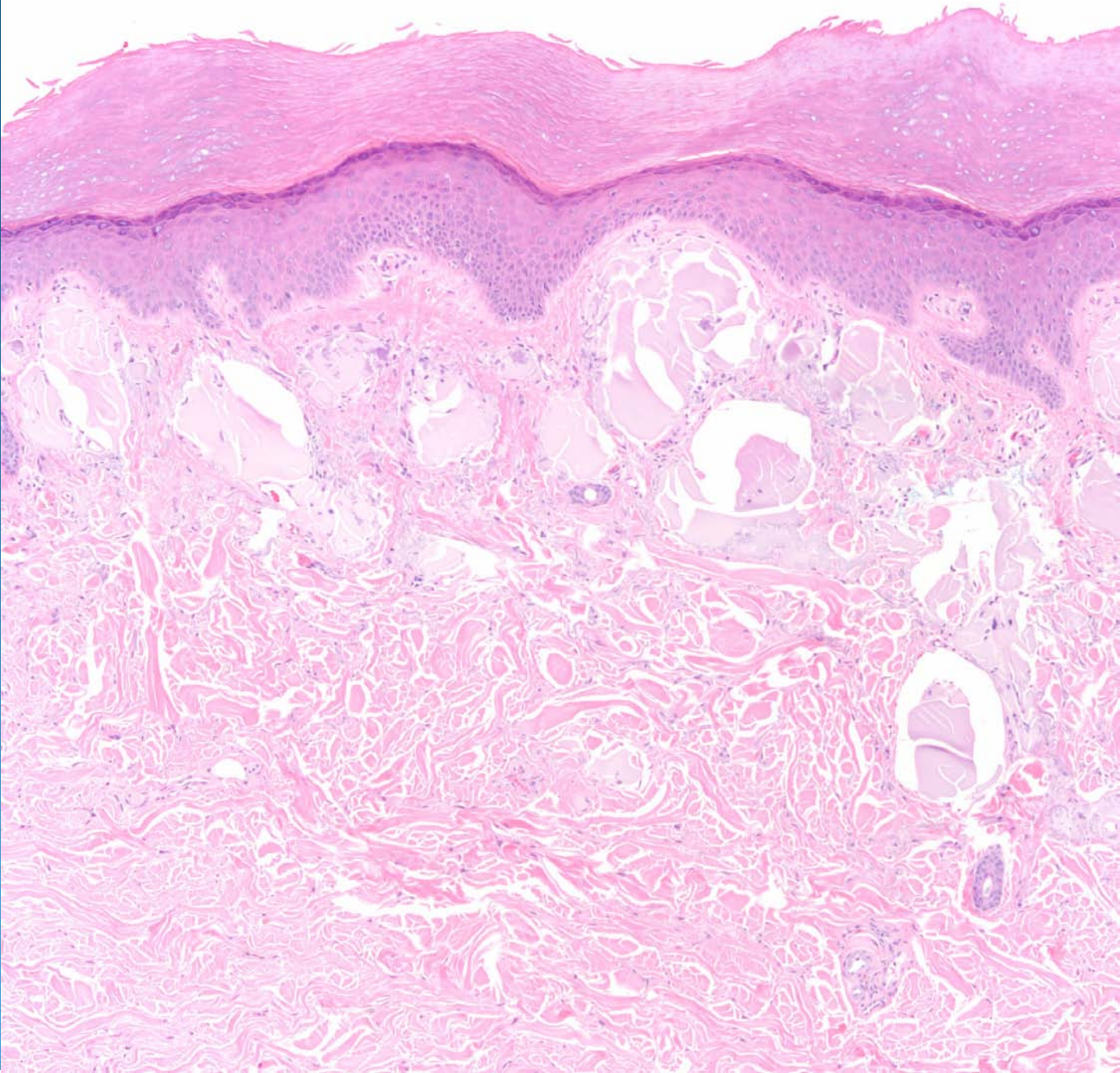
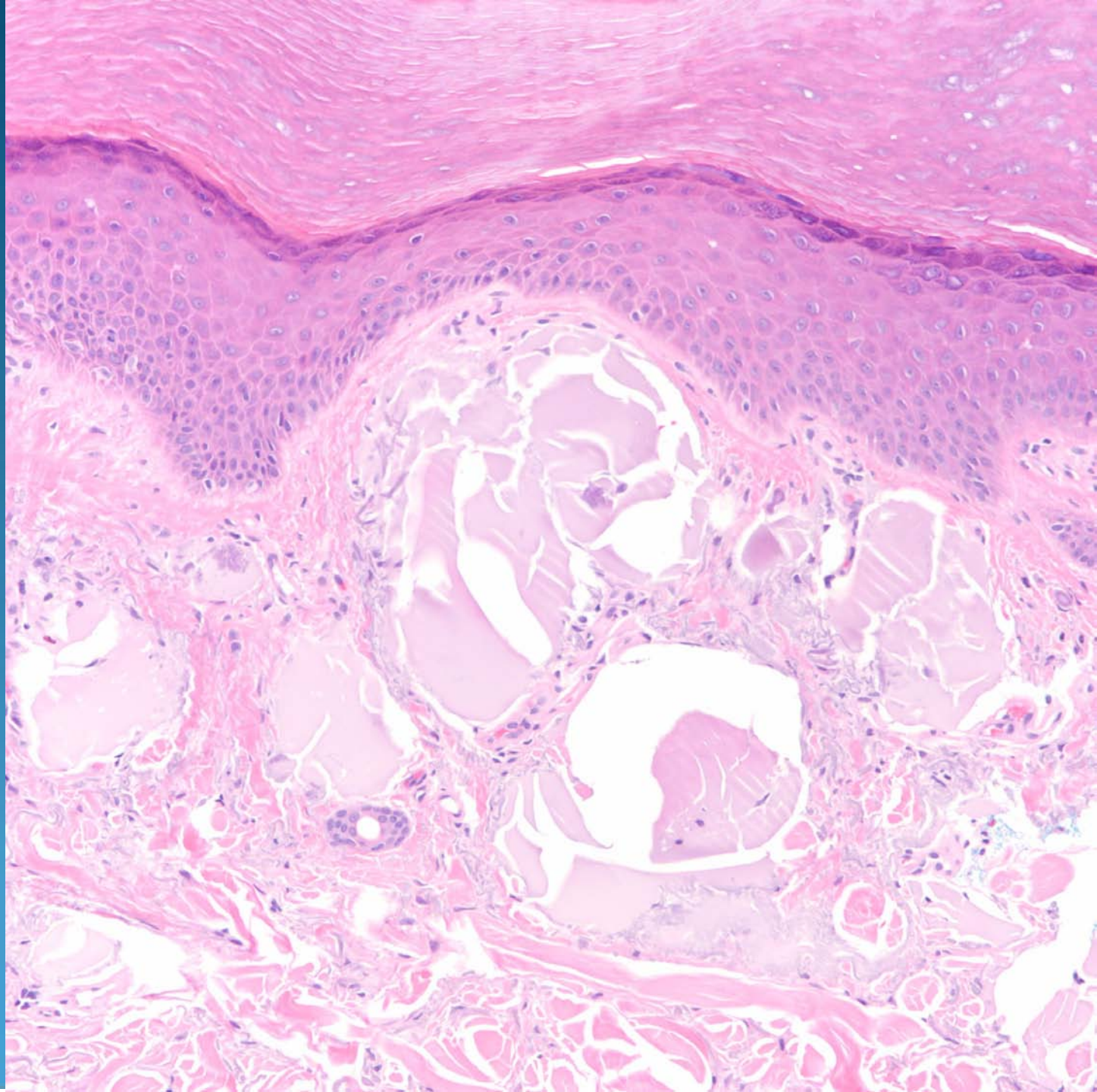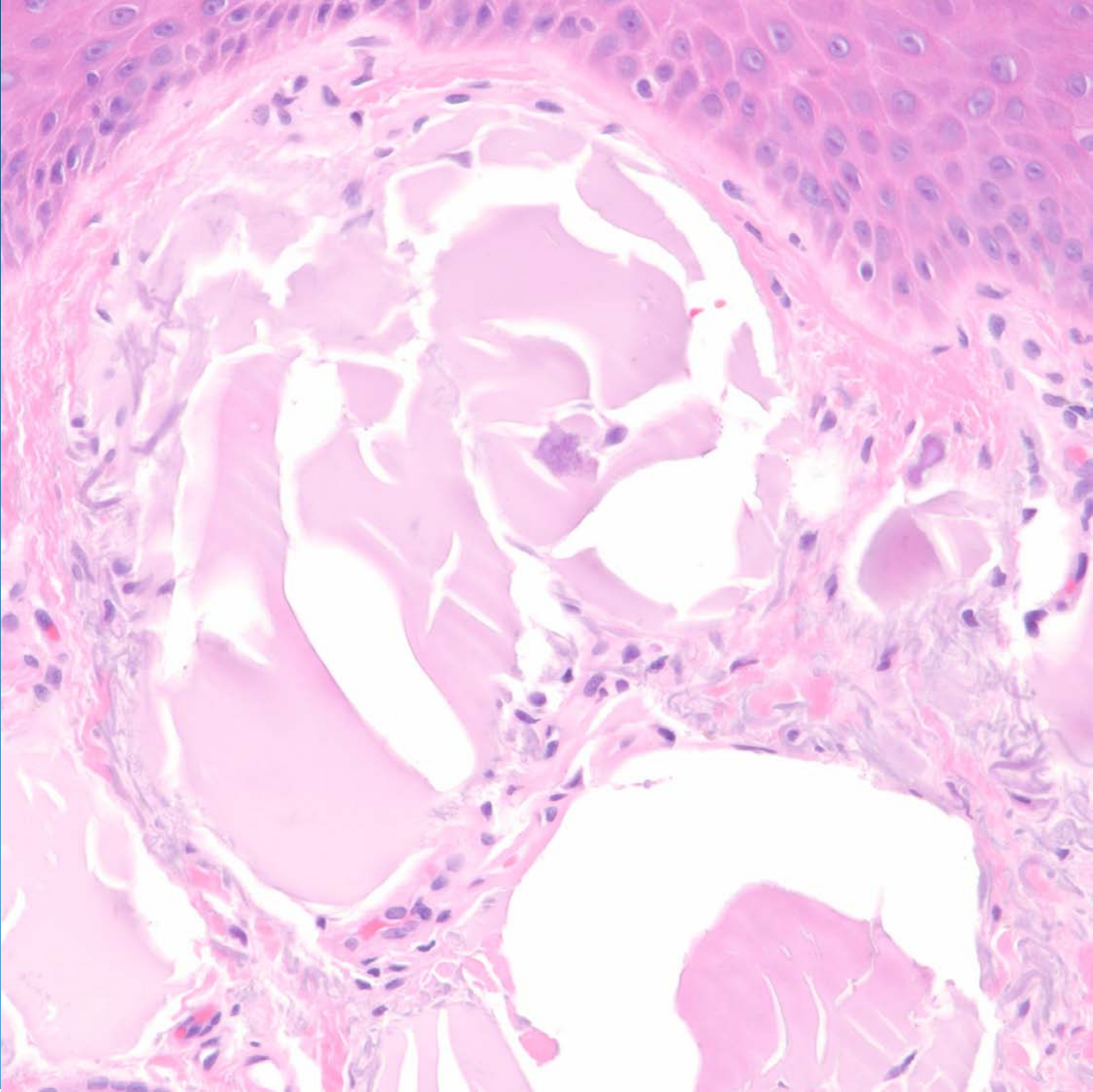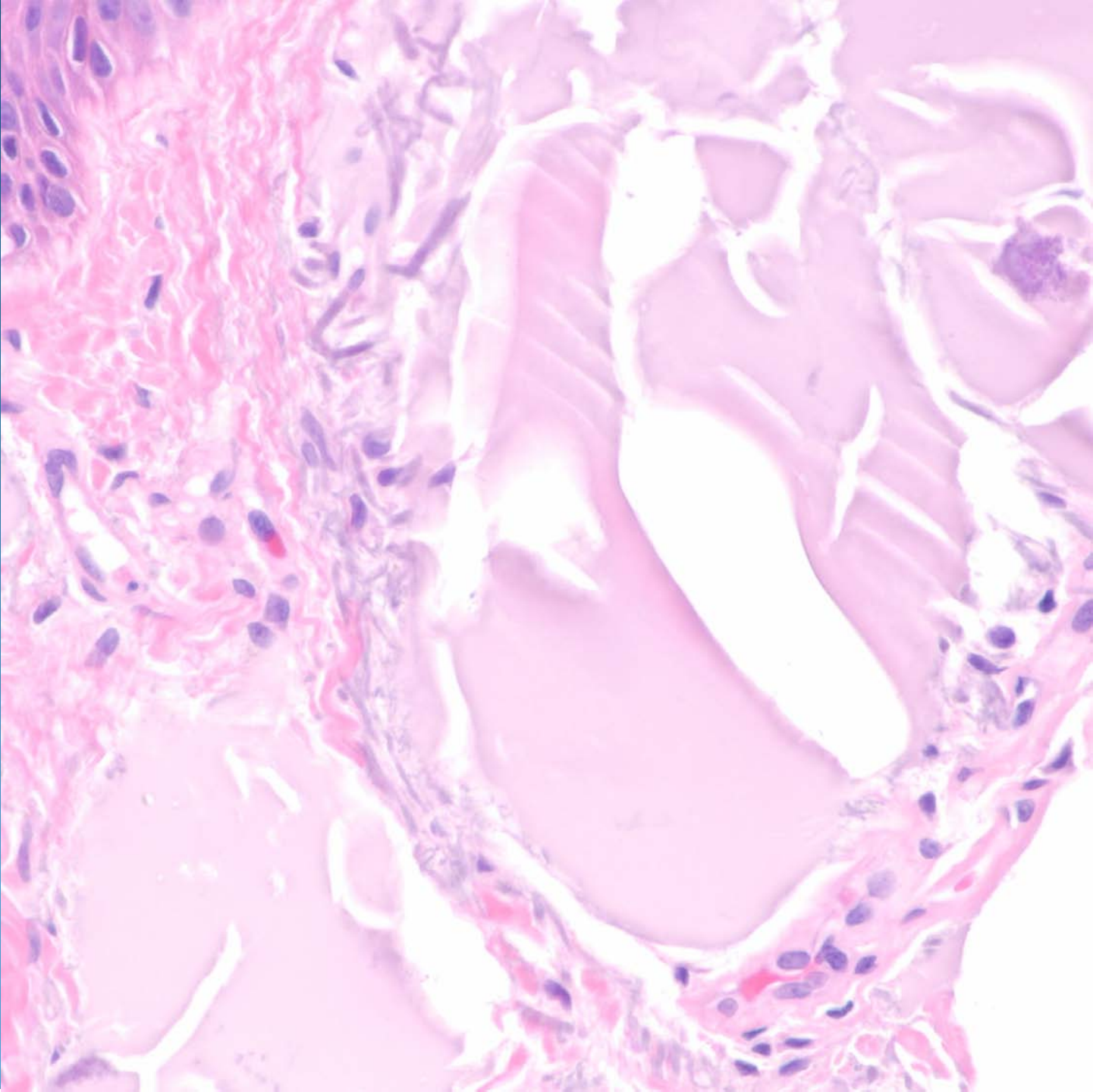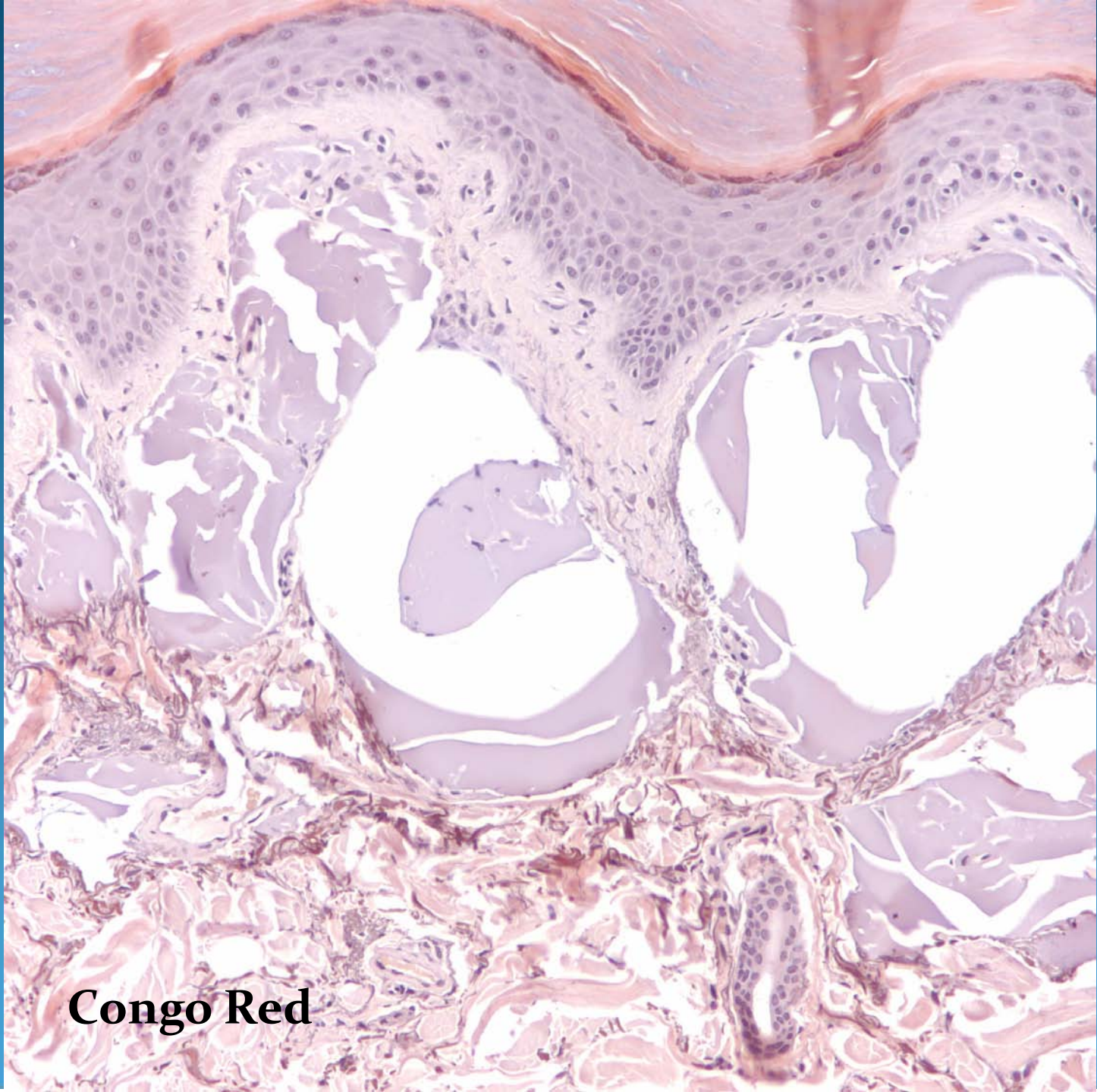# What is the best diagnosis?

- A. Macular amyloidosis
- B. Lipoid proteinosis
- C. Keloid
- D. Colloid milium
- E. Gouty tophus

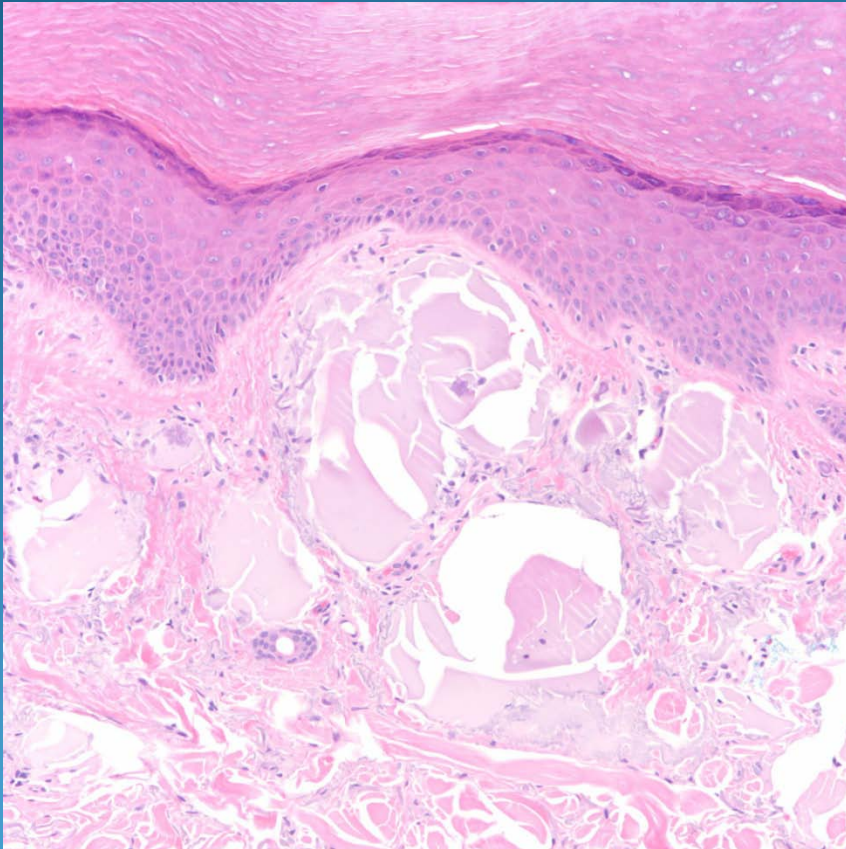
Colloid milium



**Congo Red**



# Pearls



- Nodular collections of hyalinized material, may show cracking
- Localized to papillary dermis
- Congo red negative, May be PAS positive
- Elastic stain may show decreased elastic fibers