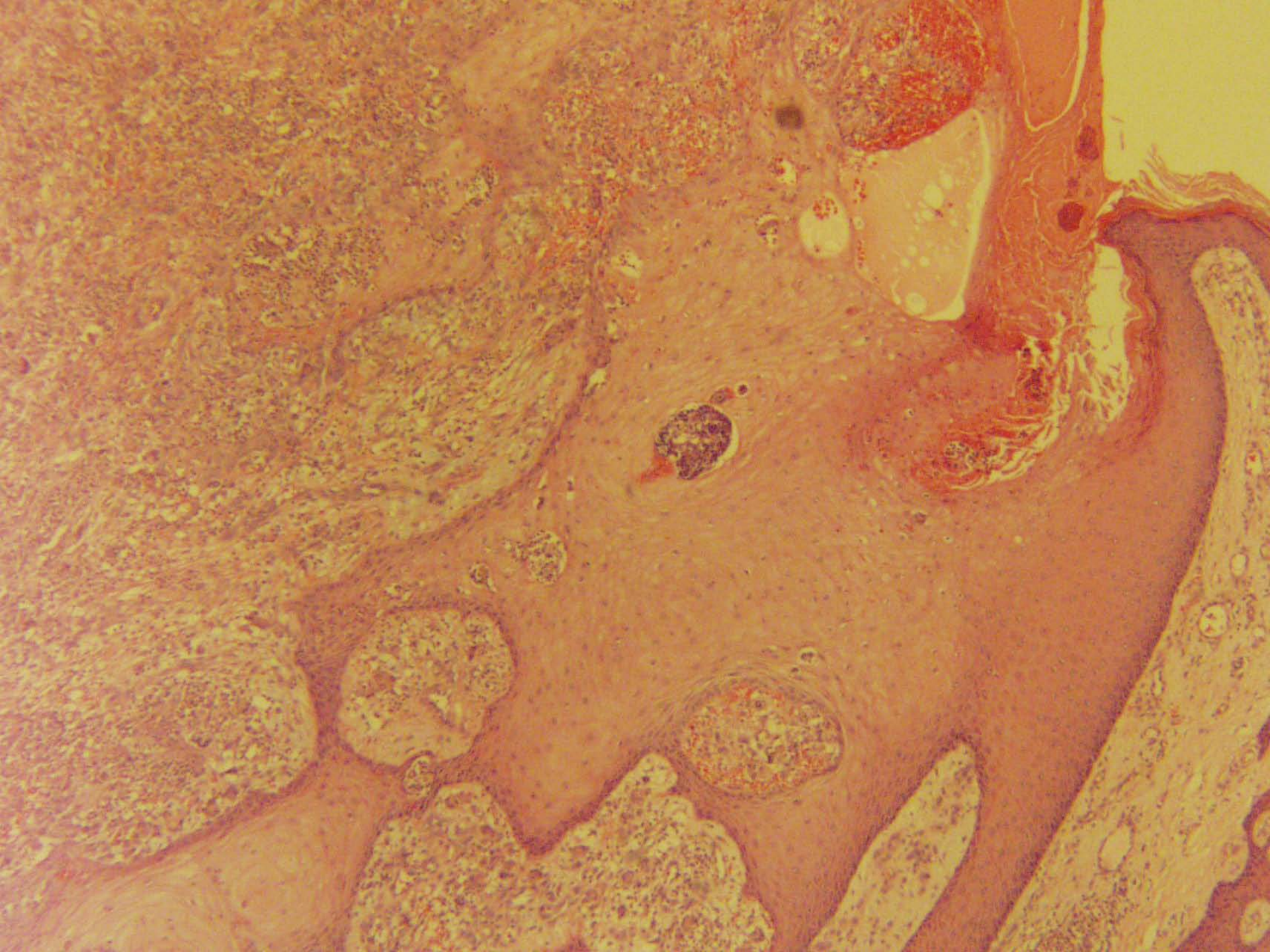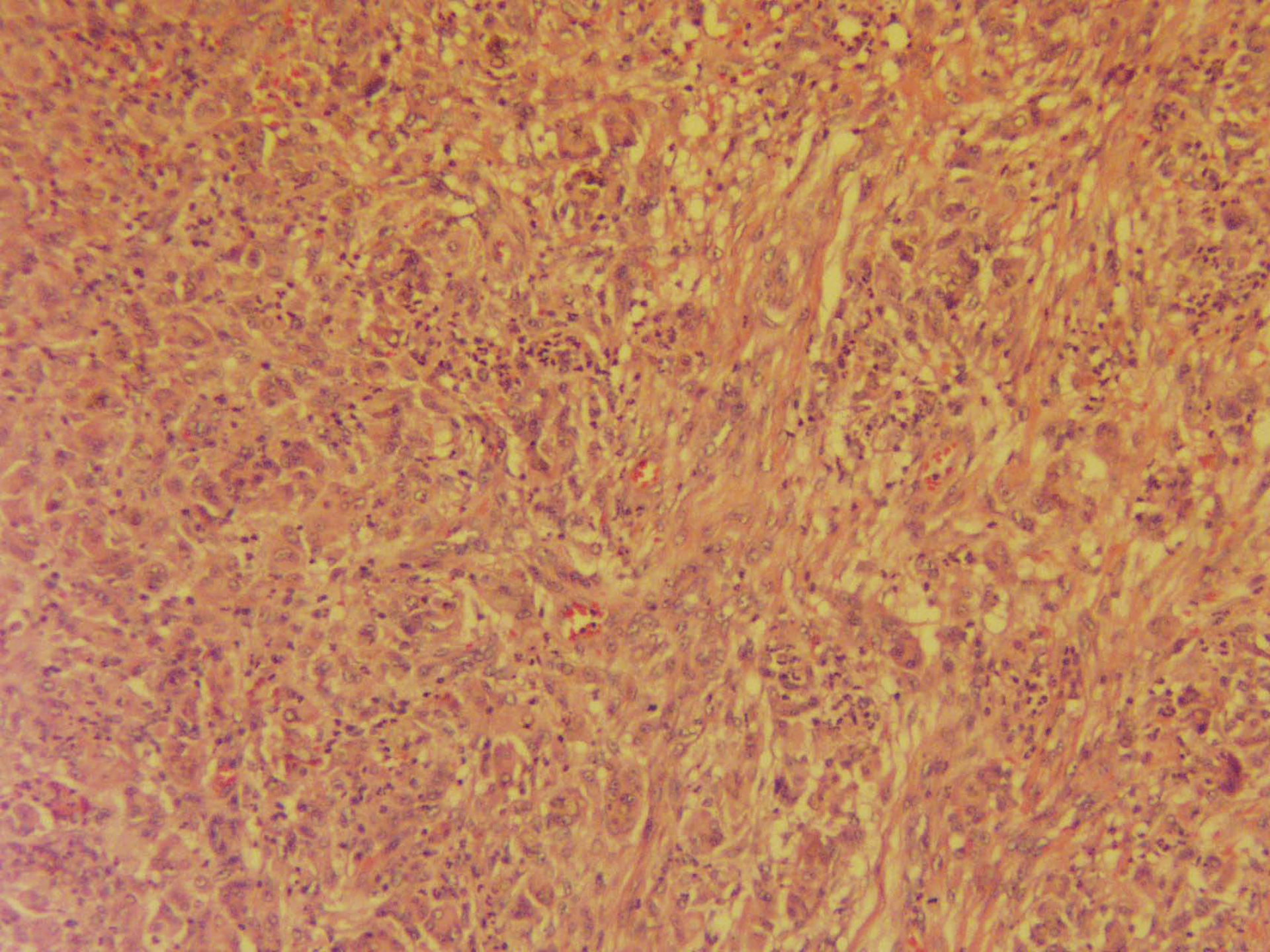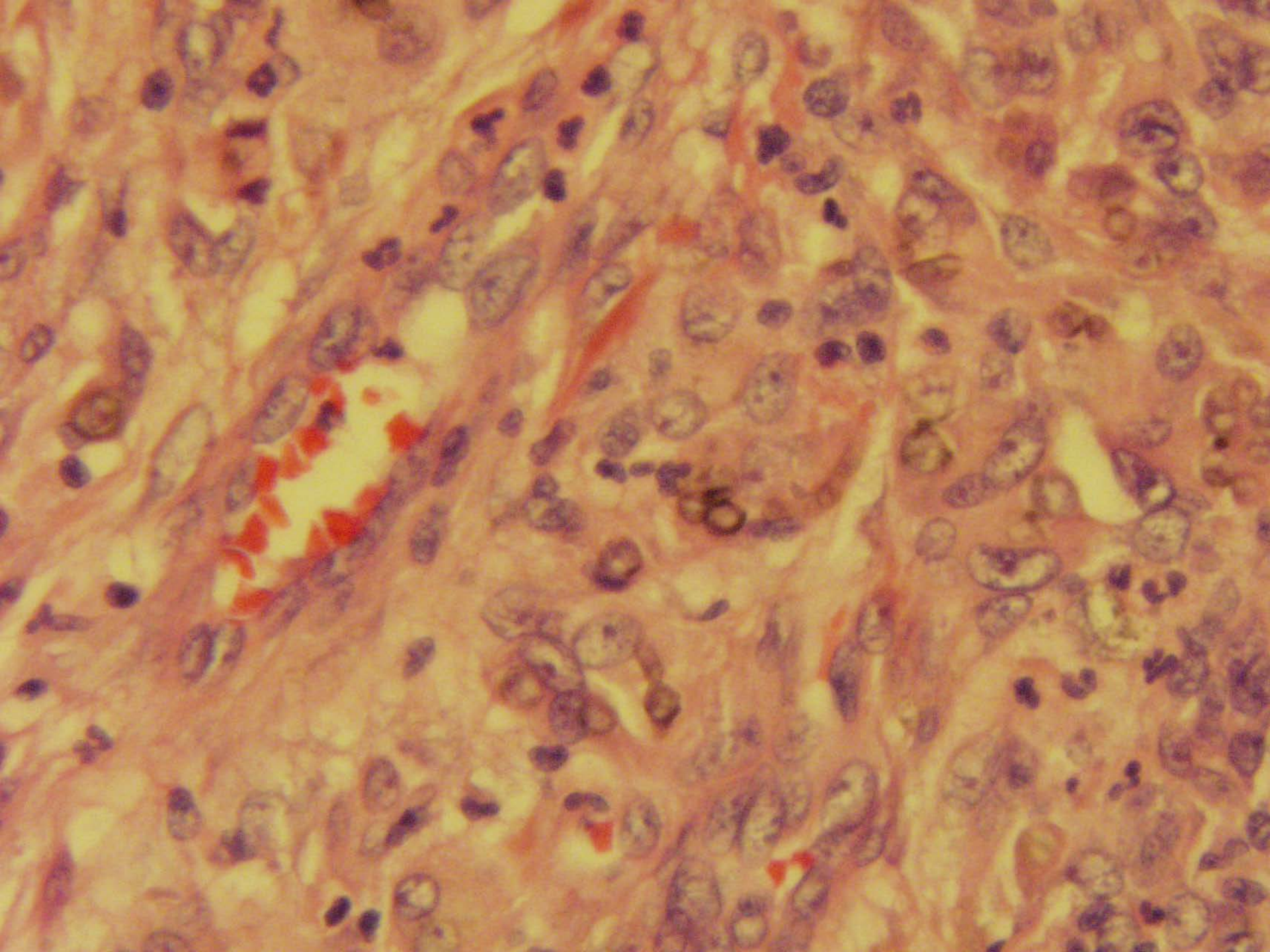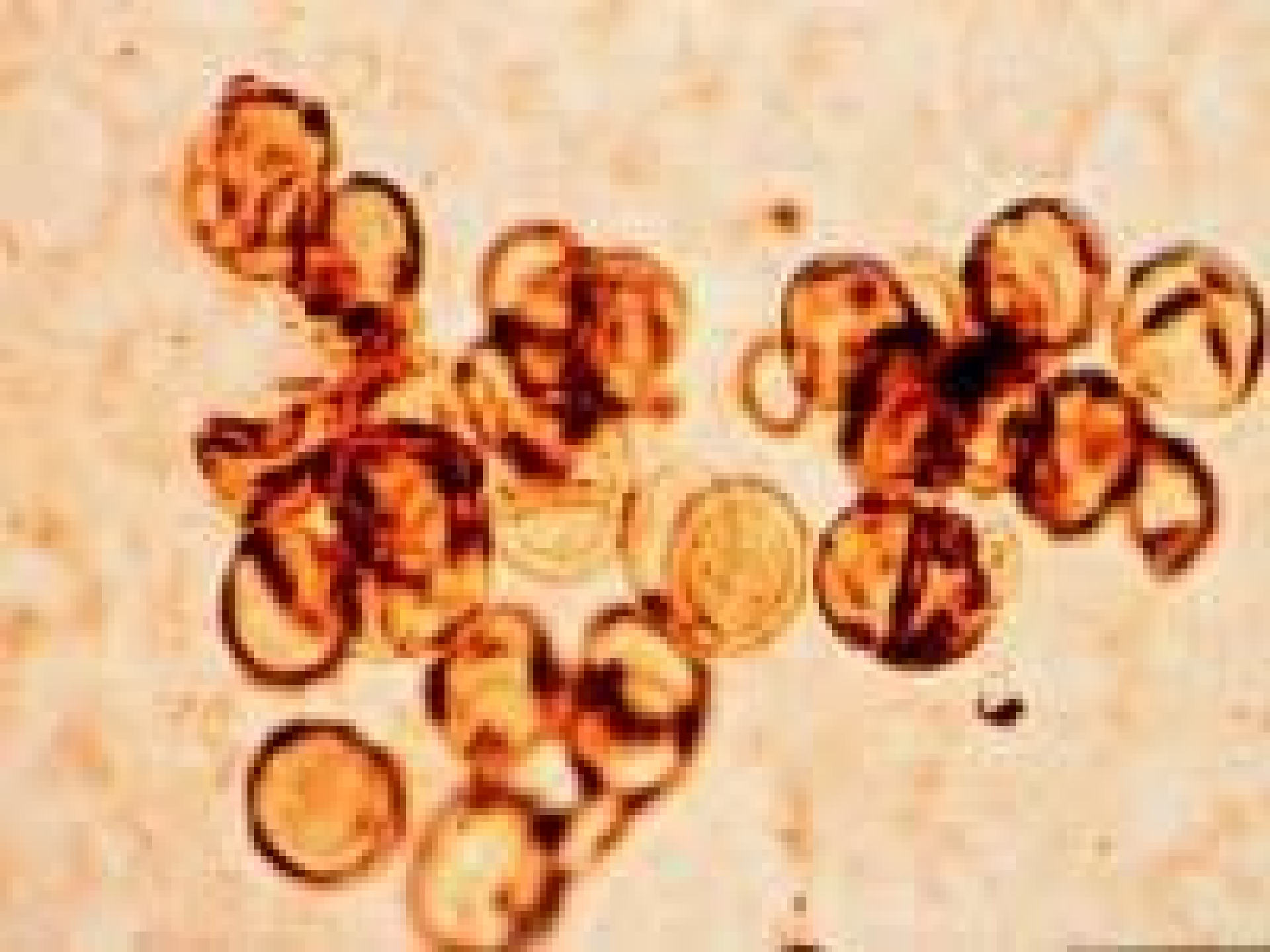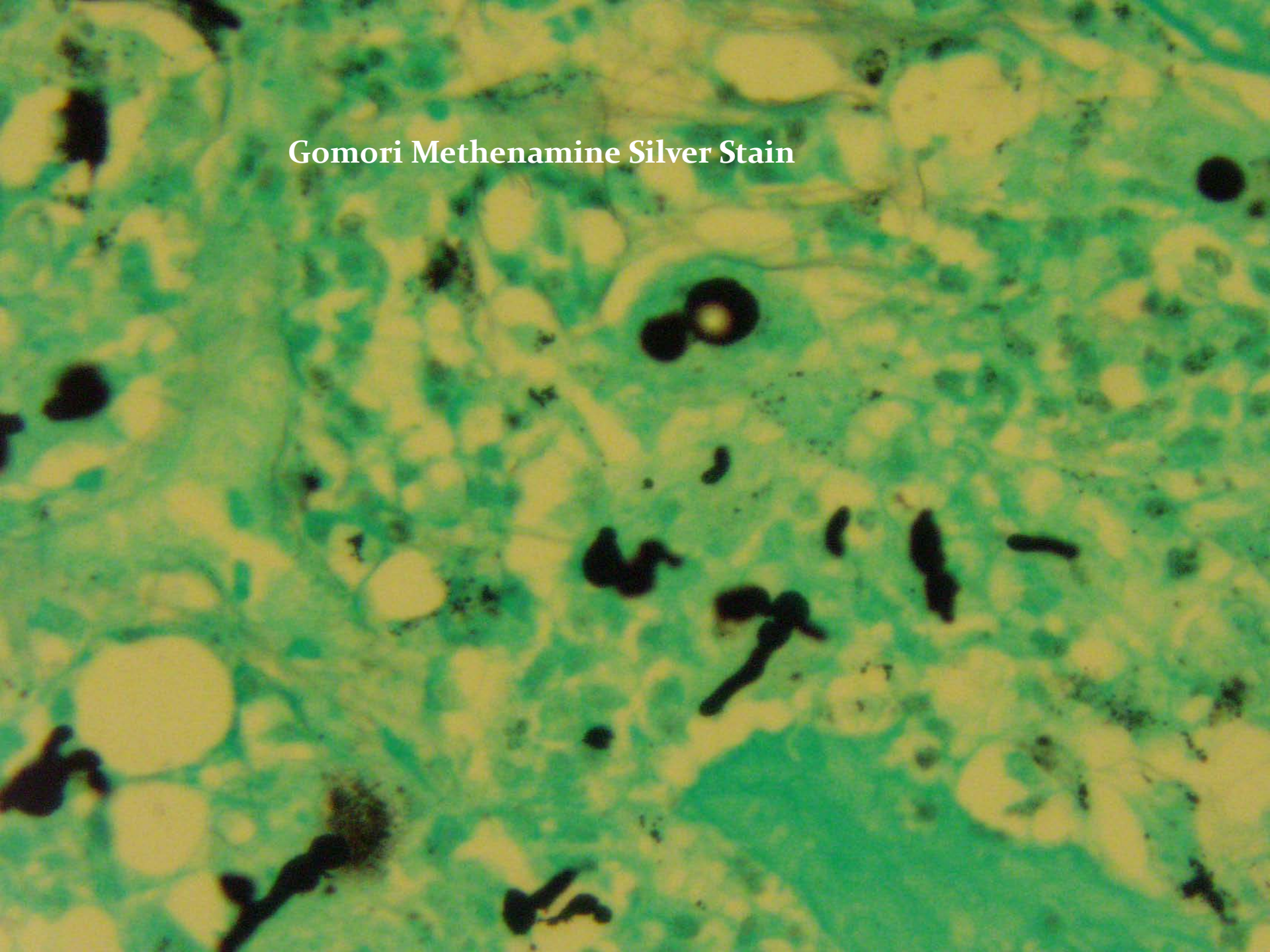


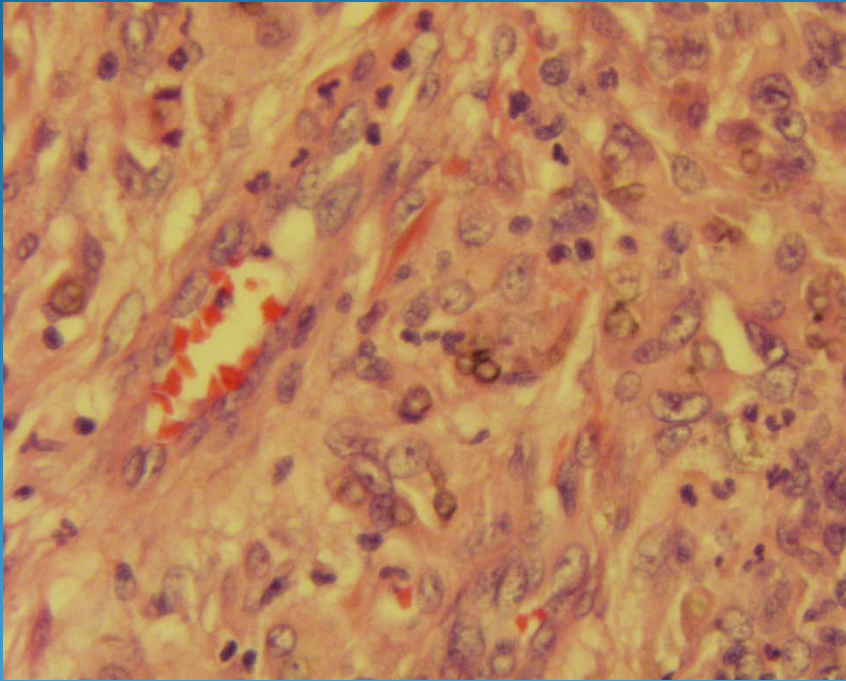


Chromomycosis

Gomori Methenamine Silver Stain



Pearls



- Pseudoepitheliomatous hyperplasia
- Intraepithelial abscesses
- Granulation tissue
- Look for “copper pennies”
AKA Medlar bodies
- Frequently seen with splinter or foreign body