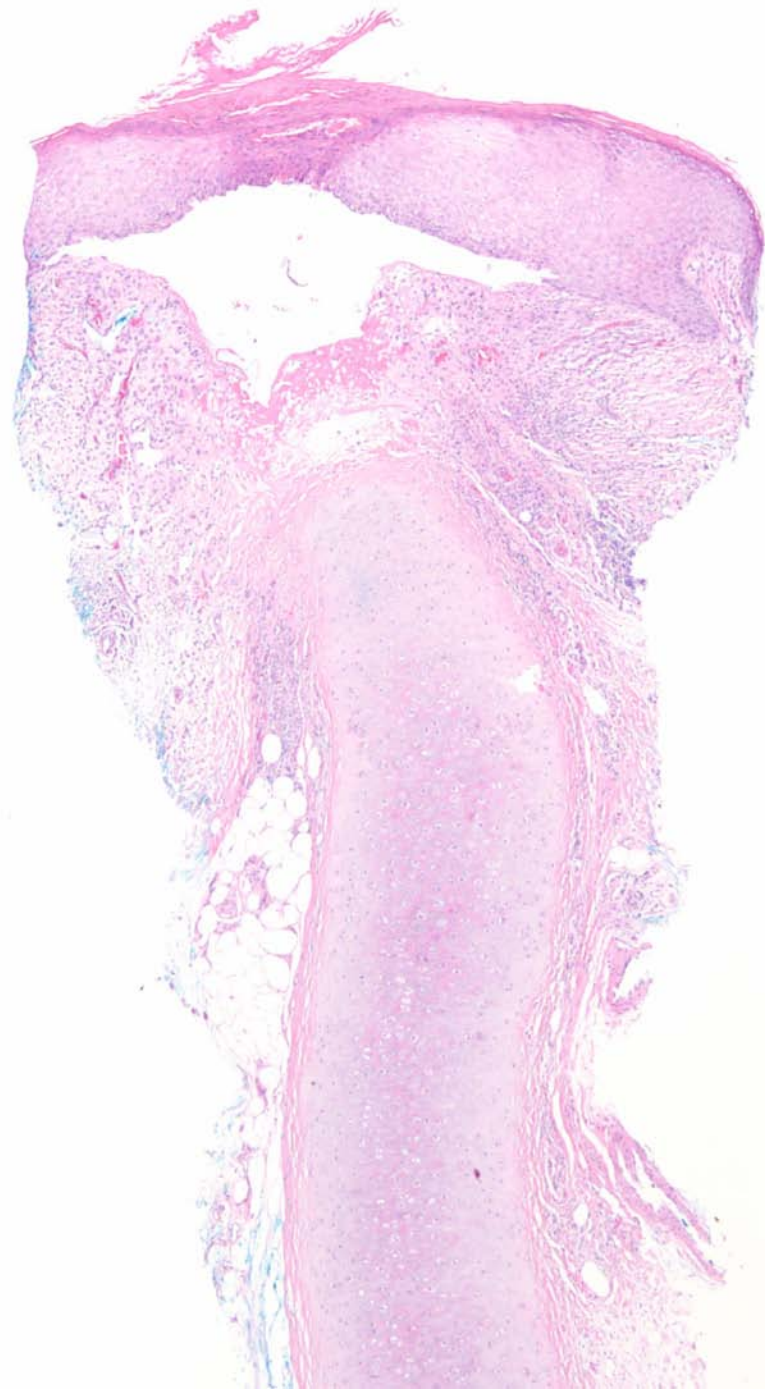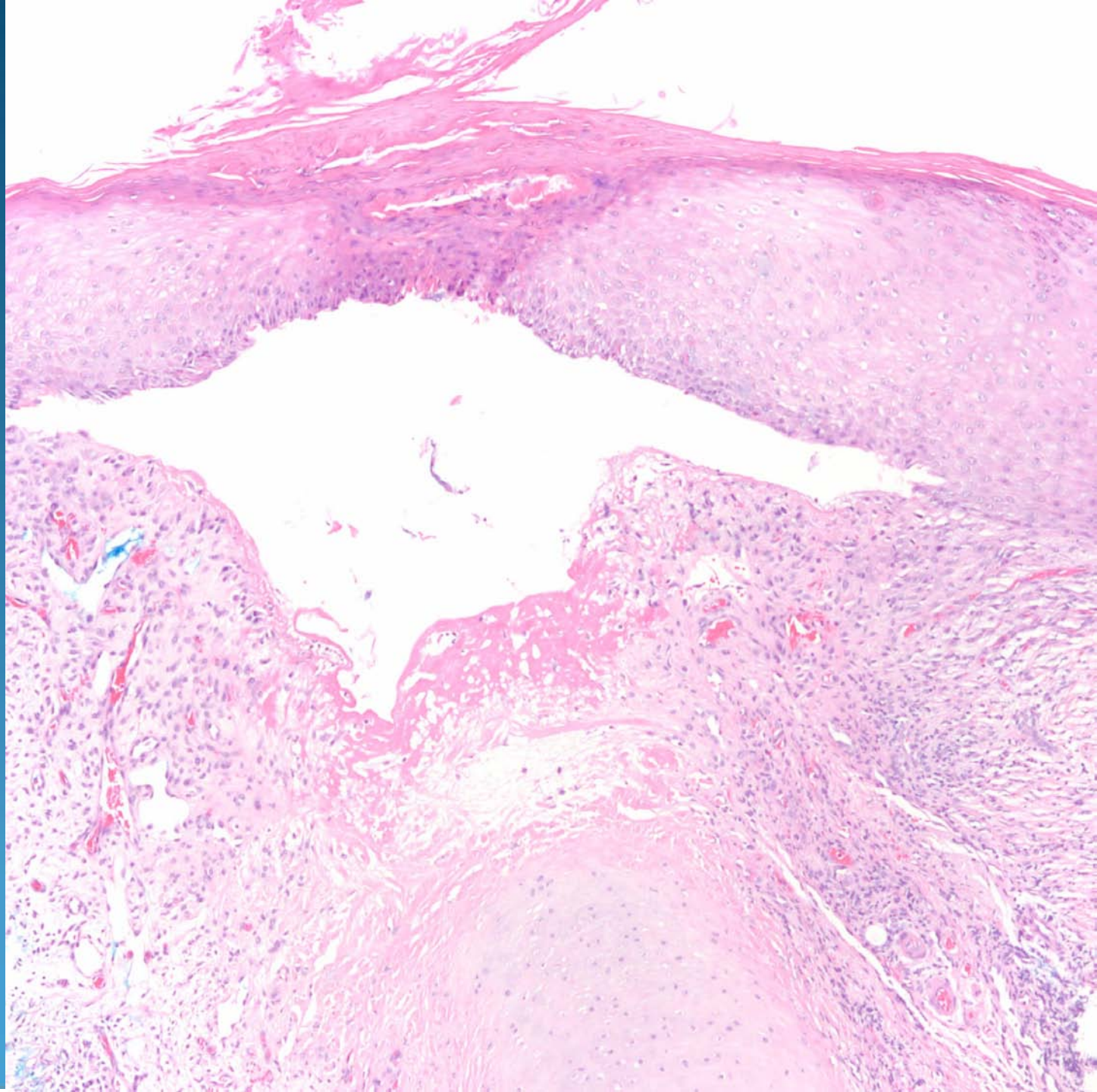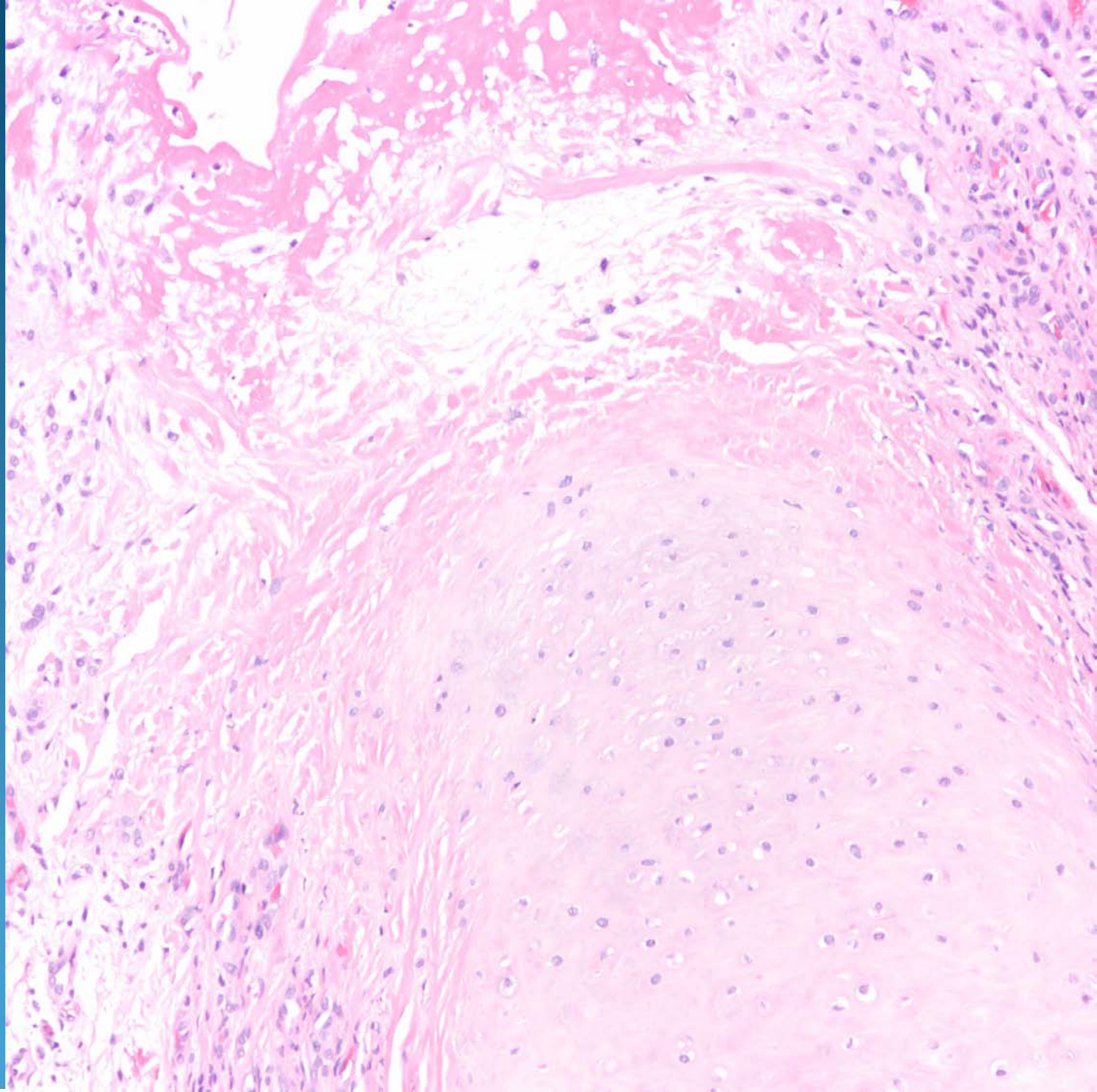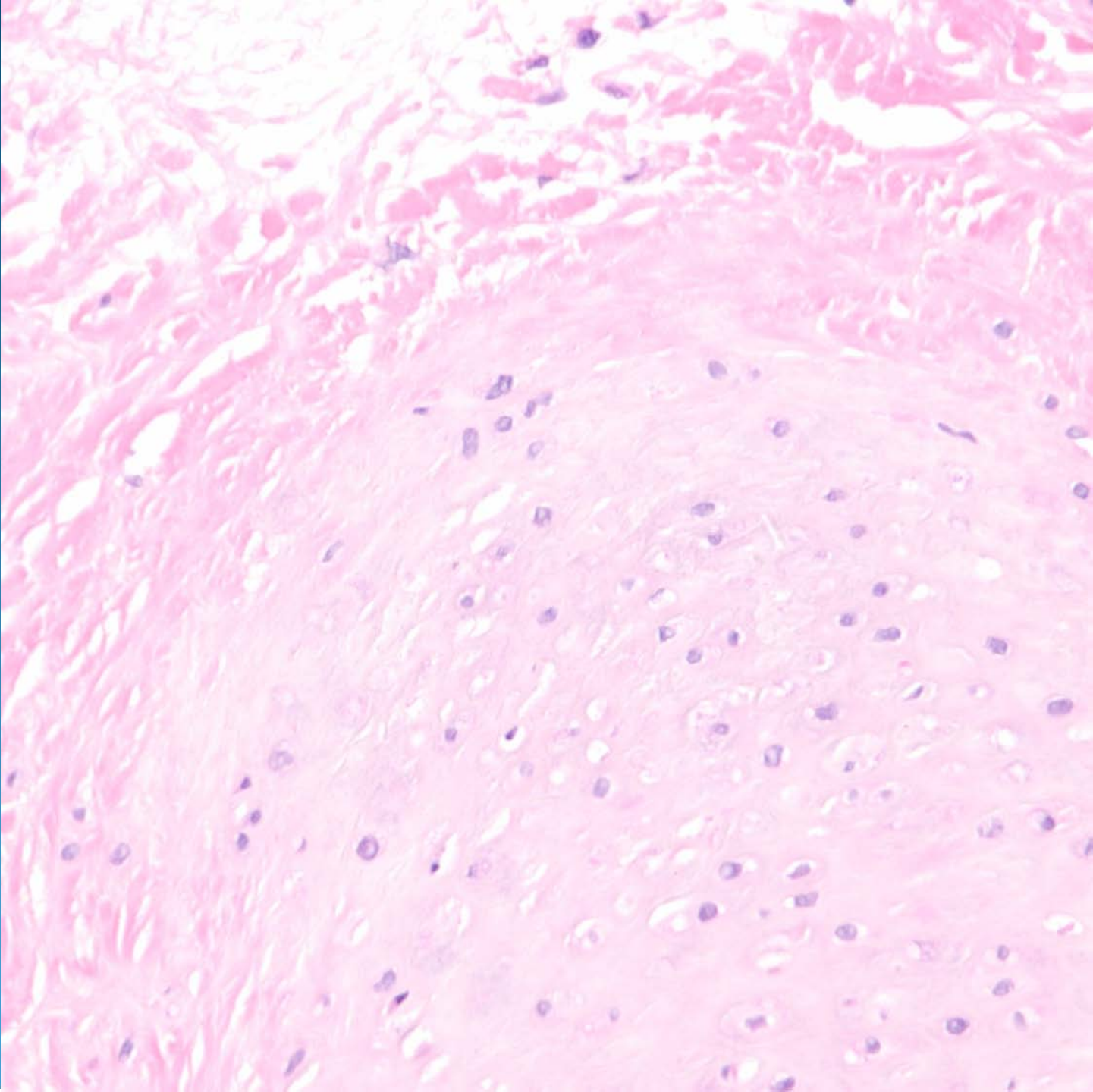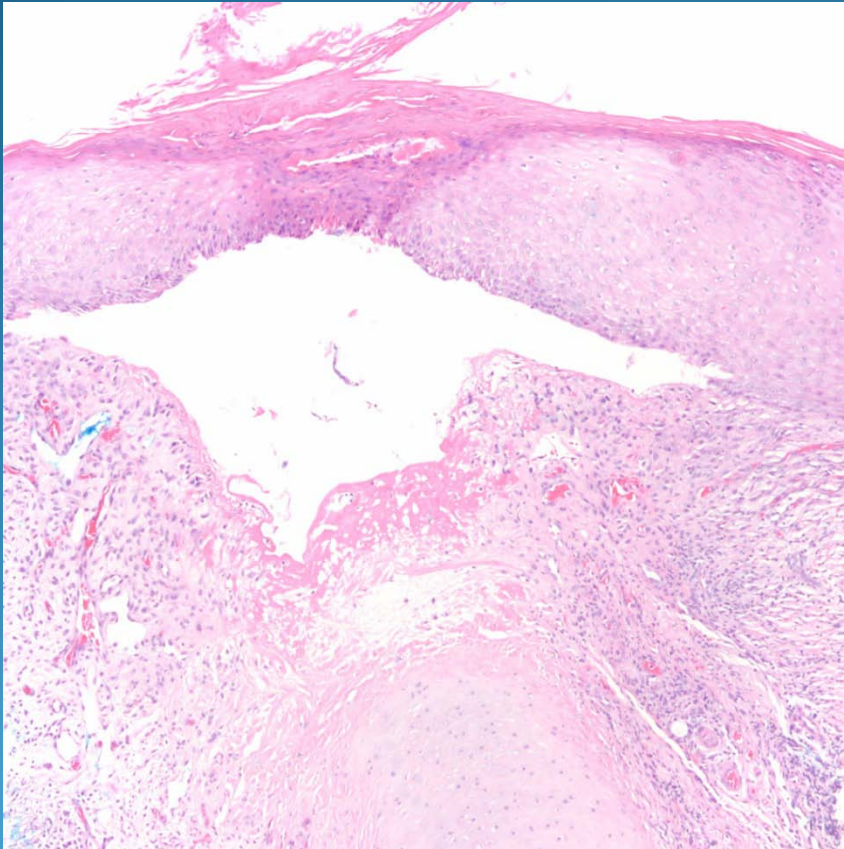


Chondrodermatitis Nodularis Helicis

Pearls



- Recognize ear location with vellus hairs and cartilage
- Variable epidermal changes +/- ulceration
- May have epidermal-dermal separation with fibrin
- May have proliferation of perichondrocytes
- Cartilage with eosinophilic degenerative changes