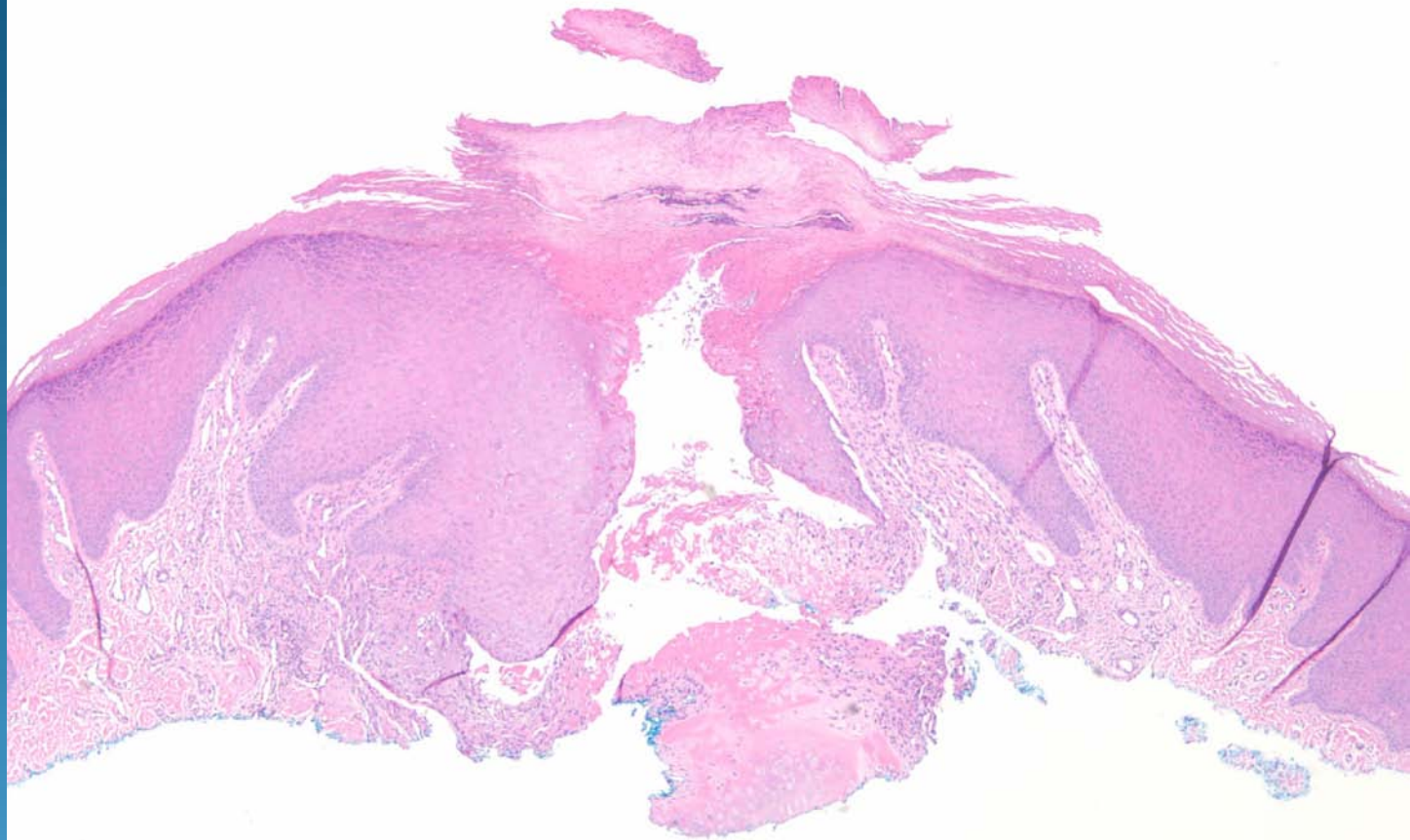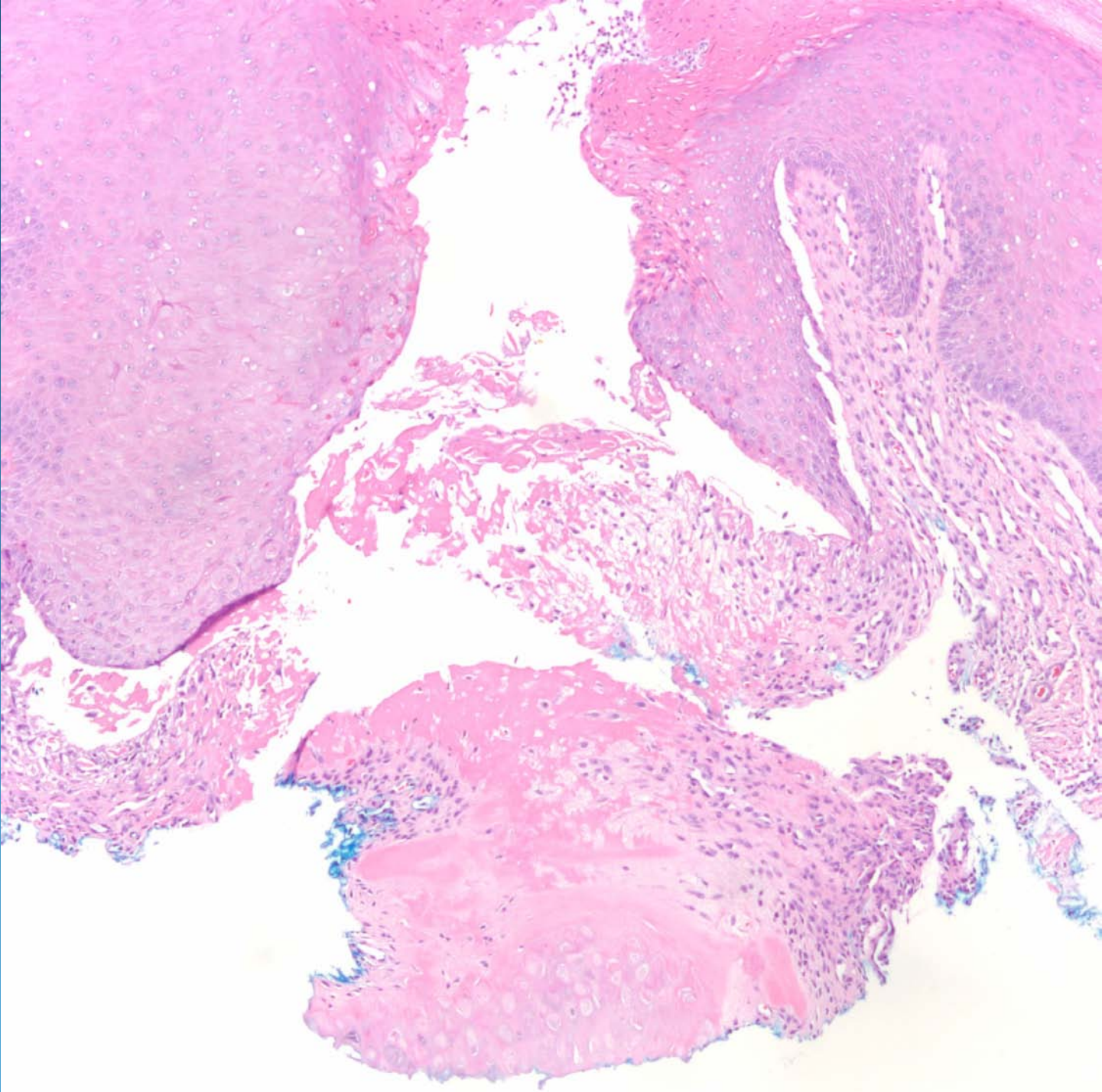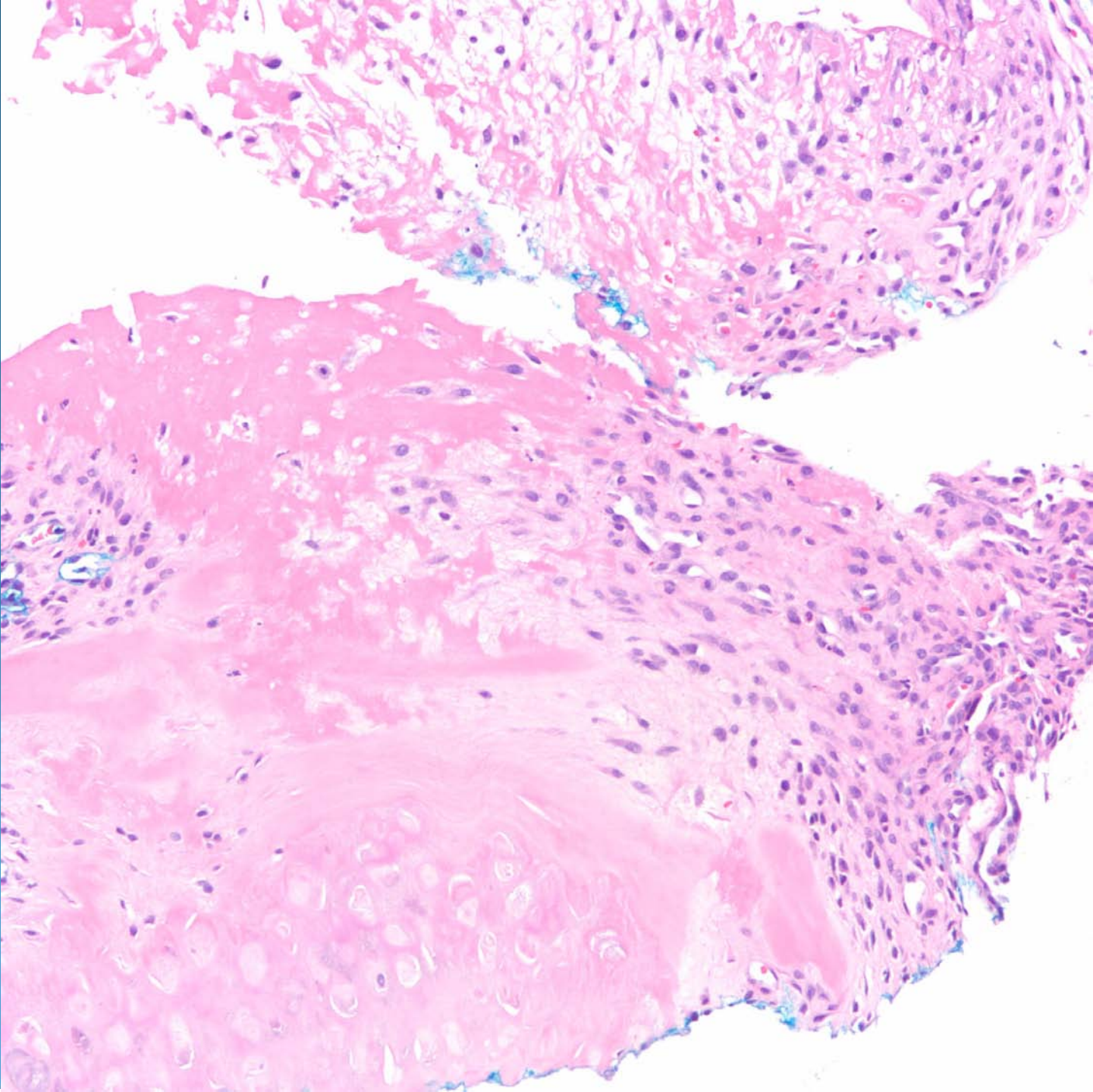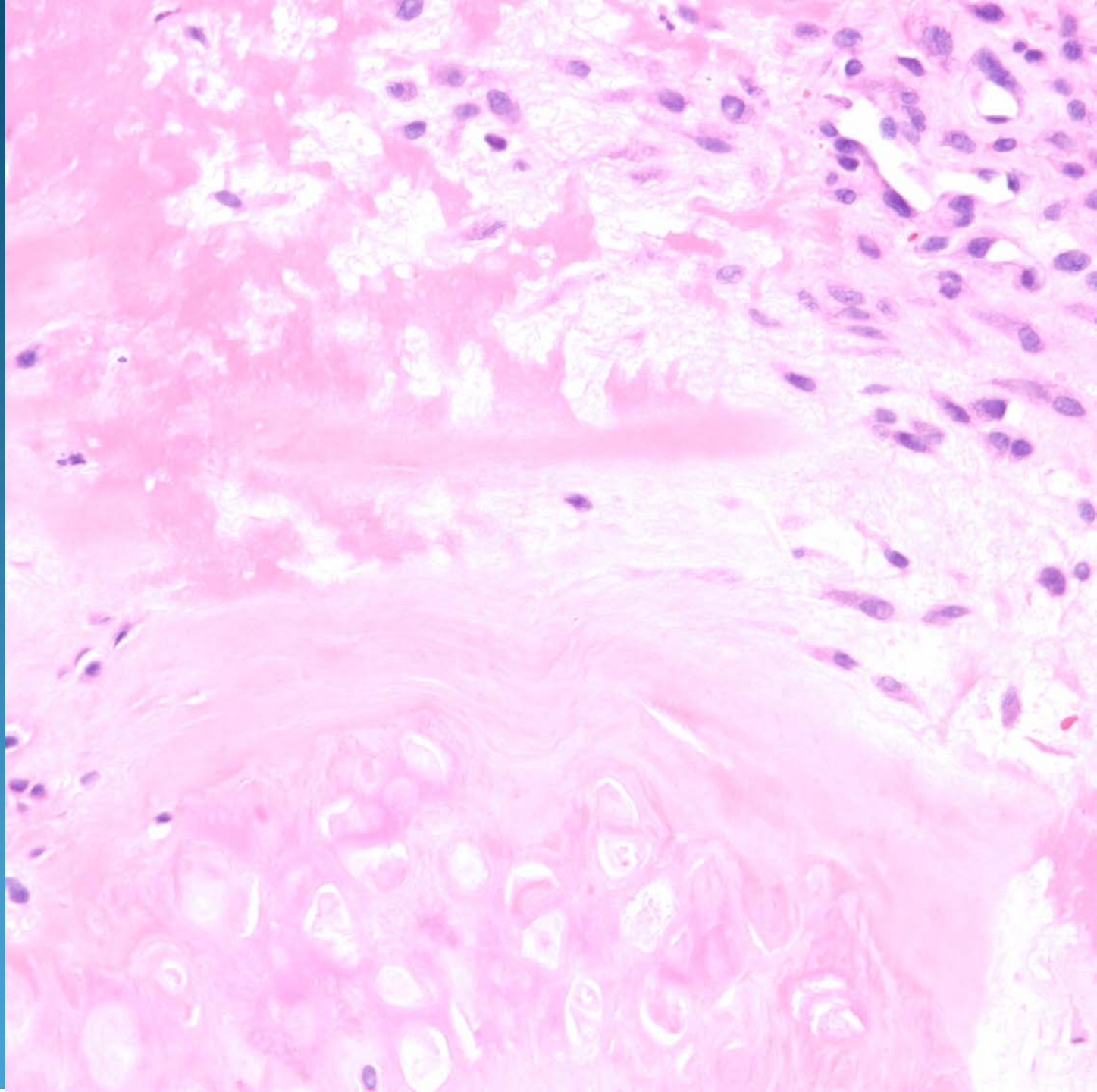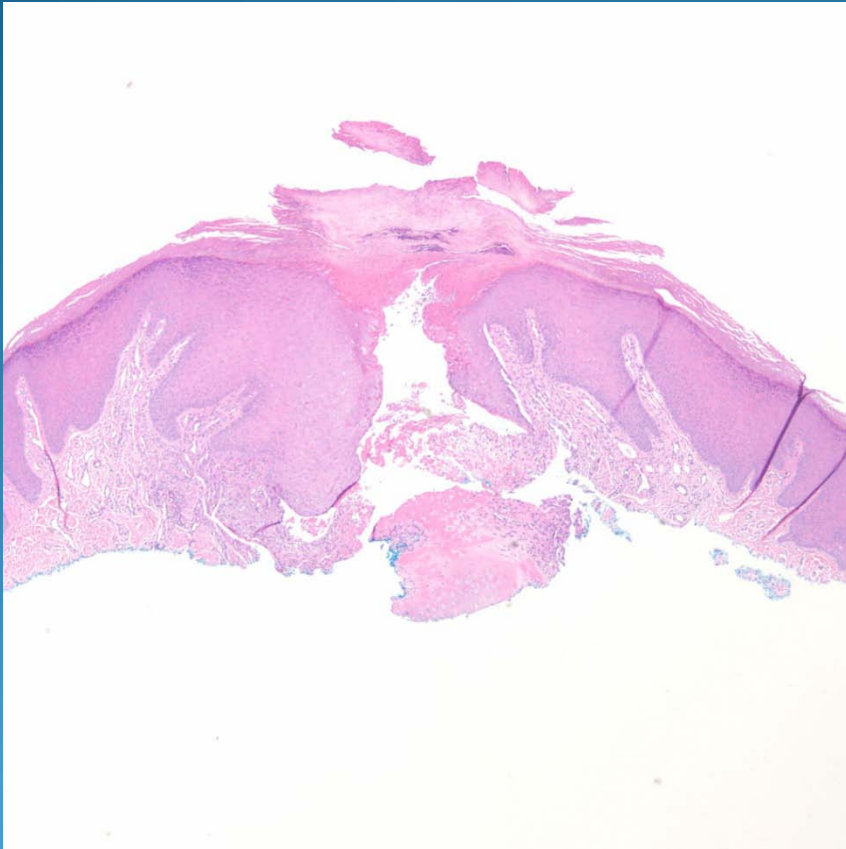


Chondrodermatitis Nodularis Helicis

Pearls



- Usually epidermal hyperplasia with scar
- Look for cartilage with eosinophilic degenerative changes
- May see proliferation of perichondrocytes within the dermis