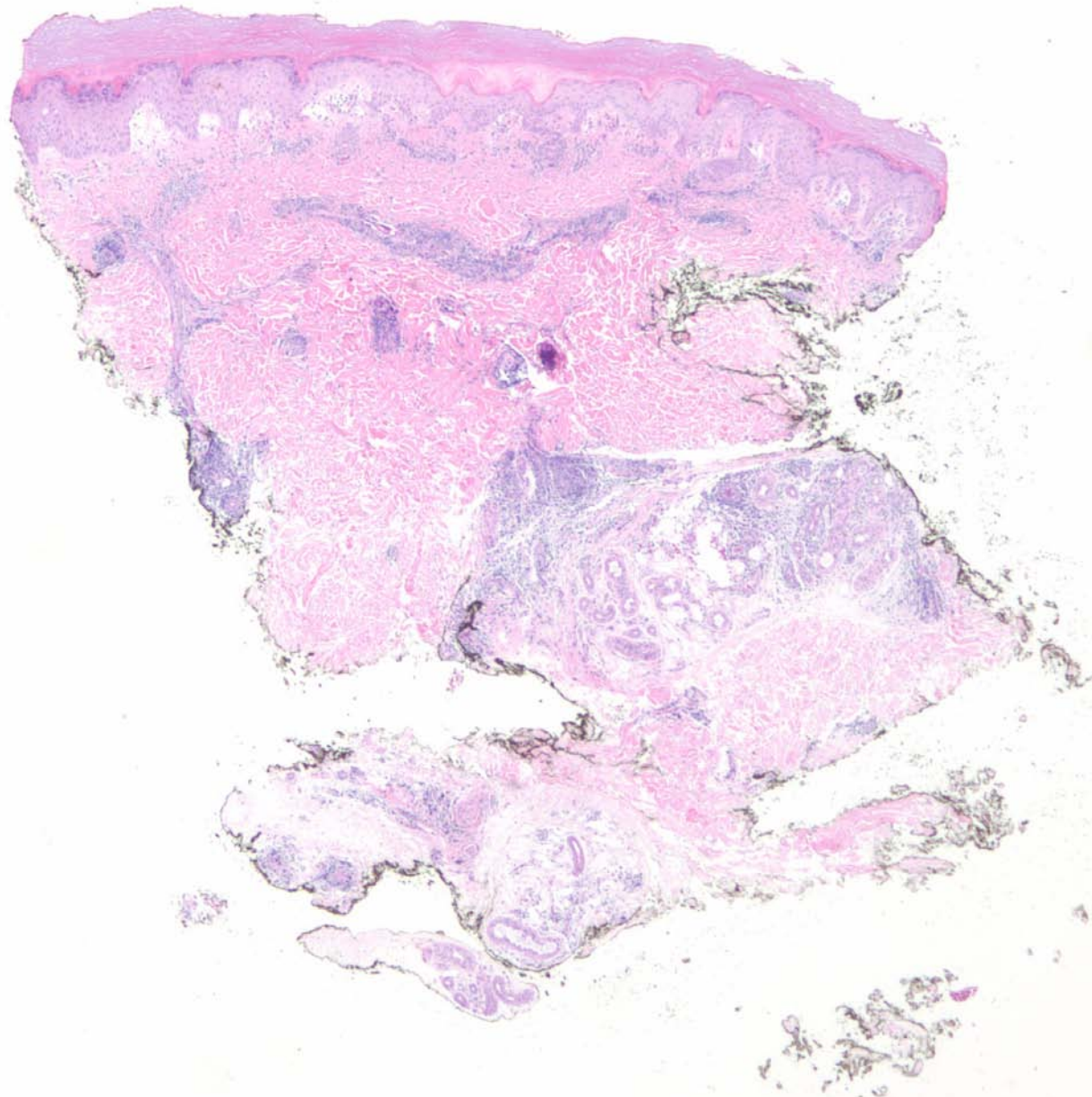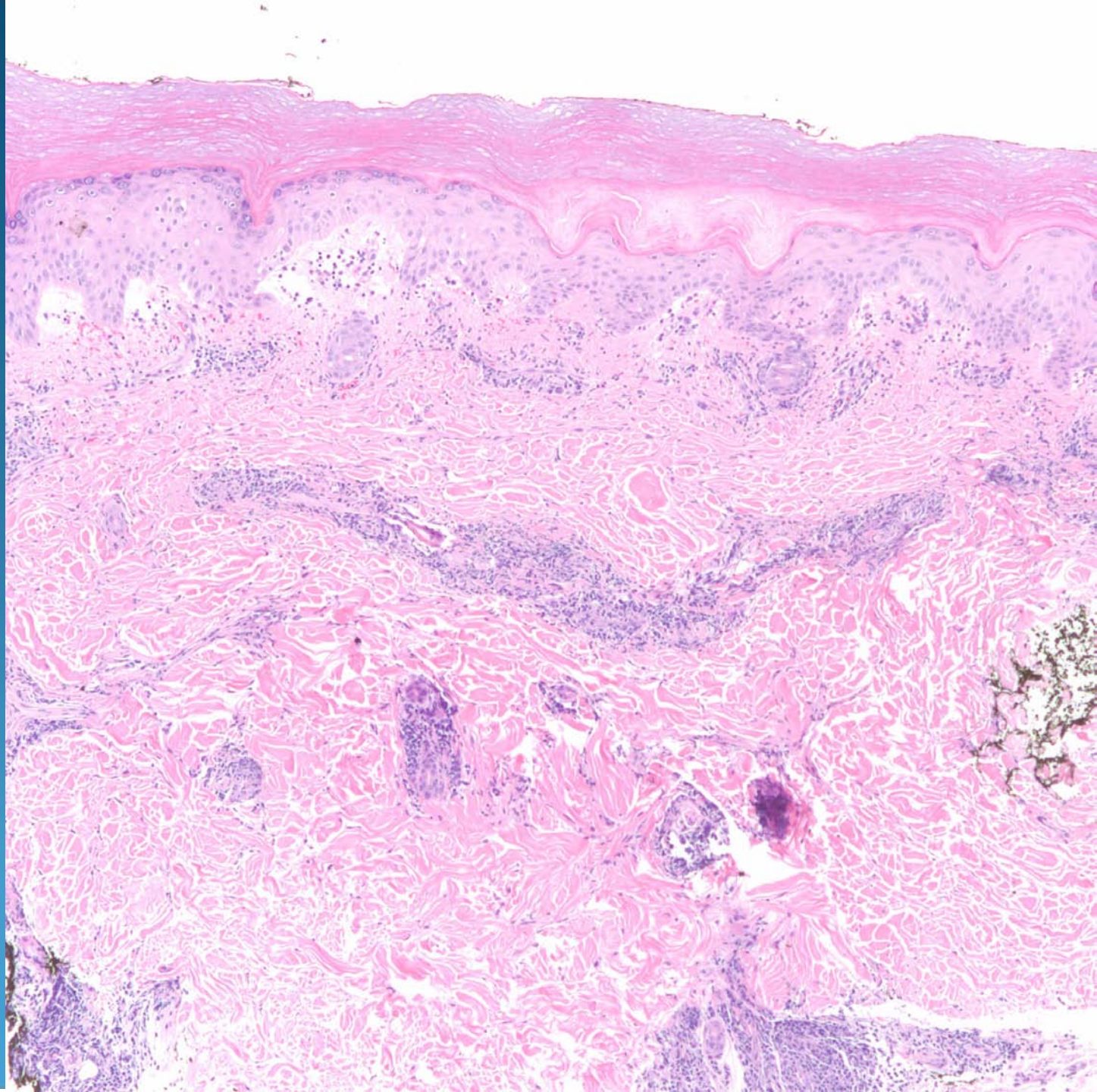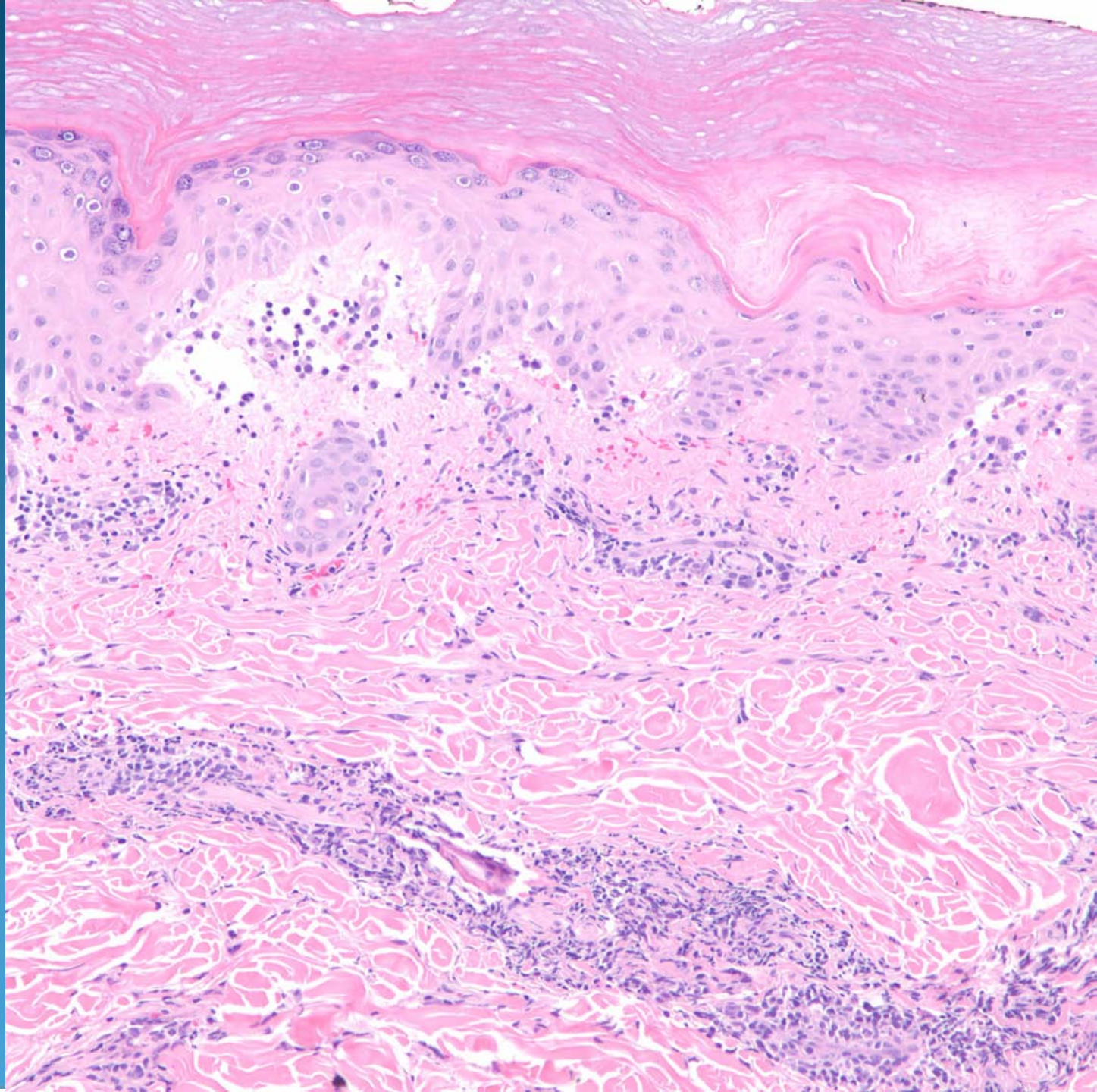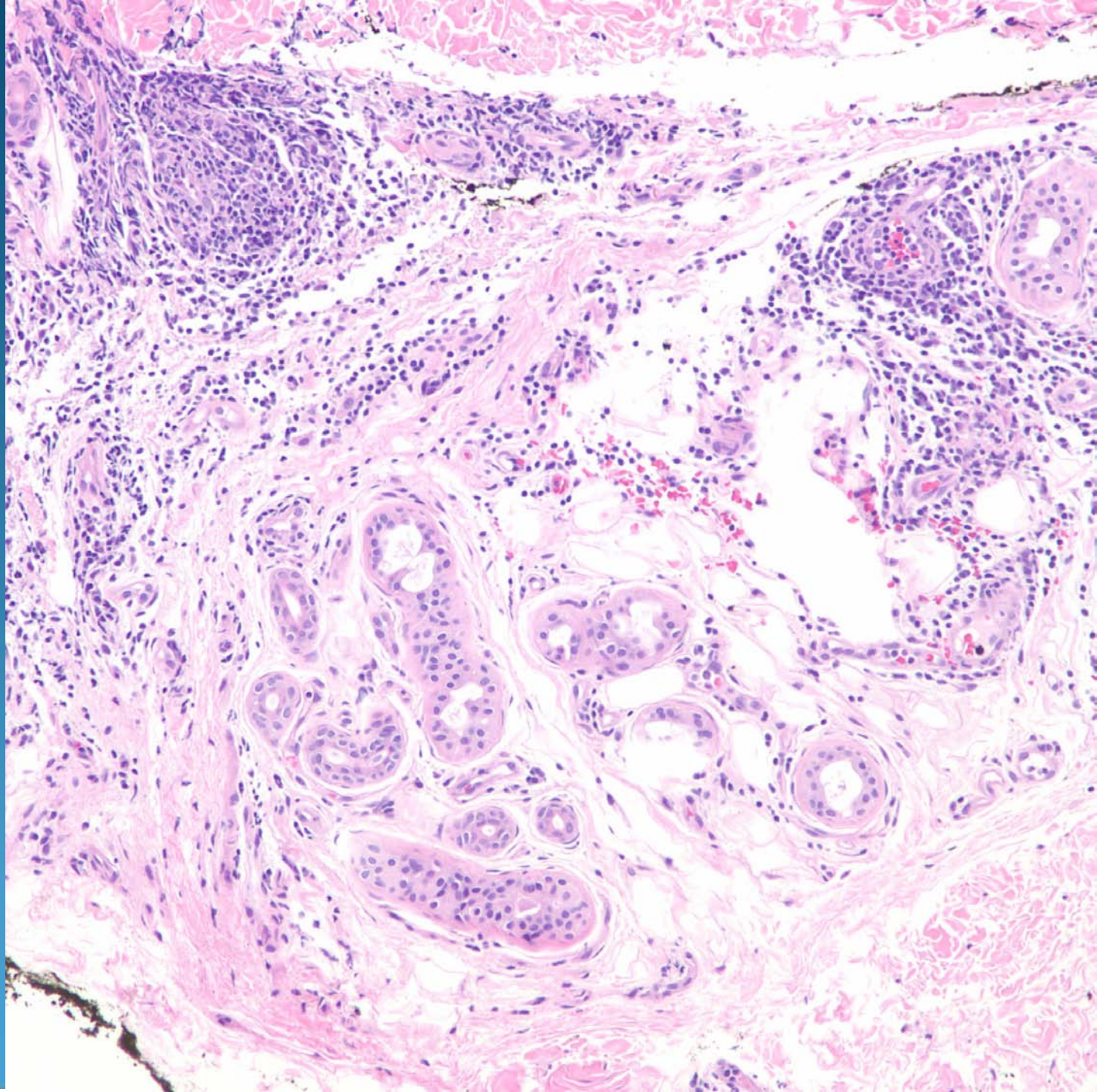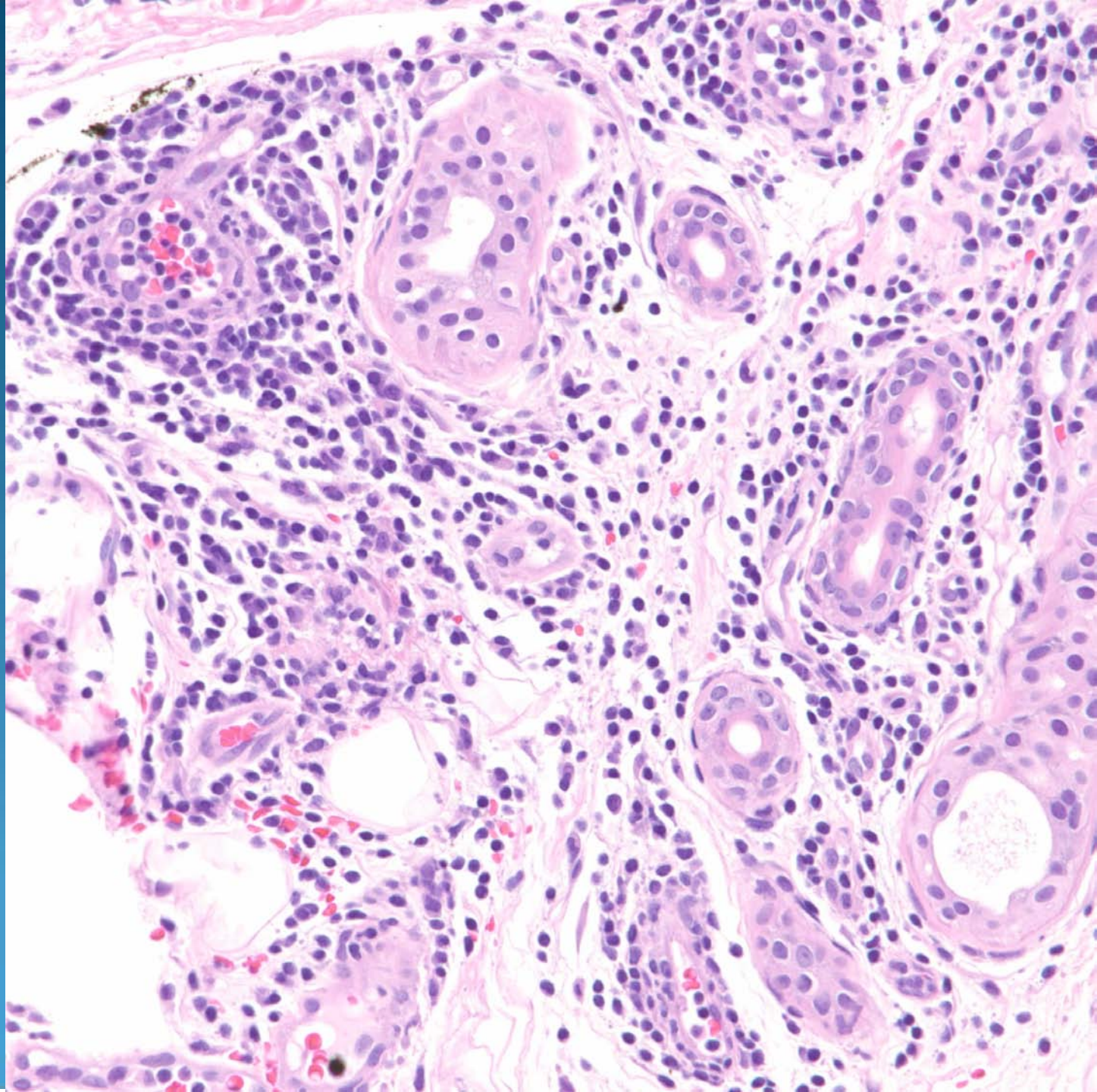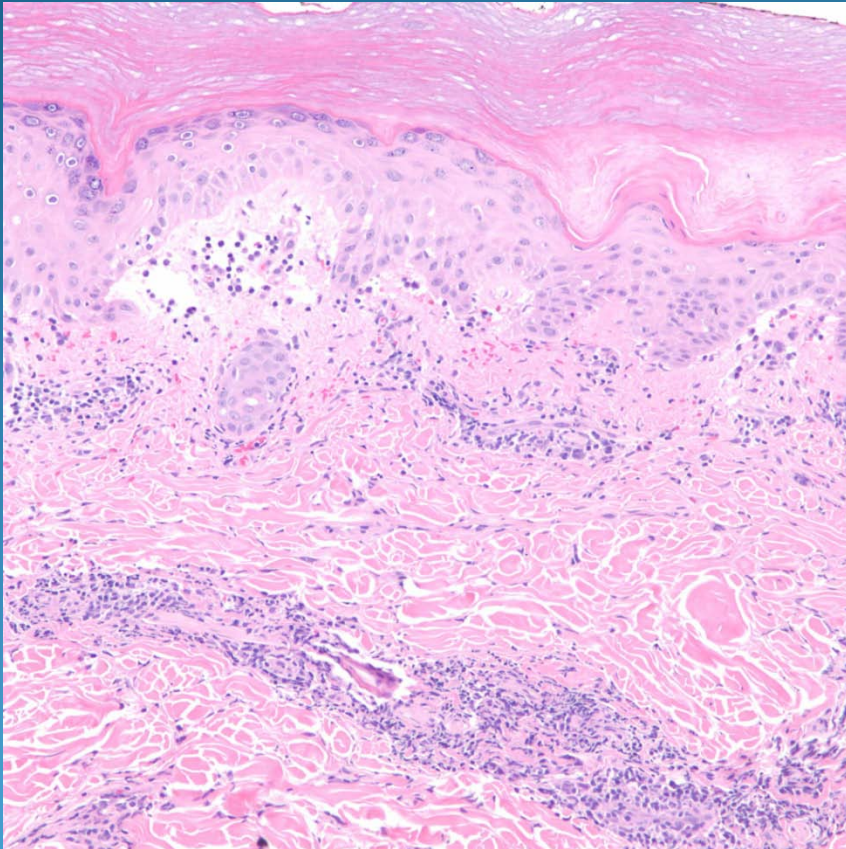


Chilblains (Perniosis)

Pearls



- Clinical-pathologic correlation
- Superficial and deep perivascular and periadnexal dermatitis with lymphocytic vasculitis
- May have dermal edema/dermal mucinosis
- May have focal interface changes
- DDX: Lupus erythematosus